

The use of digital periapical radiographs to study the prevalence of alveolar domes

Pedro Augusto Oliveira Santos Xambre¹, Claudia Scigliano Valerio¹, Claudia Assunção e Alves Cardoso¹, Antônio Luís Neto Custódio¹, Flávio Ricardo Manzi^{1,*}

¹Department of Oral Radiology, School of Dentistry, Pontifical Catholic University of Minas Gerais, Belo Horizonte, Brazil

ABSTRACT

Purpose: In the present study, we coined the term 'alveolar dome' and aimed to demonstrate the prevalence of alveolar domes through digital periapical radiographs.

Materials and Methods: This study examined 800 digital periapical radiographs in regard to the presence of alveolar domes. The periapical radiographs were acquired by a digital system using a photostimulable phosphor (PSP) plate. The χ^2 test, with a significance level of 5%, was used to compare the prevalence of alveolar domes in the maxillary posterior teeth and, considering the same teeth, to verify the difference in the prevalence of dome-shaped phenomena between the roots.

Results: The prevalence of alveolar domes present in the first pre-molars was statistically lower as compared to the other maxillary posterior teeth ($p < 0.05$). No statistically significant difference was observed in the prevalence of alveolar domes between the maxillary first and second molars. Considering the maxillary first and second molars, it was observed that the palatal root presented a lower prevalence of alveolar domes when compared to the distobuccal and mesiobuccal roots ($p < 0.05$).

Conclusion: The present study coined the term 'alveolar dome', referring to the anatomical projection of the root into the floor of the maxillary sinus. The maxillary first and second molars presented a greater prevalence of alveolar domes, especially in the buccal roots, followed by the third molars and second pre-molars. Although the periapical radiograph is a two-dimensional method, it can provide dentists with the auxiliary information necessary to identify alveolar domes, thus improving diagnosis, planning, and treatment. (*Imaging Sci Dent* 2016; 46: 179-84)

KEY WORDS: Maxillary Sinus; Tooth Root; Radiography, Dental, Digital; Prevalence

Introduction

Paranasal sinuses are air cavities that exist in some facial bones. These vary in shape and size, and drain to the nasal cavity either directly or indirectly.^{1,2} The maxillary sinuses are the largest of the paranasal sinuses, normally segmented by septa, and are located inside of the maxillary bones.^{3,4} These sinuses can present anatomical vari-

ations,⁵ extending to the anterior region of the maxilla, maxillary tuberosity, hard palate, zygomatic bone, orbit, and alveolar ridge. The extensions to the alveolar region occur in more than 80% of patients.³

In this sense, the root apices of maxillary posterior teeth may well present a close relationship with the sinus floor. The knowledge of this anatomical relationship is essential when diagnosing changes in the sinus caused by lesions of odontogenic origin or association, surgical planning, intrusion of the maxillary sinus root, fracture of the bone plate with oral sinus communication, recognition of the pathway of dental infections, and planning of orthodontic treatment.^{1,4,6} When there is a projection of the root into the maxillary sinus, the maxillary sinus floor deviates from its linear and horizontal path in order to bypass the

*This project was supported by the Foundation of Research Support for the State of Minas Gerais (Fundação de Amparo a Pesquisa do Estado de Minas Gerais - FAPEMIG), and CAPES Foundation.

Received March 5, 2016; Revised May 17, 2016; Accepted June 2, 2016

*Correspondence to : Dr. Flávio Ricardo Manzi

Department of Oral Radiology, School of Dentistry, Pontifical Catholic University of Minas Gerais. Av. Dom José Gaspar, 500-Prédio 45, CEP: 30535-901, Belo Horizonte, Minas Gerais, Brazil

Tel) 55-31-33194341, Fax) 55-31-33194414, E-mail) manzi@pucminas.br

dental root of the posterior teeth. This change is referred to as an 'alveolar dome' in this study.

Maxillary sinusitis is a disease that has a significant impact on a patient's health, which may include facial pain and pressure, reduction or loss of one's sense of smell, ear aches, pain in the maxilla region, as well as toothaches, fatigue, irritability, and nausea.^{7,8} As regards etiopathogeny, up to 30% of chronic unilateral maxillary sinusitis can be attributed to an odontogenic origin.⁹ Therefore, if the diagnosis of dental origin is not performed properly, this action can compromise treatment.¹⁰ The proximity of the dental roots to the maxillary sinus favors the dissemination of dental infections within the maxillary sinus, causing odontogenic sinusitis. Other complications, such as oroantral fistulae or root displacement after extraction, might occur due to a close relationship between dental roots and the maxillary sinus.¹¹ Thus, knowing and identifying the relationship between these dental roots and the maxillary sinus is of utmost importance in determining proper diagnosis, planning, and treatment.

All previous studies have shown the anatomical relationship between the dental roots and the maxillary sinus through cone-beam computed tomography (CBCT).^{1,3,11-13} However, CBCT is not the primary exam considered for diagnosis due its high costs and radiation doses. Health history, clinical examination, and dental radiographs are necessary for diagnosis in new patients or in recall patients being evaluated for oral diseases.^{14,15} In light of this, the present study aimed to define the term 'alveolar dome' and to evaluate the prevalence of alveolar domes in the maxillary pre-molar and molar regions using digital periapical radiographs.

Materials and Methods

This retrospective cross-sectional study was conducted after having received approval from the local Ethics Committee (CAE: 45194615.5.0000.5137). Eight hundred digital periapical radiographs from 200 dentate adult patients, who had all of their maxillary pre-molars and molars, were evaluated in regard to the presence of alveolar domes. Only the healthy maxillary sinus surrounding the teeth was considered.

All of the periapical radiographs were acquired by a digital system using the photostimulable phosphor (PSP) plate (Scan-X Duo, Air Techniques, New York, NY, USA). For the standard acquisition of images, a single operator took the radiographs, using the periapical technique of parallelism by means of Rinn XCP positioners (Dentsply,

York, PA, USA). This study used the Kodak 2200 intra-oral X-ray system (Kodak Dental Systems, Rochester, NY, USA), with an exposure factor of 60 kV, 7 mA, and an exposure time that varied according to manufacturer recommendations for each region (0.304 seconds for pre-molars and 0.356 seconds for molars).

In adults, the maxillary sinuses have a pyramidal shape, extending from the root of the canine to the maxillary tuberosity, and from the floor of the orbit to the apex region of the maxillary posterior teeth. On periapical radiography, the contour of the floor of a healthy maxillary sinus is seen as a slightly curved, thin, and radiopaque line (Fig. 1).¹⁶ When pneumatization of the maxillary sinus is present, two situations may occur. In the first, pneumatization occurs in the region near the tooth root, without actually coming in contact with it. As the radiographic image is two-dimensional, the image of the maxillary sinus floor projects itself over the roots of the posterior maxillary teeth; however, it should be noted that the contour of the maxillary sinus floor remains unaltered, that is, horizontal and slightly curved (Fig. 2). In the second, the pneumatization of the real maxillary sinus comes in contact with the dental roots. Thus, the maxillary sinus floor deviates from its linear and horizontal path in order to bypass the dental root of the posterior teeth, in turn taking on a sinuous contour in the shape of a bell, with a format that is similar to the contour of the root apex, a phenomenon that we in this article term an 'alveolar dome' (Fig. 3). In this scenario, on the periapical radiograph, one can observe that the radiopaque line of the contour of the maxillary sinus floor merges with the radiopaque line of the lamina dura that bypasses the dental apex, as if both were a single sinuous and radiopaque line in close contact with the root apex.

All of the images were evaluated by 2 dentists, specialists in dental radiology and diagnostic imaging, after having been duly trained and calibrated. The interpretation of the digital images was performed directly with Kodak Dental Imaging software (Kodak Dental Systems, Rochester, NY, USA), allowing the use of all available resources. This study used a computer that contained a GeForce 9500 GT graphics card (Nvidia Corporation, Santa Clara, CA, USA) and an LED LG Flatron E2241 monitor (LG Electronics, Greater Noida, Uttar Pradesh, India) with a resolution of 1920 × 1080 pixels, together with brightness and contrast levels of the monitor set to their pre-defined configurations.

BioEstat 5.0 software (Instituto de Desenvolvimento Sustentável Mamirauá, Belém, Pará, Brazil) was used to com-

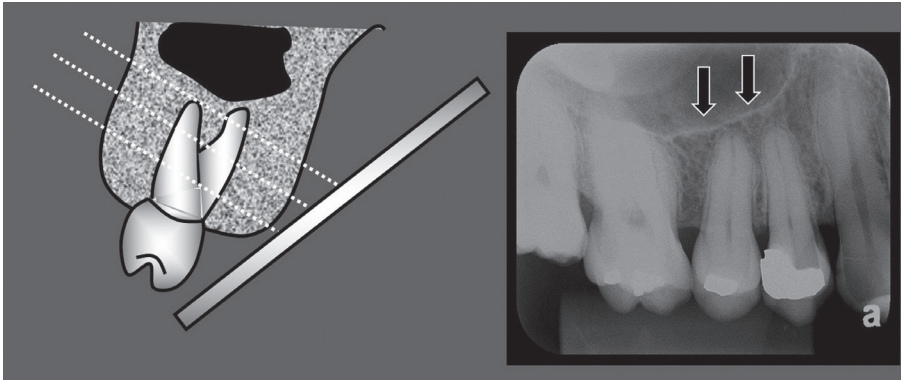


Fig. 1. Maxillary sinus without pneumatization. The periapical radiograph shows the slightly curved, thin, delicate, and tenuous radiopaque line of the contour of the maxillary sinus floor (arrows).

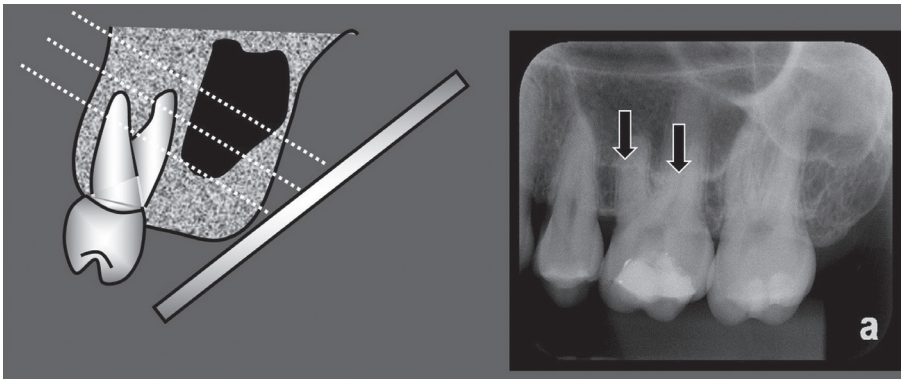


Fig. 2. Maxillary sinus with pneumatization near the root of the maxillary molar. The contour of the maxillary sinus floor is projected over the roots of the maxillary molar; however, its format remains horizontal and slightly curved (arrows).

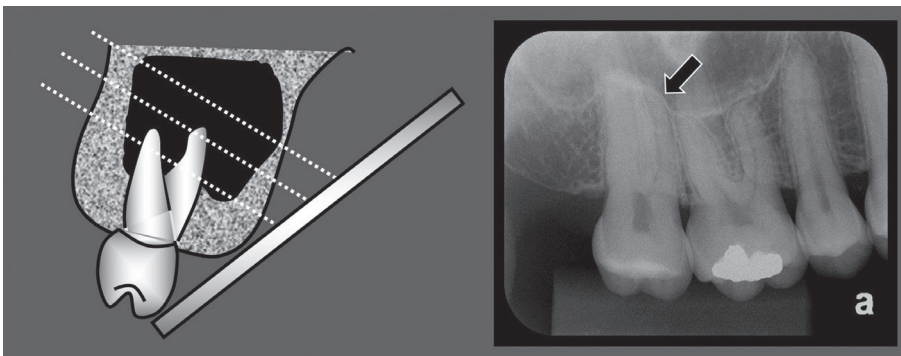


Fig. 3. Maxillary sinus with pneumatization involving the root of the maxillary molar. The radiopaque line of the contour of the maxillary sinus floor appears in the form of a bell, forming an alveolar dome (arrows).

pare the prevalence of alveolar domes among the maxillary teeth and, considering the molars, to compare the prevalence of alveolar domes among the different roots of the same tooth. The χ^2 test was applied with a significance level of 5%.

Results

The prevalence of alveolar domes was evaluated in 400 first pre-molars, 400 second pre-molars, 400 first molars, 400 second molars, and 128 third molars. The results demonstrated that the prevalence of alveolar domes

identified in the first pre-molars was 7.75% (31/400), which is statistically significantly lower when compared to the other maxillary posterior teeth (19.25% for second pre-molar [77/400], 30.5% for first molar [122/400], 32% for second molar [128/400]), and 22.66% for third molars (29/128) ($p < 0.05$) (Table 1). There was also no statistically significant difference in the prevalence of alveolar domes between the first and second maxillary molars, and between the second pre-molar and third molars. However, for the second pre-molars and third molars, the prevalence of alveolar domes was statistically lower when compared to the first and second molars and statistically

Table 1. Prevalence and percentage of alveolar domes in the evaluated teeth.

	First premolar	Second premolar	First molar	Second molar	Third molar
Prevalence	31 ^C	77 ^B	122 ^A	128 ^A	29 ^B
%	7.75	19.25	30.5	32	22.66
Total	400	400	400	400	128

Frequency followed by different letters differ significantly between them (chi-square test; $p < 0.05$)

Table 2. Prevalence and percentage of alveolar domes in the mesiobuccal, distobuccal, and palatal roots of the maxillary first molars.

Roots	Mesiobuccal	Distobuccal	Palatal
Prevalence	119 ^A	113 ^A	45 ^B
%	29.75	28.25	11.25
Total	400	400	400

Frequency followed by different letters differ significantly between them (chi-square test; $p < 0.05$)

Table 3. Percentage of the appearance of alveolar domes in the mesiobuccal, distobuccal, and palatal roots of the maxillary second molars.

Roots	Mesiobuccal	Distobuccal	Palatal
Frequency	121 ^A	116 ^A	54 ^B
%	30.25	29	13.5
Total	400	400	400

Frequency followed by different letters differ significantly between them (chi-square test; $p < 0.05$)

higher when compared to the first pre-molars ($p < 0.05$).

In the evaluation of the presence of alveolar domes among the roots of the first molars, it was observed that the palatal (P) root presented a lower prevalence of alveolar domes (11.25%, 45/400) when compared to the distobuccal (DB) (28.25%, 113/400) and the mesiobuccal (MB) (29.75%, 119/400) roots ($p < 0.05$). The buccal roots presented no statistically significant differences among them (Table 2).

The same characteristics found for the roots of the first molars were also identified for the maxillary second molars. In other words, no statistically significant difference was observed in the prevalence of alveolar domes among the buccal roots (30.25% for MB root [121/400], and 29% for DB root [116/400]), which present a higher prevalence of alveolar domes when compared to the 13.5% for the P root (54/400) ($p < 0.05$) (Table 3).

Discussion

In this study, the prevalence of alveolar domes in maxillary sinus was examined using periapical radiographs.

Due to the anatomical proximity between the maxillary sinus and the root apices of the posterior teeth, various cases of maxillary sinusitis are of odontogenic origin or association with periapical and periodontal lesions, as well as tooth extractions.^{9,17} In addition, the endodontic treatment of pre-molars and molars can result in accidents, such as oral sinus communication, allowing for the displacement of infected tissues to the inner portion of the maxillary sinus, which can cause acute or chronic forms of sinusopathy.¹⁸

The distance between the maxillary sinus and the roots of maxillary posterior teeth were analyzed by Kilic et al.³ through 92 computed tomography (CT) images. These authors maintained that the roots of the first pre-molars had less contact with the maxillary sinus, whereas the buccal roots of the second molars had more contact but presented no statistically significant difference between them. These results are quite similar to those from the present study, which observed that the first pre-molars present a lower prevalence of alveolar domes, while the buccal roots, as compared to the palatal root, of the maxillary first and second molars present a greater prevalence of alveolar domes. This affirmation can be explained by the anatomy of the maxillary sinus, which shows a tendency towards a reduction in volume in the medial and posterior directions.¹⁹

One study performed by Pagin et al.,² conducted using CT images, verified that the root apices protruded into the maxillary sinus in 21.1% of the first pre-molars, 22.2% of the second pre-molars, 20.3% of the first molars, 25% of the second molars, and 11.1% of the third molars. In the present study, it was observed that the root apices protruded into the maxillary sinus in 7.75% of the first pre-molars, 19.25% of the second pre-molars, 30% of the first molars, 32% of the second molars, and 22.66% of the third molars. Upon comparing the two studies, a greater difference was found in the prevalence of the alveolar domes of the first pre-molars and third molars; however, this difference may well be related to the different types of exams used in each study.

As regards the roots of the maxillary first and second molars, many studies have demonstrated that the MB roots of these molars were most frequently associated with alveolar domes when compared to the DB and P roots, and that the P roots contained the lowest prevalence

of alveolar domes.^{12,13,20} The present study also observed a lower prevalence of alveolar domes in the P roots, when compared to the buccal roots ($p < 0.05$). However, no statistically significant difference was observed between the MB and DB roots ($p > 0.05$). This divergence can be explained by the sensitivity of the diagnostic method, given that the present study was conducted with digital periapical radiographs, while the other studies were conducted using CT exams. The same was not true for the first pre-molar and the P root of the first and second molars, as they presented results that were similar to prior studies, that is, a lower prevalence of alveolar domes.^{8,13,20}

No previous study using periapical radiographs has evaluated the anatomical relationship between the apices of the maxillary posterior teeth and the maxillary sinus floor. In this study, the results of the prevalence of alveolar domes, using two-dimensional periapical radiographs as an evaluation method, were similar to those found in works that used three-dimensional CT exams.^{6,8,13,19-22} However, periapical radiographs have the advantage of being an imaging method that is more commonly used by dentists, due to their cost, accessibility, and lower radiation dose.²¹ Once the periapical radiograph has identified an alveolar dome, the decision to recommend a CT exam should be based on the patient's history and clinical examination.²³

In conclusion, the present study coined the term 'alveolar dome,' referring to the anatomical projection of the root into the floor of the maxillary sinus. In regard to prevalence, this study showed that the first and second molars presented a greater prevalence of alveolar domes, especially in the buccal roots, followed by the third molars and second pre-molars. The first pre-molars presented a lower prevalence of alveolar domes. Although the periapical radiograph is a two-dimensional method, the results of this study showed that periapical radiographs can provide dentists with the auxiliary information necessary to identify alveolar domes, improving diagnosis, planning, and treatment.

References

1. Hauman CH, Chandler NP, Tong DC. Endodontic implications of the maxillary sinus: a review. *Int Endod J* 2002; 35: 127-41.
2. Pagin O, Centurion BS, Rubira-Bullen IR, Alvares Capelozza AL. Maxillary sinus and posterior teeth: accessing close relationship by cone-beam computed tomographic scanning in a Brazilian population. *J Endod* 2013; 39: 748-51.
3. Kilic C, Kamburoglu K, Yuksel SP, Ozen T. An assessment

- of the relationship between the maxillary sinus floor and the maxillary posterior teeth root tips using dental cone-beam computerized tomography. *Eur J Dent* 2010; 4: 462-7.
4. de Oliveira AG, dos Santos Silveira O, Francio LA, de Andrade Marigo Grandinetti H, Manzi FR. Anatomic variations of paranasal sinuses - clinical case report. *Surg Radiol Anat* 2013; 35: 535-8.
5. Lana JP, Carneiro PM, Machado Vde C, de Souza PE, Manzi FR, Horta MC. Anatomic variations and lesions of the maxillary sinus detected in cone beam computed tomography for dental implants. *Clin Oral Implants Res* 2012; 23: 1398-403.
6. Sharan A, Madjar D. Correlation between maxillary sinus floor topography and related root position of posterior teeth using panoramic and cross-sectional computed tomography imaging. *Oral Surg Oral Med Oral Pathol Oral Radiol Endod* 2006; 102: 375-81.
7. Kretzschmar DP, Kretzschmar JL. Rhinosinusitis: review from a dental perspective. *Oral Surg Oral Med Oral Pathol Oral Radiol Endod* 2003; 96: 128-35.
8. Tan R, Spector S. Pediatric sinusitis. *Curr Allergy Asthma Rep* 2007; 7: 421-6.
9. Patel NA, Ferguson BJ. Odontogenic sinusitis: an ancient but under-appreciated cause of maxillary sinusitis. *Curr Opin Otolaryngol Head Neck Surg* 2012; 20: 24-8.
10. Pokorny A, Tataryn R. Clinical and radiologic findings in a case series of maxillary sinusitis of dental origin. *Int Forum Allergy Rhinol* 2013; 3: 973-9.
11. Didilescu A, Rusu M, Săndulescu M, Georgescu C, Ciuluvică R. Morphometric analysis of the relationships between the maxillary first molar and maxillary sinus floor. *Open J Stomatol* 2012; 2: 352-7.
12. Eberhardt JA, Torabinejad M, Christiansen EL. A computed tomographic study of the distances between the maxillary sinus floor and the apices of the maxillary posterior teeth. *Oral Surg Oral Med Oral Pathol* 1992; 73: 345-6.
13. Kwak HH, Park HD, Yoon HR, Kang MK, Koh KS, Kim HJ. Topographic anatomy of the inferior wall of the maxillary sinus in Koreans. *Int J Oral Maxillofac Surg* 2004; 33: 382-8.
14. American Dental Association, U.S. Department of Health and Human Services. Dental radiographic examinations: recommendations for patient selection and limiting radiation exposure. Revised: 2012 [Internet]. Chicago: American Dental Association; 2012 [cited 2016 Mar 1]. Available from: http://www.ada.org/~media/ADA/Member_Center/Files/Dental_Radiographic_Examinations_2012.ashx
15. Low KM, Dula K, Bürgin W, von Arx T. Comparison of periapical radiography and limited cone-beam tomography in posterior maxillary teeth referred for apical surgery. *J Endod* 2008; 34: 557-62.
16. White SC, Pharoah MJ. *Oral radiology; principles and interpretation*. 6th ed. St. Louis: Mosby-Year Book Inc; 2009.
17. Shanbhag S, Karnik P, Shirke P, Shanbhag V. Association between periapical lesions and maxillary sinus mucosal thickening: a retrospective cone-beam computed tomographic study. *J Endod* 2013; 39: 853-7.
18. Lu Y, Liu Z, Zhang L, Zhou X, Zheng Q, Duan X, et al. Associations between maxillary sinus mucosal thickening and apical periodontitis using cone-beam computed tomography

- scanning: a retrospective study. *J Endod* 2012; 38: 1069-74.
19. Mossa-Basha M, Blitz AM. Imaging of the paranasal sinuses. *Semin Roentgenol* 2013; 48: 14-34.
20. Lane JJ, O'Neal RB. The relationship between periodontitis and the maxillary sinus. *J Periodontol* 1984; 55: 477-81.
21. Butaric LN, McCarthy RC, Broadfield DC. A preliminary 3D computed tomography study of the human maxillary sinus and nasal cavity. *Am J Phys Anthropol* 2010; 143: 426-36.
22. Jung YH, Cho BH. Assessment of the relationship between the maxillary molars and adjacent structures using cone beam computed tomography. *Imaging Sci Dent* 2012; 42: 219-24.
23. Special Committee to Revise the Joint AAE/AAOMR Position Statement on use of CBCT in Endodontics. AAE and AAOMR joint position statement: use of cone beam computed tomography in endodontics 2015 update. *Oral Surg Oral Med Oral Pathol Oral Radiol* 2015; 120: 508-12.