

## A 3D-printing Bone Model for Surgical Planning of Total Hip Replacement after Failed Triple Pelvic Osteotomy

Kyungjin Han<sup>†</sup>, Jiyoung Park<sup>†</sup>, Jangwon Yoon, Young-Won Lee, Ho-Jung Choi,  
SeongMok Jeong and Haebeom Lee<sup>1</sup>

*College of Veterinary Medicine, Chungnam National University, Daejeon 34134, Korea*

(Received: August 23, 2017 / Accepted: September 30, 2017)

**Abstract :** A 3-year-old, 26 kg, castrated male Chow Chow was presented for assessment of weight-bearing lameness of the left hind limb. The patient had a history of triple pelvic osteotomy on the left side to correct hip dysplasia 2 years prior to his presentation of clinical signs and underwent total hip replacement on the right coxofemoral joint 1 year later. Upon physical examination, pain and crepitus were noted on the left hip joint during extension. Radiological examination revealed coxofemoral joint subluxation and moderate degenerative bone changes on the left hip joint and pelvic axis, which relates to acetabular angles that were changed after triple pelvic osteotomy (TPO). Preoperative computed tomography was used for 3-dimensional printing to establish an accurate surgical plan. The changed angles of the acetabulum after TPO were evaluated, and rehearsal surgery was performed using a 3-dimensional printing bone model. Three months after the THR surgery, the function of the affected limb had improved, with no lameness. Complications, such as luxation and implant failure, were not observed until 6 months after the operation. Accurate evaluation of acetabulum angles and rehearsal surgery using a 3D-printed bone model is effective for total hip replacement after unsuccessful TPO.

**Key words :** triple pelvic osteotomy, total hip replacement, 3D-printed bone model.

### Introduction

Canine hip dysplasia (CHD) is one of the most common orthopedic diseases in medium to large breed dogs. It causes subluxation and degenerative changes in the joints of dogs (8,12,13). Discomfort may develop due to joint laxity, exposed subchondral bone and stretching of soft tissue. When CHD progresses to degenerative changes, the development of osteoarthritis (OA) results in pain (2,11).

To alleviate pain and prevent joint degeneration, a TPO can be performed in young dogs without OA (i.e., skeletally immature dogs approximately 6 to 12 months of age). TPO surgery rotates the acetabulum ventrolaterally to increase dorsal coverage of the femoral head. The loadbearing area of the acetabulum increases, and cartilage injury is decreased by dispersing mechanical stress onto the articular cartilage. Therefore, TPO limits hip subluxation and prevents OA (8,11).

However, when a CHD patient still has pain and progressive degenerative changes after preventative surgery, a salvage procedure should be considered as a treatment option. In a patient with degenerative changes and OA at the hip joint, femoral head and neck osteotomy (FHNO) and total hip replacement (THR) are generally considered to be a salvage procedure. THR has the best clinical outcomes, regardless of

weight, by replacing the diseased acetabulum and femoral head with a prosthetic implant to relieve pain and return the patient to normal function (1,2,12).

Conversion to THR from failed TPO is a difficult surgical technique because of the morphological changes in the pelvis. If a prosthetic THR cup is positioned as a changed anatomic pelvic axis, then complications, such as ventral luxation and impingement, may occur after THR. Therefore, meticulous evaluations and technical considerations are needed preoperatively to adjust the cup positioning angle (5,9,10). Preoperative computed tomography was used for 3-dimensional printing to establish an accurate surgical plan, and rehearsal surgery was performed using a 3d-printed bone model.

This case report evaluates the changed acetabular angle after failed TPO and describes a successful clinical outcome of THR using a 3-d printed bone model.

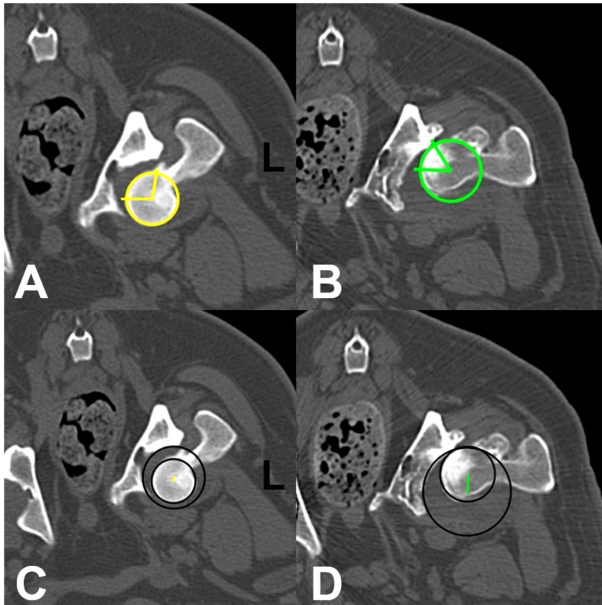
### Case

A 3-year-old, 26 kg, castrated male Chow Chow was presented for assessment of weight-bearing lameness of the left hind limb. The patient had undergone TPO on the left side to correct hip dysplasia 2 years ago. After 1 year, Zurich cementless total hip replacement (ZCTHR) surgery was performed on the contralateral hip. To prepare for THR surgery on the right hip, a patient positioner (Kyon Inc., Zurich, Switzerland) for the operating table was used to make the patient's spine horizontal and place the ilium bodies perpendicular to the table. With the patient in the positioner, the left

<sup>†</sup>These authors contribute equally to this work

<sup>1</sup>Corresponding author.

E-mail : [seatiger76@cnu.ac.kr](mailto:seatiger76@cnu.ac.kr)



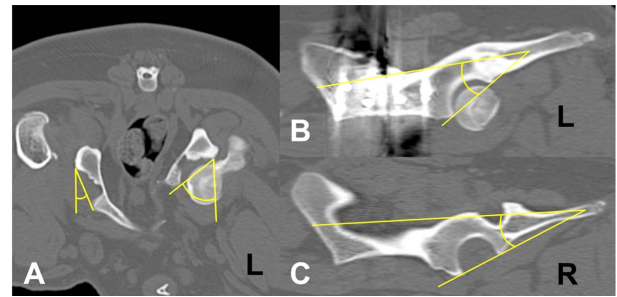
**Fig 1.** The lateral center edge angle (LCEA) and center distance (CD) has been used as a parameter for hip joint congruity. LCEA is the angle between the connecting line of the dorsal edge of the acetabulum and the center of the femoral head, and appears as a horizontal line on the CT image. CD is the distance between the center of the femoral head and the acetabular center on this CT image. (A) Six months after left hip TPO, the LCEA of the acetabulum was 99.2°. (B) One year after right hip THR, the LCEA of acetabulum was 55.1°. (C) Six months after left hip TPO, the CD of the acetabulum was 1.22 mm. (D) One year after right hip THR, the CD of the acetabulum was 6.56 mm.

hindlimb was hyperflexed, and dorsal pressure was applied at the mid tibia. When excessive pressure was applied on the left hip to correct the patient’s position, luxation occurred at the left hip.

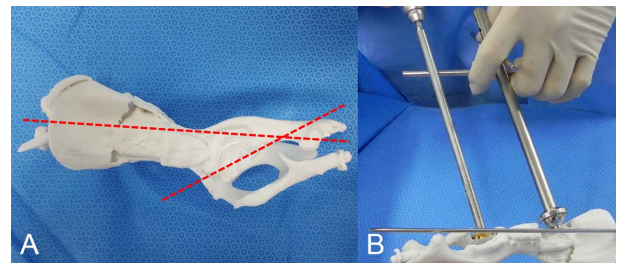
Closed reduction of the luxated hip was performed and the hindlimb was maintained in hobbles, with strict exercise restrictions for 2 weeks. After 1 year from discharge, the patient revisited the animal hospital with clinical signs.

During the physical examination, pain and crepitus were noted on the left hip joint during extension, and medial patellar luxation was identified on the same side. Radiological examination revealed coxofemoral joint subluxation and moderate degenerative bone changes on the left hip joint. Based on comprehensive information, THR was planned for revision of the left hip.

A CT scan was performed with 120 kVp, 500 mA, and 2 mm slice thickness with the patient under general anesthesia. CT was performed twice: 6 months after the left hip TPO and 1 year after the right hip THR. At each point, the lateral center edge angle (LCEA) and center distance (CD), which has been used as a parameter of hip joint congruity in previous articles (3,4,6), was measured from the left hip (Fig 1). The acetabular angle (AA) and inclination angle of the pelvis were also measured to adjust the positioning angle of the THR cup (Fig 2). CT data were reconstructed to print a 3D bone model. With the 3D bone model, the acetabular wall thickness and positioning angle of cup were confirmed.



**Fig 2.** The acetabular angle (AA) and inclination angle of the acetabulum. Based on the AA, the decreasing angle of the lateral opening (ALO) for the total hip replacement cup was determined. (A) The AA of the left acetabulum was 50.4°. (B) The AA of the right acetabulum was 21.2°. (C) The inclination angle of the left acetabulum was 29.3°. (D) The inclination angle of the right acetabulum was 21.2°.

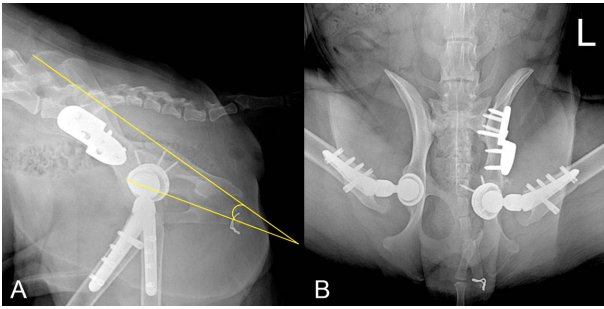


**Fig 3.** 3D-printed bone model was used for the rehearsal surgery. (A) The red dotted line shows the altered inclination angle of the left acetabulum after the TPO surgery. (B) The sagittal bar was adjusted to decrease the inclination angle, not based on the caudally lifted pelvic axis.

Rehearsal surgery was performed, and a preoperative plan was determined (Fig 3).

Prior to surgery, the patient was premedicated with cefazolin (22 mg/kg IV, cefazolin®; Jong-keundang, Korea) and midazolam (0.2 mg/kg IV, Midazolam®; Bukwang, Korea). Anesthesia was induced using propofol (6 mg/kg IV, Proville®; Myungmoon, Korea) and maintained with isoflurane (Ifran®; Hana Pharm, Korea), with oxygen, in a semi-closed circuit system. An epidural local block was performed with bupivacaine (bupivacaine HCL 0.5%®; Myungmoon, Korea). Remifentanyl HCl (0.1~0.6 µg/kg IV CRI, Ultiva®; Glakso, Korea) was infused as a perioperative analgesia.

The patient was placed in lateral recumbency, with a positioning bag on the surgical table and was prepared for aseptic surgery. The Zurich cementless total hip replacement (ZCTHR) procedure was performed, with Kyon implants (Kyon Inc., Zurich, Switzerland). After using the cranio-lateral approach, the femoral head was removed with an oscillating saw, and the femoral canal was prepared using drill bits and files. While the acetabular bed was reaming, excessive bone loss occurred. Therefore, a 26.5 mm revision cup was selected instead of the usual double shell cup, due to an expected inadequate press-fit. Before the cup fixation, multiple holes were drilled for osteostixis on the acetabular fossa and then packed with a cancellous bone graft. The cup was



**Fig 4.** A postoperative radiograph showing the left lateral view (A) and ventrodorsal view (B) of the left hip. The angle of inclination was 14.9°, and the lateral opening angle was 50°. The ALO was confirmed through fluoroscopy during surgery.

stabilized with four cortical screws. A small stem and a 16-mm head with a short neck prosthetic implant were inserted at each position. A fentanyl patch was used for postoperative analgesia.

Postoperative radiography showed that the angle of the lateral opening was 50°, and the inclination angle was 14.9° (Fig 4). Cage rest was prescribed for 2 weeks, and activity was controlled for next 4 weeks. At 3 postoperative months, radiographs revealed that the implants were well positioned. The muscle mass of the affected limb was significantly improved. The excursion angle of the left hip joint had increased from 100° to 115°. Until 6 months after the operation, the function of the affected limb had been improving without complications, such as luxation and implant failure. At the last follow-up exam, the patient showed satisfactory weight-bearing ambulation, without lameness associated with activity.

## Discussion

The change in congruity was confirmed with LCEA and CD measurements. Increased LCEA and decreased CD indicate increased congruity (3,4,6). In this case, incongruity after recurrent luxation from a failed TPO was ascertained through decreased LCEA and increased CD inversely. Due to luxation and degenerative changes on the left hip, THR was planned for revision. Unlike a normal hip, TPO-induced pelvic axis alterations results in technical difficulties for THR. Thus, acetabular angles had to be considered for the surgery plan, and they were thoroughly understood from the CT scan.

TPO has some complications, such as progressive degenerative joint disease and persistent joint incongruity. In dogs with excessive joint laxity, performing TPO cannot avoid joint incongruity. Recent studies have shown that TPO is focused on mitigating subluxation and improving function rather than completely preventing the onset or progression of OA (3,14). In this case, degenerative changes on the left hip joint started after ventral luxation during right THR surgery. Other factors may affect degenerative changes after luxation. First, TPO-induced morphologic changes at the pelvis are prone to result in a luxated hip joint. The pelvic axis was rotated ventrally and lifted caudally. A lifted caudal segment in the pelvic osteotomy showed an increased inclination angle

for the acetabulum, which increased the tendency of a femoral head to luxate caudally, resulting in hip instability and degenerative changes at the hip joint. Second, after closed reduction of the left hip joint during THR surgery, luxation occurred postoperatively. Recurrent luxation and instability could lead to articular cartilage damage and progress to joint degeneration. OA of the hip joint progresses in 55 to 62% of dogs after coxofemoral luxation, and it occurs more frequently in heavier patients.

For these reasons, OA eventually occurred, and THR surgery was indicated. Hemipelvis was not superimposed due to previous TPO surgery on the lateral radiographic view, which made it difficult to evaluate the pelvic axis. CT was performed to measure accurate acetabular angles. The measurement method for the acetabular angles was based on a previous paper (7,11).

If the THR cup is positioned according to altered angle of acetabulum, the possibility of ventrocaudal coxofemoral luxation could increase after actual surgery. Therefore, decreasing the angle of lateral opening (ALO) and inclination angle of the THR cup was planned for the rehearsal surgery using a 3D printed bone model. During the rehearsal surgery with the bone model, the acetabular medial wall thickness was measured through pinning and reaming. The osteophyte locations were confirmed for removal. Considering the CT data, when positioning the THR cup, the transverse bar of cup positioner was paralleled to the table to create an ALO of 45°, and the sagittal bar was adjusted to decrease the inclination angle, which was not based on the caudally lifted pelvic axis. The points derived from the rehearsal surgery were equally applied during the actual surgery, resulting in a successful outcome. In this case, the technical difficulties were overcome by using a 3d-printed bone model, which demonstrated successful results through customization of the surgical technique.

## Conclusion

Hip joint incongruity after recurrent luxation was confirmed through CT. TPO has some complications, such as progressive degenerative change and persistent incongruity. In this case, a ventrocaudally lifted pelvic axis and luxation resulted in degenerative changes to the hip joint. Accurate measurement of the acetabular angles and a 3d-printed bone model using CT data was useful in determining a surgical plan. THR after failed TPO was performed successfully by premeasuring the acetabular angles in the rehearsal surgery.

## Acknowledgement

This work was supported by Basic Science Research Program through the National Research Foundation of Korea funded by the Ministry of Education, Science and Technology (NRF-2015R1D1A1A01056945).

## References

1. Allen M. Advances in total joint replacement in small animals. *J Small Anim Pract* 2012; 53: 495-506.

2. Anderson A. Treatment of hip dysplasia. *J Small Anim Pract* 2011; 52: 182-189.
3. Fujiki M, Kurima Y, Yamanokuchi K, Misumi K, Sakamoto H. Computed tomographic evaluation of growth-related changes in the hip joints of young dogs. *Am J Vet Res* 2007; 68: 730-734.
4. Harada Y, Fujita Y, Taoda T, Yoshinori N, Yamaguchi S, Orima H, Tagawa M. Changes of hip joint congruity after triple pelvic osteotomy in the dog with hip dysplasia. *J Vet Med Sci* 2002; 64: 933-936.
5. Ito H, Takatori Y, Moro T, Oshima H, Oka H, Tanaka S. Total hip arthroplasty after rotational acetabular osteotomy. *J Arthroplasty* 2015; 30: 403-406.
6. Kishimoto M, Yamada K, Sa-Hun P, Muroya N, Watarai H, Anzai H, Shimizu J, Iwasaki T, Miyake Y-I, Wisner ER. Quantitative evaluation of hip joint laxity in 22 Border Collies using computed tomography. *J Vet Med Sci* 2009; 71: 247-250.
7. Leasure JO, Peck JN, Villamil A, Fiore KL, Tano CA. Inter- and intra-observer variability of radiography and computed tomography for evaluation of Zurich cementless acetabular cup placement ex vivo. *Vet Comp Orthop Traumatol* 2016; 29: 507-514.
8. Manley PA, Adams WM, Danielson KC, Dueland RT, Linn KA. Long-term outcome of juvenile pubic symphysiodesis and triple pelvic osteotomy in dogs with hip dysplasia. *J Am Vet Med Assoc* 2007; 230: 206-210.
9. Osawa Y, Hasegawa Y, Seki T, Amano T, Higuchi Y, Ishiguro N. Significantly poor outcomes of total hip arthroplasty after failed periacetabular osteotomy. *J Arthroplasty* 2016; 31: 1904-1909.
10. Peters CL, Beck M, Dunn HK. Total hip arthroplasty in young adults after failed triple innominate osteotomy. *J Arthroplasty* 2001; 16: 188-195.
11. Punke JP, Fox DB, Tomlinson JL, Davis JW, Mann F. Acetabular ventroversion with double pelvic osteotomy versus triple pelvic osteotomy: a cadaveric study in dogs. *Vet Surg* 2011; 40: 555-562.
12. Tobias K, Johnston S. Surgical therapy of canine hip dysplasia. In: *Veterinary small animal surgery*, 1<sup>th</sup> ed. Canada: Elsevier, 2012: 849-864
13. Vezzoni A, Boiocchi S, Vezzoni L, Vanelli A, Bronzo V. Double pelvic osteotomy for the treatment of hip dysplasia in young dogs. *Vet Comp Orthop Traumatol* 2010; 23: 444.