



Original Article

Effects of Muscle Energy Technique of Upper Trapezius and Sternocleidomastoid Muscles on Bell's Palsy



Jong-Hyeon Park ¹, Yoon-Joo Lee ², Hye-Min Ryu ¹, Seung-Jeong Lee ¹, Eun-Jin Park ¹, Choon-Ho Song ¹, Cheol-Hong Kim ¹, Hyun-Min Yoon ^{1,*}

¹ Department of Acupuncture & Moxibustion Meridian & Acupoint, College of Korean Medicine, Dong-Eui University, Busan, Korea

² Department of Acupuncture & Moxibustion Meridian & Acupoint, College of Korean Medicine, Dong-Eui University, Ulsan, Korea

ARTICLE INFO

Article history:

Submitted: June 27, 2017

Revised: August 9, 2017

Accepted: August 22, 2017

Keywords:

Bell's palsy, muscle energy technique, sternocleidomastoid muscle, upper trapezius

ABSTRACT

Background: The purpose of this study was to investigate the efficacy of muscle energy techniques (MET) of upper trapezius and sternocleidomastoid muscles on Bell's palsy.

Methods: In this retrospective study, we screened the medical records of patients with Bell's palsy who had received inpatient and outpatient treatment at the Department of Acupuncture & Moxibustion, Korean Medicine Hospital Dong-Eui University between November 28, 2016 and April 30, 2017. A total of 34 out of 93 Bell's palsy patients met the inclusion criteria. The 34 patients were divided into two groups: Group A patients had undergone Korean-Western combination treatment and MET of upper trapezius and sternocleidomastoid muscles; Group B patients had undergone Korean-Western combination treatment only. MET of upper trapezius and sternocleidomastoid muscles had been performed three times a week during the inpatient period, and two to three times a week during the outpatient period. Yanagihara scores had been assessed at the first visit, and 1, 2, 3, and 4 weeks after the first visit.

Results: Group A Yanagihara scores were significantly improved during each interval from the first visit to 4 weeks later. Group B Yanagihara scores were also significantly improved except during the first week. During every period, the improvements observed in Yanagihara score were significantly higher in Group A than in Group B.

Conclusion: These results suggest that MET of upper trapezius and sternocleidomastoid muscles may be effective treatment for Bell's palsy.

©2017 Korean Acupuncture & Moxibustion Medicine Society. This is an open access article under the CC BY-NC-ND license (<http://creativecommons.org/licenses/by-nc-nd/4.0/>).

Introduction

Facial nerves are mixed nerves consisting of motor, sensory, and parasympathetic nerves [1]. Facial nerves are also involved in facial muscle movement, tear and saliva secretion, tympanum protection, and taste sensation by the tongue [2].

Infra-nuclear facial nerve palsy without clear causes is referred to as idiopathic Bell's palsy [3] and represents the most common facial nerve disorder, with a prevalence of 11–40 cases per 100,000 persons. The incidence of Bell's palsy does not vary among different sex and age groups, but has been reported to be higher among patients with diabetes [2].

Vascular ischemia, viruses, genetic factors, and autoimmunity have all been highlighted as possible causes of Bell's palsy. Thus far,

vascular ischemia appears to be the most likely cause of Bell's palsy, and cold exposure, emotional shock, and anxiety are known to cause circulatory disturbance [4]. According to Korean medicine, Bell's palsy occurs when the harmful energy of a cold invades the meridian system in a weak state, as well as when stasis stagnates the meridian system, obstructs qi and blood, and blocks the flow of nutrients into muscles and tendons [3].

The major clinical symptoms of Bell's palsy include loss of wrinkles in the forehead due to facial nerve paralysis on one side of the face, epiphora due to an inability to close the eyes, ocular discomfort, and lip distortion toward the contralateral side. Minor symptoms include impaired taste at the tip of the tongue, sound sensitivity, and ringing in the ears [5]. Approximately 60% of patients with Bell's palsy experience pain in the ipsilateral mastoid

*Corresponding author.

Department of Acupuncture & Moxibustion Meridian & Acupoint, College of Korean Medicine, Dong-Eui University, 62 Yangjeong-ro, Busanjin-gu, Busan 47227, Korea
E-mail: 3rdmed@daum.net

<https://doi.org/10.13045/jar.2017.02131>

pISSN 2586-288X eISSN 2586-2898

©2017 Korean Acupuncture & Moxibustion Medicine Society, Published by E-Tree Publishing. This is an open access article under the CC BY-NC-ND license (<http://creativecommons.org/licenses/by-nc-nd/4.0/>).

as a preceding symptom, and severe paralysis occurs within the next 48 hours [6].

The muscle energy technique (MET) is a form of chuna manual treatment on fascia and is based on active muscle relaxation techniques that use the intrinsic energy of the muscles to relax and stretch stiff muscles [7]. Compared to other manipulative therapies, MET has a wider range of applications for treating the nervous and musculoskeletal systems, proceeds smoothly, and allows patients to actively participate in the treatment process [8]. The efficacy of MET has been proven both experimentally and clinically [8].

While manual therapy has been undergoing a change from techniques using fast and weak twisting movements to softer techniques that focus more on soft tissues [8], there have not been any clinical reports on the treatment of Bell's palsy using MET. Therefore, in this study, we retrospectively compared patients with Bell's palsy who received Korean–Western combination treatment and MET of upper trapezius and sternocleidomastoid (SCM) muscles with those who received Korean–Western combination treatment only.

Materials and Methods

Patients

We reviewed the medical records of patients who visited the Department of Acupuncture & Moxibustion, Korean Medicine Hospital Dong-Eui University who were diagnosed with Bell's palsy, and who had received inpatient and outpatient treatment between November 28, 2016 and April 30, 2017. Approval for the study was received from the institutional review board of Korean Medicine Hospital Dong-Eui University (IRB no. 2017-02).

The inclusion criteria were: (1) patients had undergone more than 4 weeks of treatment, including 7 days of inpatient treatment, following the initial diagnosis of Bell's palsy; (2) patients were aged 20–70 years; (3) patients had presented to hospital within 10 days of the onset of Bell's palsy; (4) patients had no previous history of stroke or cancer; and (5) patients had never received insulin injections for diabetes.

Of the 93 patients with Bell's palsy who were treated during the study period, 59 were excluded as they did not meet all of the inclusion criteria. Of the 34 patients who were included in this study, 17 received Korean–Western combination treatment and MET of upper trapezius and SCM muscles (Group A), and 17 received Korean–Western combination treatment only (Group B) (Fig. 1).

Treatments

Acupuncture

Disposable stainless steel needles (0.20 mm in diameter, 30.00 mm in length; Dong Bang Medical Co. Ltd., Daecheon, Chungcheongnam-do, Korea) were used to apply acupuncture twice daily during inpatient treatment, and two to three times a week during outpatient treatment. Acupuncture was applied on Chanjuk (BL2), Yangbaek (GB14), Sajukgong (TE23), Seungeub (ST1), Yeonghyang (LI20), Hagwan (ST7), Gwollyo (SI18), Sugu (GV26), Seungjang (CV24), Jichang (ST4), Hyeopgeo (ST6), and Yepung (TE17) on the ipsilateral side, and the stomach-tonification point on the contralateral side for 20 minutes.

Pharmacopuncture

The 10% sweet bee venom used in this study was produced at an extramural herbal dispensary of the Korean Pharmacopuncture Research Institute. A 1.0 mL disposable insulin syringe (29 G

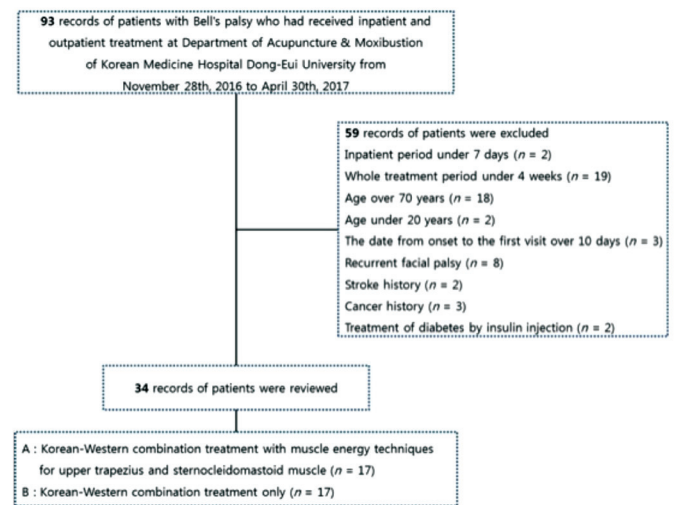


Fig. 1. Flowchart showing how patients were selected for inclusion.

× 1/2 inch; Shin Chang Medical Co. Ltd., Gumi, Korea) was used to inject the solution in Chanjuk (BL2), Yangbaek (GB14), Sajukgong (TE23), Seungeub (ST1), Yeonghyang (LI20), Hagwan (ST7), Gwollyo (SI18), Sugu (GV26), Seungjang (CV24), Jichang (ST4), Hyeopgeo (ST6), and Yepung (TE17) on the ipsilateral side. Separate injections were carried out to administer 0.05–0.10 mL of the solution per acupoint; total volume of solution injected per treatment was 0.5 mL. Pharmacopuncture therapy was performed once daily during inpatient treatment, and two to three times a week during outpatient treatment.

Herbal medicine

Depending on patients' symptoms, *Igigeopung Powder*, *Bohyeol Decoction*, *Ikgi Decoction*, and *Geopung Decoction* were administered (Table 1).

Western examination and treatment

All patients were diagnosed with Bell's palsy based on neurological test results. A nerve conduction velocity (NCV) test was performed 7–10 days after the onset of Bell's palsy to measure the severity of paralysis. Patients were orally administered high-dose steroids for the first 5 days. The dose was gradually reduced over the course of the next 5 days. Patients who refused pharmacotherapy or who were at high risk of side effects were excluded from steroid administration. Antiviral agents, drugs that improved blood circulation, and vitamins were also administered. To prevent corneal damage, an artificial solution and eye ointment were applied. Patients received facial massage and electrotherapy at a physical therapy center once daily (except during holidays) throughout the period of hospitalization.

MET of upper trapezius and SCM muscles

An acupuncture specialist performed MET on patients three times a week during the inpatient period and two to three times a week during the outpatient period. The precise protocols used are described below.

MET of the upper trapezius muscle: With the patient in the supine position, the therapist supported the back of the patient's

Table 1. Herbal Medicine Prescriptions

<i>Igigeopung Powder</i>	Root or rhizome of <i>Saposhnikovia Radix</i> -Root of <i>Paeoniae Radix Alba</i> (baked with alcohol)-Root of <i>Angelicae Dahuricae Radix</i> -Unripe pericarp of <i>Citrii Unshiu Immaturi Pericarpium</i> -Rhizome of <i>Cnidii Rhizoma</i> -Tuberous root of <i>Gastrodiae Rhizoma</i> -Root of <i>Angelicae Pubescentis Radix</i> -Rhizome of <i>Notopterygii Rhizoma</i> -Root of <i>Platycodi Radix</i> -Root of <i>Glycyrrhizae Radix</i> -Floral axis of <i>Schizonepetae Spica</i> -Fruit of <i>Ponciri Fructus Pericarpium</i> -Old peel of <i>Citri Reticulatae Pericarpium</i> -Tuberous root of <i>Arisaematis Rhizoma</i> -Root of <i>Linderae Radix</i> 5 g, Tuberous root of <i>Typhonii Tuber-Bombycis Corpus cum Batryticatus</i> 4 g
<i>Bohyeol Decoction</i>	Honey roasted root of <i>Astragali Radix</i> 8 g, Fruit of <i>Jujubae Fructus</i> 7 g, Sclerotium of <i>Poria (Hoelen)</i> -Root of <i>Atractylodis Rhizoma Alba</i> -Root of <i>Angelicae Gigantis Radix</i> -Roasted root of <i>Glycyrrhizae Radix</i> -Old peel of <i>Citri Reticulatae Pericarpium</i> -Root of <i>Ginseng Radix</i> -Rhizome of <i>Zingiberis Rhizoma Recens</i> -Root of <i>Rehmanniae Radix Preparat</i> 4 g, <i>Bombycis Corpus cum Batryticatus</i> -Root or rhizome of <i>Saposhnikovia Radix</i> -Tuberous root of <i>Pinelliae Rhizoma</i> -Rhizome of <i>Notopterygii Rhizoma</i> -Root of <i>Gentianae Macrophyllae Radix</i> -Tuberous root of <i>Arisaematis Rhizoma</i> 3 g, The whole of <i>Scorpio</i> -Alcohol-washed rhizome of <i>Cimicifugae Rhizoma</i> -Alcohol-washed root of <i>Bupleuri Radix</i> 1 g
<i>Ikgi Decoction</i>	Sclerotium of <i>Poria (Hoelen)</i> -Baked root of <i>Atractylodis Rhizoma Alba</i> -Root of <i>Paeoniae Radix Alba</i> -Rhizome of <i>Cnidii Rhizoma</i> -Root of <i>Angelicae Gigantis Radix</i> -Roasted root of <i>Glycyrrhizae Radix</i> -Honey roasted root of <i>Astragali Radix</i> -Old peel of <i>Citri Reticulatae Pericarpium</i> -Root of <i>Ginseng Radix</i> -Root of <i>Rehmanniae Radix Preparat</i> 6 g, <i>Bombycis Corpus cum Batryticatus</i> -Root or rhizome of <i>Saposhnikovia Radix</i> -Tuberous root of <i>Pinelliae Rhizoma</i> -Rhizome of <i>Notopterygii Rhizoma</i> -Root of <i>Gentianae Macrophyllae Radix</i> -Tuberous root of <i>Arisaematis Rhizoma</i> -Rhizome of <i>Cimicifugae Rhizoma</i> -Root of <i>Bupleuri Radix</i> 4 g, The whole of <i>Scorpio</i> 2 g
<i>Geopung Decoction</i>	Sclerotium of <i>Poria (Hoelen)</i> -Root of <i>Polygoni Multiflori Radix</i> 8 g, Rhizome of <i>Cnidii Rhizoma</i> -Pericarp of <i>Aurantii Pericarpium</i> -Rhizome of <i>Cyperii Rhizoma</i> -Root of <i>Linderae Radix</i> 6 g, Tuberous root of <i>Pinelliae Rhizoma</i> (treated with ginger juice)-Rhizome of <i>Atractylodis Rhizoma</i> -Root of <i>Angelicae Gigantis Radix</i> -Branch of <i>Cinnamomi Ramulus</i> -Root of <i>Paeoniae Radix Rubra</i> -Root of <i>Ginseng Radix</i> -Root of <i>Achyranthis Radix</i> 4 g, Root of <i>Aucklandiae Radix</i> 3 g-Root of <i>Glycyrrhizae Radix</i> 2 g

head with his contact hand, and placed his stabilizing hand on the patient's clavicle, which is where the insertion site of the upper trapezius muscle is located. The contact hand was used to bend the patient's neck forward, then rotate and bend it toward the ipsilateral side to check for an elastic barrier, and then to place it at a mid-point between the initial position and the fully rotated position. The patient was then asked to breathe in, hold their breath, and perform isometric contraction (20% of maximal force) in the direction that would allow the muscle's point of origin to get closer to its insertion, while the therapist pressed on the patient in the opposite direction. The patient was then asked to breathe out 6–7 seconds later, and the muscles—including those with an elastic barrier—were stretched while the patient was in a relaxed state. This process was repeated three to four times [7].

MET of the SCM muscle: The patient lay in the supine position with a cushion under the shoulder to keep the head slightly bent backward onto the bed [8]. The therapist placed his contact hand on the ipsilateral mastoid on the temporal region, which is the insertion site of the SCM muscle, and his stabilizing hand on the sternum, which is the point of origin. The patient was asked to rotate his head to the contralateral side and lift his head while holding his breath, while the therapist pressed on the patient in the opposite direction. The patient was then asked to breathe out 6–7

Table 2. The Yanagihara Unweighted Grading System

	Rating scale
1. At rest	0 1 2 3 4
2. Wrinkle forehead	0 1 2 3 4
3. Blink	0 1 2 3 4
4. Closure of eye lightly	0 1 2 3 4
5. Closure of eye tightly	0 1 2 3 4
6. Closure of eye on involved side only	0 1 2 3 4
7. Wrinkle nose	0 1 2 3 4
8. Whistle	0 1 2 3 4
9. Grin	0 1 2 3 4
10. Depress lower lip	0 1 2 3 4

seconds later, and the area where the contact hand was placed was diagonally pushed toward the foot on the same side to stretch the muscles while the patient was in a relaxed state. This process was repeated three to four times [7].

Methods

Data collection

Initial diagnosis, treatment progress, and NCV test results from patients' medical records were reviewed.

Facial paralysis assessment

We used the Yanagihara unweighted grading system (Y-system, Table 2) to assess the severity of facial paralysis. Facial paralysis measurements were taken on the first visit (P0), and 1 (P1), 2 (P2), 3 (P3), and 4 (P4) weeks after the first visit. The Y-system is an assessment method that classifies facial function into 10 different domains without weighting any values. Using the Y-system, facial paralysis can be easily and quickly assessed and quantified without the use of special equipment, while avoiding subjective errors. For these reasons, the Y-system is the most commonly used of all regional scales [9].

Statistical analyses

All statistical analyses were performed with SPSS version 18.0 for Windows (SPSS Inc., Chicago, IL, USA). Results are expressed as means \pm standard deviations. A Kolmogorov-Smirnov test was used to assess data for normality.

To test the homogeneity of categorical data for Group A and Group B, the Chi-square test was used for data with a normal distribution, and Fisher's exact test was used for data that did not follow a normal distribution. Student's t-test was used to test the homogeneity of continuous data that were normally distributed, and the Mann-Whitney U test was used for continuous data that were not normally distributed. The level of statistical significance was set at $p < 0.05$.

The significance of improvements in patient condition at different treatment intervals (P0 to P1, P1 to P2, P2 to P3, P3 to P4) within each group was tested with a paired t-test following a test for normality ($p < 0.001$). The significance of the differences in improvement in patient condition in each treatment period (P0 to P1, P0 to P2, P0 to P3, P0 to P4) between Group A and Group B was tested using Student's t-test following a test of normality ($p < 0.05$).

Results

General characteristics

The data extracted from the medical records of the 34 patients who were included in this study included age, sex, affected side, whether or not they took Western medicine, length of admission, NCV, and Yanagihara score. There were no statistically significant differences in any of these characteristics between Groups A and B (Table 3).

Causes of paralysis

Several causes of facial nerve paralysis were recorded: overwork, stress, exposure to cold, common cold, and idiopathic (Table 4). Multiple responses were allowed. Overwork and stress were the most common causes.

Symptoms at onset

The symptoms reported by patients at disease onset are shown in Table 5. Multiple responses were allowed. Almost two-thirds of patients experienced postauricular pain and lacrimation.

Yanagihara score

The Yanagihara scores for Groups A and B at P0, P1, P2, P3, and P4 are shown in Table 6. The treatment intervals between each of these time points were defined as follows: from the first visit to 1 week later (P01), from 1 week to 2 weeks later (P12), from 2 weeks to 3 weeks later (P23), and from 3 weeks to 4 weeks later (P34).

Within-group changes

Significant improvements in Yanagihara score were observed at all time intervals in Group A. In Group B however, significant improvements in Yanagihara score were observed at all time intervals except for P01 (Table 7).

Between-group comparison

Changes in Yanagihara score at each time period were calculated as differences in the score compared to that at the first visit. Significantly greater improvements were observed in Group A than in Group B for all time periods (Table 8).

Table 3. General Characteristics of Patients

	Group A (n = 17)	Group B (n = 17)	P
Age (y)	46.47 ± 13.92	50.53 ± 12.99	0.386*
Sex (male/female)	9/8	7/10	0.492†
Affected side (left/right)	10/7	9/8	0.730†
Western medicine (taking/not taking)	15/2	12/5	0.398‡
Length of admission (d)	14.76 ± 3.56	14.88 ± 4.61	0.934*
Nerve conduction velocity (%)	59.00 ± 16.16	50.29 ± 16.26	0.139*
Yanagihara score	12.00 ± 8.13	13.41 ± 5.12	0.231§

Data are presented as mean ± SD.

*Student's t-test.

†Chi-square test.

‡Fisher's exact test.

§Mann-Whitney U test.

Table 4. Causes of Paralysis*

Cause	Group A (n)	Group B (n)	Total (n)
Overwork	7	8	15
Stress	7	8	15
Exposure to cold	6	5	11
Common cold	3	2	5
Unknown	4	5	9

*Multiple responses were allowed.

Table 5. Symptoms at Onset*

Symptom	Group A (n)	Group B (n)	Total (n)
Postauricular pain	9	13	22
Lacrimation	10	11	21
Scheroma	9	9	18
Hyperacusis	2	3	5
Hypoacusis	0	1	1
Dysgeusia	5	5	10
Tinnitus	3	3	6
Dizziness	1	1	2
Other	2	1	3

*Multiple responses were allowed.

Table 6. Yanagihara Score

	Group A	Group B
P0	12.00 ± 8.13	13.41 ± 5.12
P1	17.76 ± 6.34	13.59 ± 7.14
P2	25.59 ± 6.58	20.18 ± 7.69
P3	31.06 ± 6.52	26.59 ± 8.27
P4	35.12 ± 5.31	30.18 ± 8.14

Data are presented as mean ± SD.

P0, the first visit; P1, 1 week after the first visit; P2, 2 weeks after the first visit; P3, 3 weeks after the first visit; P4, 4 weeks after the first visit.

Discussion

The motor nerve fibers from the motor nucleus of the facial nerve assist in controlling facial expressions and making the movements that are necessary for speech and mastication. Secretomotor fibers of the facial nerve, which originate from the superior salivary nucleus, regulate the secretory activities of the submandibular glands, sublingual glands, lachrymal glands, olfactory mucosa, and palatine mucosa. Special visceral afferent fibers of the facial nerve, which originate from the nucleus tractus solitarius, occupy two-thirds of the anterior region of the tongue and palate. They are responsible for taste sensation in the anterior two-thirds of the tongue and sensation in the anterior two-thirds of the soft palate [1].

Facial nerve paralysis can be classified as central or peripheral [3], and differentiating between the two types of paralysis is important. As the frontalis muscle is controlled by both hemispheres of the cerebrum, facial nerve paralysis due to upper motor neuron lesions affects the bottom two-thirds of the face only. In contrast, peripheral facial nerve lesions not only paralyze the muscles

Table 7. Within-Group Changes in Yanagihara Score*

	Group A		Group B	
	t	p	t	p
P01	4.858	< 0.001	0.119	0.907
P12	10.250	< 0.001	5.378	< 0.001
P23	6.344	< 0.001	5.684	< 0.001
P34	4.976	< 0.001	4.999	< 0.001

*Paired t-test.

P01, interval from the first visit to 1 week later; P12, interval from 1 week to 2 weeks later; P23, interval from 2 weeks to 3 weeks later; P34, interval from 3 weeks to 4 weeks later.

Table 8. Between-Group Comparison of Changes in Yanagihara Score*

	Group A	Group B	t	p
P01	5.76 ± 4.89	0.18 ± 6.14	2.936	0.006
P02	13.59 ± 6.37	6.76 ± 6.08	3.197	0.003
P03	19.06 ± 7.47	13.18 ± 7.25	2.330	0.026
P04	23.12 ± 7.72	16.76 ± 6.33	2.624	0.013

Data are presented as mean ± SD.

*Student's t-test.

P01, interval from the first visit to 1 week later; P02, interval from the first visit to 2 weeks later; P03, interval from the first visit to 3 weeks later; P04, interval from the first visit to 4 weeks later.

involved in the closing of the mouth and eyes but also affect the frontalis muscle, thus obscuring wrinkles on the forehead [10]. Peripheral facial nerve paralysis can be classified as nuclear paralysis or infra-nuclear paralysis. Infra-nuclear facial nerve paralysis without a clear cause is referred to as Bell's palsy [3].

Bell's palsy suddenly occurs without any evident causes or injuries. The most likely cause of Bell's palsy is vascular ischemia. It has been hypothesized that constriction of the arterial vessels interferes with blood flow into the facial nerves, thus causing the nerves within the facial canal to swell and become pressurized, consequently leading to paralysis [4].

Postauricular pain is the most common early symptom of Bell's palsy [11]. When the patient tries to firmly close the eye on the paralyzed side of the face, the pupil of the eye moves abnormally upward relative to the pupil of the other eye; this symptom is referred to as Bell's phenomenon [10]. Patients with Bell's palsy may not be able to wrinkle their forehead or whistle, and food may collect within the mouth on the ipsilateral side such that fluids leak from the mouth. If the chorda tympani nerve becomes affected, taste sensation may become impaired in two-thirds of the tongue tip. If the stapedius muscle becomes affected, sound sensitivity may also occur.

Aside from acupuncture and herbal medicine, Korean medical treatments include electroacupuncture [12], pharmacopuncture [13], embedding therapy [14], acupotomy [15], and chuna manual therapy [16,17]. These therapies have been clinically practiced, and their efficacy has been clinically proven. In Western medicine, the administration of steroids and antiviral agents, physical therapy, and surgery are used [5].

MET stretches shortened muscles to relieve tenderness and pain, and to recover the original state of the muscles. This not only removes trigger points within the muscles, but also relieves pain in the ligament or periosteum at the attachment point. In a study by Lewit and Simons, MET was effective for 330 out of 351 muscles, muscle relaxation was observed in 63% of all patients in the second

examination 3 months later, and pain relief was achieved in 23% of muscles [18].

With regard to the mechanism underlying MET, during isometric exercise, in which the forces applied by the therapist and the patient onto the agonistic muscle match, reciprocal inhibition occurs in the antagonistic muscle, and post-isometric relaxation occurs in the agonistic muscle due to physiological and neurological reactions. Thereby, contracted muscles and tissues can be stretched and relaxed.

MET resembles chuna manual therapy for the meridian muscle in Korean medicine [19], which applies stimuli onto the surface of the patient's body to control the meridian system, to prevent and treat diseases. Therapeutic effects are achieved through correction of particular parts of the body such as joints and the skeletal structure using manual force [20].

The effectiveness of chuna manual therapy for treating Bell's palsy has been reported in a clinical study by Park et al [16], in which the danmuji anchu traction technique was performed, and in a clinical study by Jeong et al [17], in which JS supine cervical distraction, supine cervical manipulation, and cranial base release were performed. These chuna manual therapy techniques for Bell's palsy fall under the areas of chuna joint distraction therapy, chuna spine and joint manipulation therapy, and chuna craniosacral therapy. However, clinical research on fascia chuna therapy for Bell's palsy is currently lacking.

The Department of Acupuncture & Moxibustion, Korean Medicine Hospital Dong-Eui University has been performing MET of upper trapezius and SCM muscles associated with facial nerve disorders to treat Bell's palsy. Significantly better treatment outcomes have been observed in patients who receive Korean-Western combination treatment and MET compared to patients who receive Korean-Western combination treatment only. In this retrospective analysis of the medical records of 34 patients who were diagnosed with Bell's palsy and who met the criteria for inclusion into the study, overwork and stress were the most common causes of paralysis, followed by cold exposure, unknown causes, and the common cold. Postauricular pain was the most common early symptom at onset, followed by lacrimation, scheroma, dysgeusia, tinnitus, hyperacusis, dizziness, and hypoacusis.

In Group A (patients who had received Korean-Western combination treatment and MET of upper trapezius and SCM muscles), Yanagihara scores were significantly improved at all time intervals (P01, P12, P23, P34). Yanagihara scores were also significantly improved in Group B (patients who had received Korean-Western combination treatment only) at all time intervals except for P01. For each of the time periods P01, P02, P03 and P04, the improvements observed in Yanagihara score were significantly greater in Group A than in Group B. Based on these results, the treatment of Bell's palsy with MET of upper trapezius and SCM muscles may be beneficial. The theoretical background on the application of MET on these two muscles is given below.

First, the effects of treatment on the SCM muscle on Bell's palsy can be considered from an anatomical perspective. To begin with, its effects on the autonomic nervous system can be considered. The SCM muscle is anatomically closely associated with the stellate ganglion, which is a central ganglion through which sympathetic nerves that travel to the head, neck, and chest pass [21], and carotid arteries and the SCM muscle are ventrally distributed [22]. The Gisa (ST11) of the stomach meridian is an acupuncture point located on the inner side of the SCM muscle and corresponds anatomically to the stellate ganglion. Trigger points of the SCM muscle cause symptoms of autonomic nerve disorders such as headache, dizziness, and nausea [23], possibly by contracting to

stimulate the stellate ganglion. In Western medicine, blockade of the autonomic nervous system alleviates hyperactivation of the autonomic nervous system and subsequently increases peripheral blood flow, and stellate ganglion block is used in the treatment of facial nerve paralysis [22]. Murakawa et al [24] performed stellate ganglion block in 35 patients with Bell's palsy and observed significant improvements in the blood flow of the common carotid arteries. Since Bell's palsy is known to develop as a result of reduced microcirculation in the facial nerves, a stellate ganglion block may treat Bell's palsy by improving blood flow in the common carotid arteries. Lim et al [25] found significantly higher low frequency/high frequency ratios in patients with Bell's palsy than in normal patients. The low frequency/high frequency ratio is used as a marker of regulation in the autonomic nervous system. It is directly proportional to the activity of the sympathetic nervous system and inversely proportional to the activity of the parasympathetic nervous system. Kim et al [26] reported improvements in facial blood circulation after performing acupuncture and manual therapy on the SCM muscle. In summary, relaxing the SCM muscle reduces stimulation of the stellate ganglion, alleviates hyperactivation of the sympathetic nervous system, and increases peripheral blood flow in the face, representing an effective method for treating Bell's palsy.

Furthermore, because the SCM muscle is anatomically associated with cervical arteries, veins, and lymph, constriction of the SCM muscle may reduce blood flow to the head and neck by applying pressure to the cervical arteries, veins, and lymph, causing facial swelling [23], while relaxation of the SCM muscle may promote blood circulation in the head and neck.

In addition, the sternal and clavicular branches of the SCM muscle both attach to the mastoid [27], and facial nerves exit the cranial cavity through the stylomastoid foramen located on the anteromedial side of the mastoid [28]. Around this location, they communicate with the vagus nerve, the auricular branches of the glossopharyngeal nerve, the internal carotid plexus, and the trigeminal nerves [1]. The posterior auricular nerve separates from the facial nerves as it exits from the stylomastoid foramen. After passing through the anterior margin of the SCM muscle, it travels upward to receive sensory information from the mastoid surface and the auricle, and communicates with the cervical plexus through the greater auricular nerve and the lesser occipital nerve. The lesser occipital nerve travels along the posterior margin of the SCM muscle, curves and travels upward, and distributes throughout the retroauricular area. The greater auricular nerve exits the posterior margin of the SCM muscle, travels upward along the posterior region of the external jugular vein, and is distributed to the surface of the parotid gland, auricle, and mastoid [29]. If the mandible is pushed back due to problems with the SCM muscle, the Wangol (GB12) area can become compressed. Therefore, because tension in the SCM muscle directly and indirectly applies pressure on the nerves around the mastoid, problems with the SCM muscle must be considered a symptom preceding Bell's palsy when patients complain of pain in the Wangol (GB12) area [23].

Second, the effects of MET of upper trapezius and SCM muscles can be understood in terms of its cervical alignment. The upper fibers of the trapezius muscle are controlled by the same accessory nerves that control the SCM muscle and are located on the agonist and antagonist muscles. Constriction of these muscles leads to neck pain, and chronic stiffness can cause degenerative changes to the cervical spine [23].

In addition, some of the nerve fibers of the trigeminal nerve enter the pons, form the spinal tract that travels down toward the spinal cord, and form a synapse at the spinal nucleus located at the medial side of the spinal tract. The spinal nucleus of the trigeminal

nerve is located immediately below the principal sensory nucleus of the pons and extends to the C2 spinal cord level [30].

Within the face, heterogeneous nervous communication occurs between facial nerves and the trigeminal nerve. Facial nerves meet the supraorbital nerve, which branches off from the ophthalmic nerve (V1), the zygomatic nerve and the infraorbital nerve of the maxillary nerve (V2), and the auriculotemporal nerve, buccal nerve, and lingual nerve of the mandibular nerve (V3). The connections between facial nerves and the trigeminal nerve provide afferent pathways that carry proprioceptive information necessary for sophisticated movements of complex facial muscles and play a physiological role in the recovery of damaged nerves [31].

In summary, treatment of the upper trapezius and SCM muscles can contribute to the recovery of a normal cervical alignment, and affects activation of the spinal nucleus of the trigeminal nerve that extends down to the C2 spinal cord level. An activated trigeminal nerve may play a physiological role in the recovery of damaged facial nerves.

Third, the association between the face and the upper trapezius and SCM muscles may be considered in terms of the meridian muscle. Citing the anatomical reports on the three yang meridian muscles of the hand by Park et al [32–34], the anatomical association between the neck and face can be explained through the routes in which the meridian muscle travels. The large intestine meridian muscle connects the trapezius muscle (LI16), the SCM muscle (LI17–18), the greater auricular nerve (LI18), the accessory nerve (LI18), the SCM branches of the external carotid artery (LI18), the orbicularis oris superior muscle (LI19–20), the infraorbital nerve (LI19–20), the facial artery (LI19–20), and facial nerve (LI20) [32]. The arm greater yang small intestine meridian muscle connects the trapezius muscle (SI12–15), the accessory nerve (SI12–17), the SCM muscle (SI16–17), the external jugular vein (SI16–17), the facial nerve (SI17), the sympathetic trunk (SI17), the posterior auricular artery (SI17), the internal jugular vein and internal carotid artery (SI17), the zygomatic muscle (SI18), the masseter muscle (SI18), the zygomatic branch of the facial nerve (SI18), the transverse facial artery and vein (SI18), the maxillary artery branch (SI18), and the temporal branch of the facial nerve (SI19) [33]. The triple energizer meridian muscle connects the trapezius muscle (TE15), the accessory nerve (TE16–17), the SCM muscle (TE16–18), the facial nerve (TE17–18), the internal jugular vein (TE17), the temporal branch of the facial nerve (TE20–23), the orbicularis oculi muscle (TE23), and the zygomaticotemporal artery and vein (TE23) [34]. Therefore, MET performed on the upper trapezius and SCM muscles affects activation of the facial structures that are connected through meridian muscles and may have significant therapeutic effects against Bell's palsy.

Lastly, the effects of MET of upper trapezius and SCM muscles can be understood in terms of the similarity between symptoms of Bell's palsy and pathology of the two muscles. The trigger points of the upper trapezius muscle and of the SCM muscle cause referred pain in the face, which tends to be misdiagnosed as atypical facial pain. Pain from the sternal branch of the SCM muscle occurs in the cheek, the temporal region, and the orbit. Pain from the clavicular branch of the SCM muscle occurs in the frontal lobe, deep inside the ipsilateral ear, and on the back of the ear or on the auricle. When trigger point number 1 of the upper trapezius muscle fiber becomes activated, pain travels along the lateral surface of the neck on the ipsilateral side up to the mastoid and may spread to the masseter muscle. In addition, the autonomic symptoms of the sternal branch of the SCM muscle may cause excessive tearing on the ipsilateral side, and proprioceptive symptoms of

the clavicular branch can cause positional dizziness, vertigo, and hearing impairment on the ipsilateral side [27]. Therefore, referred pain in the facial area indicates that the face is affected by the upper trapezius muscle and the SCM muscle, and can be seen to share similar symptoms with Bell's palsy such as excessive tearing, hearing impairment, and dizziness.

In this study, it was observed that MET of upper trapezius and SCM muscles had positive effects on Bell's palsy. However, due to the retrospective nature of the study, we could not systematically control for the effects of selection bias. Furthermore, due to the small sample size of 34 patients and the limited treatment period of 4 weeks, we could not investigate post-treatment progress or complications. There is a need for a systematic randomized controlled trial of MET for the treatment of Bell's palsy, with sufficient sample size and long-term patient monitoring.

Conflicts of Interest

All authors have no conflicts of interest to declare.

References

- [1] Netter FH. The CIBA Collection of Medical Illustrations: Nervous System, Anatomy and Physiology. Seoul (Korea): Jeongdam;2000. 92p, 102p.
- [2] Korean Neurological Association. Neurology, 2nd ed. Seoul (Korea): Beomun Education;2012. 32p, 724p. [In Korean]
- [3] Korean Acupuncture & Moxibustion Medicine Society. Acupuncture Medicine. Seoul(Korea): Hanmi Medical;2016. p.638-640. [In Korean]
- [4] Baek MK. The Newest Otolaryngology. Seoul(Korea):Ilchokak;1997. p.121-127. [In Korean]
- [5] Yang HJ, Joo HA, Baek SC, Park JS, Hong SH. A clinical report on 35 inpatients with facial paralysis—effects of early Oriental medicine treatment on House-Brackmann grade in Bell's palsy. J Korean Med Ophthalmol Otolaryngol Dermatol 2011;24:108-118. [In Korean]
- [6] Korean Society of Otorhinolaryngology-Head and Neck Surgery. Otolaryngology Head and Neck Surgery I. Seoul(Korea):Ilchokak;2010. 962p. [In Korean]
- [7] Korean Society of Chuna Manual Medicine for Spine & Nerves. Chuna Manual Medicine, 2nd ed. Seoul (Korea):Author;2014. p.274-275, 278p. [In Korean]
- [8] Chaitow L. Muscle Energy Techniques, 2nd ed. Seoul(Korea): Daehakseorim;2005. p.1-12, 160p. [In Korean]
- [9] House JW. Facial nerve grading system. Laryngoscope 1983;93:1056-1069.
- [10] Netter FH. The CIBA Collection of Medical Illustrations: Nervous System, Neurologic and Neuromuscular Disorders. Seoul(Korea):Korea Medical Book;2008. p.51-2, 305p. [In Korean]
- [11] Koo GH. Facial nerve palsy. Korean J Pain 1996;9:14-25. [In Korean]
- [12] An BJ, Song HS. Effect of electroacupuncture on patients with peripheral facial paralysis. The Acupuncture 2005;22:121-129. [In Korean]
- [13] Lee CW, Kim HG, Heo SW, Jung KK, Ahn CB, Song CH, et al. The clinical study about Honilirls placenta herbal acupuncture on Bell's palsy. J Pharmacopuncture 2005;8:87-97. [In Korean]
- [14] Kang EK, Kim JH, Seo HS. The clinical investigation studies in peripheral facial paralysis using needle-embedding therapy. J Korean Med Ophthalmol Otolaryngol Dermatol 2009;22:118-127. [In Korean]
- [15] Lee ES, Jeong JY, Seo DG, Shin SY, Seo JC, Seo YJ, et al. Clinical research of cervical acupotomy effects with acupuncture on facial & trigeminal nerve branch on peripheral facial paralysis and postauricular pain. The Acupuncture 2014;31:143-154. [In Korean]
- [16] Park JH, Lee CH, Lee YH, Kwon GS, Yoon HM, Jeun DS, et al. The clinical research of the effectiveness of "Danmuji Anchu Traction technique" on acute peripheral facial paralysis. J Korea Chuna Man Med Spine Nerves 2011;6:43-52. [In Korean]
- [17] Jeong JY, Lee ES, Seo DG, Shin SY, Kim SY, Kwon HK, et al. The clinical research of cervical chuna treatment's effects on Bell's palsy. The Acupuncture 2014;31:45-55. [In Korean]
- [18] Chaitow L. Muscle Energy Techniques, 3rd ed. Seoul(Korea): Koonja;2008. 136p, p.183-184. [In Korean]
- [19] Kweon JJ, Lim HH, Song YK. Analysis of osteopathic manipulation and study on relationship with chuna manual therapy for meridian sinew system. J Oriental Rehab Med 2011;21:171-188. [In Korean]
- [20] Hong SY, Lim HH. The study on clinical application of osteopathy to Oriental medicine. J Korea Chuna Man Med Spine Nerves 2002;3:85-96. [In Korean]
- [21] Han SW, Cheun JK, Lee JK, Park WK, Kim JG. Hemodynamic changes and clinical symptoms resulting from stellate ganglion block. Korean J Anesthesiol 2000;38:1009-1016. [In Korean]
- [22] Chan K. Nerve block for pain management. J Korean Acad Fam Med 2000;21:883-891. [In Korean]
- [23] Jeong HW. Introduction to Muscology. Seoul, Korea: Donga-Art, 2007:11-62. [In Korean]
- [24] Murakawa K, Ishimoto E, Noma K, Ishida K, Nishijima M, Izumi R. Circulatory effect of stellate ganglion block in idiopathic facial palsy. Masui 1994;43:356-60.
- [25] Lim DJ, Hwang GH, Hwang JS, Cho HS, Kim KH, Kim KS. Study of the relation of autonomic nerve system and peripheral facial palsy by the heart rate variability. The Acupuncture 2005;22:51-60. [In Korean]
- [26] Kim EJ, Kim JS, Yu SH, Rho HS, Kim DH, Kim HG, et al. Influence of the neck acupressure massage and the neck cream including Korean herbal extract on the neck wrinkles and facial blood circulation. J Korea Institute Oriental Med Inform 2009;15:85-91. [In Korean]
- [27] Simons DG, Travell JG, Simons LS. Travell & Simons' Myofascial Pain and Dysfunction: The Trigger Point Manual, Volume 1. Upper Half of Body, 2nd ed. Seoul (Korea): Yeongmun;2003. p.278-288, p.308-318. [In Korean]
- [28] Shin HJ, Kwon YW, Cho SM, Kim CH, Park JU. Eagle's syndrome presenting unilateral facial nerve palsy: case report. J Korean Assoc Maxillofac Plast Reconstr Surg 2010;32:467-472. [In Korean]
- [29] Janfaza P, Nadol JB, Galla RJ, Fabian RL, Montgomery WW. Surgical Anatomy of the Head and Neck. Seoul (Korea): Beommunsa;2004. 43p., 558p. [In Korean]
- [30] Lee WT, Park KA. Medical Neuroanatomy. Seoul (Korea):Medical Book;2008. p51-52, 305p. ISBN: 978-89-7043-637-1 [93510]. [In Korean]
- [31] Yang HM, Hu KS, Kim HJ. Anatomical and functional consideration of the trigemino-facial nervous communication and facial expression muscles. Korean J Phys Anthropol 2013;26:1-12. [In Korean]
- [32] Lee JM, Sim Y, Park KS. Anatomy of large intestine meridian muscle in human. Korean J Acupunct 2002;19:15-24. [In Korean]
- [33] Park KS. Anatomical study on the arm greater yang small intestine meridian muscle in human. J Pharmacopuncture 2004;7:57-64. [In Korean]
- [34] Park KS. Anatomical observation on the triple energizer meridian muscle in human. Korean J Acupunct 2007;24:65-77. [In Korean]