



Case Report

Effects of Acupuncture Treatment and Taping Therapy After Lisfranc Joint Injuries: A Case Report



Shin-Ae Kim¹, Su-Woo Kang¹, Eun-Ji Lee¹, Min-Kyung Kwak², Hui-Gyeong Jeong³, Jae-Uk Sul^{1,*}

¹ Chung-Yeon Korean Medicine Hospital, Gwangju, Korea

² College of Oriental Medicine, Dongshin University, Gwangju, Korea

³ Haeundae Jaseng Hospital of Korean Medicine, Busan, Korea

ARTICLE INFO

Article history:

Submitted: July 7, 2017

Revised: September 12, 2017

Accepted: September 15, 2017

Keywords:

acupuncture, fracture,
Lisfranc joint,
metatarsal bone,
tarsal bone

ABSTRACT

The effects of acupuncture treatment and taping therapy on a 22-year-old man who suffered from left foot pain due to Lisfranc joint injury were examined. Fractures of the first, second, and third metatarsal bones and a cuneiform bone were treated with acupuncture and taping therapy from March 24, 2017 to May 4, 2017. The patient was evaluated using the American Orthopaedic Foot & Ankle Society's Ankle-Hindfoot Scale. His Ankle-Hindfoot Score increased from 27 points pre-treatment to 65 points post-treatment. There were no side effects. While the improvement observed in this patient is encouraging, no definitive conclusion on the effects of acupuncture treatment and taping therapy on Lisfranc joint injuries can be reached without further large-scale study.

©2017 Korean Acupuncture & Moxibustion Medicine Society. This is an open access article under the CC BY-NC-ND license (<http://creativecommons.org/licenses/by-nc-nd/4.0/>).

Introduction

The central and anterior parts of the foot are composed of the cuneiform and cuboid bones, the metatarsals, and the Lisfranc ligament complex that supports these joints. These well-organized anatomical structures—especially the Lisfranc ligament complex—ensure stability and allow body weight to be evenly distributed on the ground while walking.

The functional-anatomical structure of the Lisfranc ligament complex is as below. The base of the second metatarsal bone is arranged to function as the key between the proximal regions of the medial and lateral cuneiform bones. This morphological characteristic prevents movement of the metatarsal on the frontal plane and ensures stability during walking. In addition, the bases of the second, third, and fourth metatarsal bones create a roman arch so there is stability in a cross section against load; this is also related to the stability of the Lisfranc joint [1]. Thus, injuries in that area can significantly disrupt the stability of the foot by creating an unfavorable environment for standing and walking.

Most injuries to this area are reportedly caused by falls, traffic accidents or work-related damage [2]. There is a need for careful examination of the affected lesion because of its ability to induce

gait disturbances. However, approximately 20% of these injuries are not diagnosed early or frequently overlooked.

It is necessary to study the methods for rehabilitation because the injuries often cause pain during walking and gait disturbance due to impaired structural stability [3]. Primary treatments for Lisfranc joint injuries are fixation with a cast, non-invasive manual reposition, fixation with Kirschner wires, and surgery using screws and wires after open reduction [4,5].

In this report, we describe the case of a patient who suffered injury to the Lisfranc joint and ligament complex. He experienced edema and redness of the left foot, gait disturbance, and persistent pain while walking and standing after bone healing. We applied acupuncture treatment and taping therapy.

Case Report

On December 11, 2016, a 22-year-old male patient presented to a Western medicine hospital with left foot pain after a Kimchi refrigerator-sized object fell onto his left foot. X-ray taken on the same day showed fractures in the second and third metatarsal bones (Fig. 1). On December 12, 2016, computed tomography (CT) and magnetic resonance imaging (MRI) of his left foot

*Corresponding author.

Chung-Yeon Korean Medicine Hospital, 9/F, 64 Sangmujungang-ro, Seo-gu, Gwangju 61949, Korea E-mail: sjuomd@hanmail.net (J.-U. Sul)

<https://doi.org/10.13045/jar.2017.02152>

pISSN 2586-288X eISSN 2586-2898

©2017 Korean Acupuncture & Moxibustion Medicine Society, Published by E-Tree Publishing. This is an open access article under the CC BY-NC-ND license (<http://creativecommons.org/licenses/by-nc-nd/4.0/>).

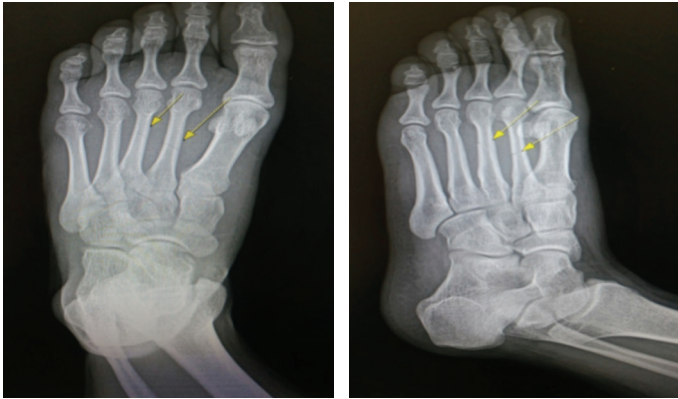


Fig. 1. X-ray images taken on December 11, 2016.

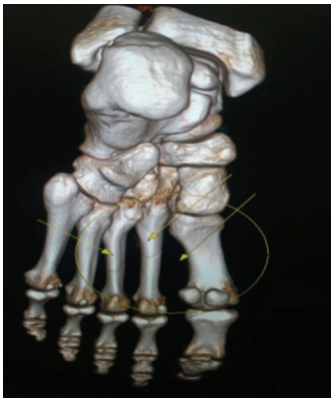

Fig. 2. Computed tomography on December 12, 2016 revealed cortical fracture at the base of the first metatarsal bone.

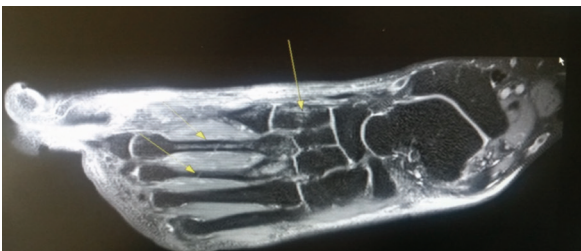

Fig. 3. Magnetic resonance imaging on December 12, 2016 showed bone marrow edema at the medial cuneiform bone.

revealed Lisfranc joint injury and fractures of the first, second, and third metatarsals and a cuneiform bone (Figs. 2 & 3). On December 13, 2016, he underwent surgery (fixation of K-wires and screws). On March 10, 2017, the K-wires and screws in the metatarsals and medial cuneiform bone were removed. However, as the patient continued to experience persistent left foot pain, he visited a Korean medicine hospital and received a total of 23 outpatient treatments from March 24, 2017 to May 4, 2017. Before his treatment at the Korean medicine hospital, the patient provided written informed consent for his case details and photographs to be used in this report.

Treatment methods

Acupuncture treatment

Acupuncture needles were inserted at six acupoints for 10 minutes on the left foot: GB41 (足臨泣), GB40 (丘墟), BL62 (申脈),

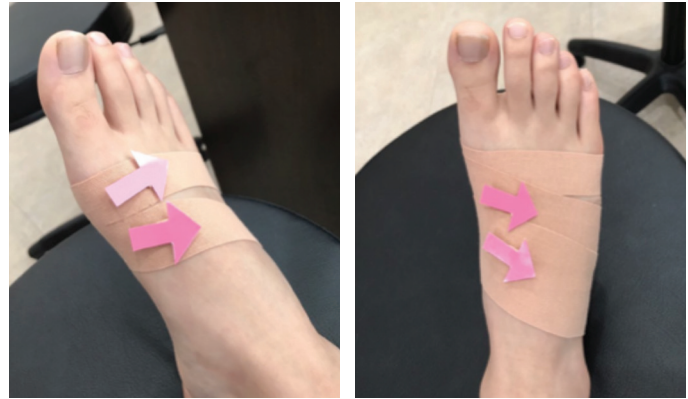

Fig. 4. Taping therapy of the foot.

GB39 (縣鍾), GB34 (陽陵泉), and SP9 (陰陵泉). The one-insertion method (單刺法) after rotation technique was used, eliciting an aching and dull sensation. The depth of needle insertion was within 10 mm. Disposable stainless steel needles (0.25 mm in diameter, 30.00 mm in length; Dong Bang Medical Co. Ltd., Daecheon, Chungcheongnam-do, Korea) were used. Electroacupuncture stimulation is a type of low-frequency electrical stimulation therapy. An electroacupuncture stimulator (GP-304; GOODPL Inc., Wonju, Korea) was used for pain relief and muscle relaxation. Electrical stimulation was applied via bipolar electrodes at a constant mode for 10 minutes, with modulated waves of 10 Hz and 100 Hz. Frequency modulation was controlled by the electroacupuncture stimulator itself. There were no side effects from acupuncture treatment.

Taping therapy

Acupuncture was combined with taping therapy to stabilize the fractured site and improve gait. The tape used was 5 cm in diameter (Kinesiology Tape; Nitto Denko Corp., Osaka, Japan). The starting point of the first tape was on the plantar surface of the first metatarsal and its endpoint was on the back of the fifth metatarsal so that the first metatarsal was pulled toward the plantar region. The second tape started from the center of the dorsum of the foot and was wrapped around the foot to cover the starting point of the first tape so that it could be pulled in the same direction (Fig. 4). Taping therapy was performed after acupuncture treatment. A total of eight taping therapy treatments were performed from April 3, 2017 to May 4, 2017. There were no side effects from taping therapy.

Assessment

The Ankle-Hindfoot Scale (AHS) of the American Orthopaedic Foot & Ankle Society [6] is a tool that was developed to evaluate the various anatomical sites of the foot (Table 1). The AHS is scored out of 100 points and covers the three domains of pain (40 points), function (50 points) and alignment (10 points).

Treatment progress

Overall AHS score improved from 27 points on March 27, 2017 to 65 points on April 24, 2017. In the pain domain, the score increased from 0 point (severe, almost always present) on March 27 to 20 points (moderate, daily) on April 24. In the function domain, for "Activity limitations, support requirement", the score increased from 4 points to 7 points. For "Ankle-hindfoot stability (anteroposterior, varus valgus)", the score increased from 0 point to 8 points.

Table 1. Ankle-Hindfoot Scale (100 points total)

Pain (40 points)	
None	40
Mild, occasional	30
Moderate, daily	20
Severe, almost always present	0
Function (50 points)	
Activity limitations, support requirement	
No limitations, no support	10
No limitation of daily activities, limitation of recreational activities, no support	7
Limited daily and recreational activities, cane	4
Severe limitation of daily and recreational activities, walker, crutches, wheelchair, brace	0
Maximum walking distance, blocks	
> 6	5
4-6	4
1-3	2
< 1	0
Walking surfaces	
No difficulty on any surface	5
Some difficulty on uneven terrain, stairs, inclines, ladders	3
Severe difficulty on uneven terrain, stairs, inclines, ladders	0
Gait abnormality	
None, slight	8
Obvious	4
Marked	0
Sagittal motion (flexion plus extension)	
Normal or mild restriction ($\geq 30^\circ$)	8
Moderate restriction (15-29°)	4
Severe restriction ($< 15^\circ$)	0
Hindfoot motion (inversion plus eversion)	
Normal or mild restriction (75-100% normal)	6
Moderate restriction (25-74% normal)	3
Marked restriction ($< 25\%$ normal)	0
Ankle-hindfoot stability (anteroposterior, varus valgus)	
Stable	8
Definitely unstable	0
Alignment (10 points)	
Good, plantigrade foot, midfoot well aligned	10
Fair, plantigrade foot, some degree of midfoot malalignment observed, no symptoms	8
Poor, nonplantigrade foot, severe malalignment, symptoms	0

On May 2, 2017, radiological examination showed that the fracture lines in the second and third metatarsal shafts were slightly blurred and not well observed (Fig. 5). Compared to the X-ray taken on December 11, 2016, the fracture on the second metatarsal shaft was still present (Fig. 1).

Discussion

We evaluated the effects of Korean medical treatment on the patient's residual symptoms after surgical treatment of Lisfranc joint injuries.

Lisfranc joint injuries are frequently caused by external damage. There may only be ligamentous injury, but if there is also direct bone injury, then it is easily diagnosed at the initial stage [7,8]. However, when the ligamentous complex is also damaged or a bone is injured alone, missed diagnosis or misdiagnosis can occur and lead to chronic pain and walking disorders after convalescence [9-11]. Open reduction and internal fixation are generally

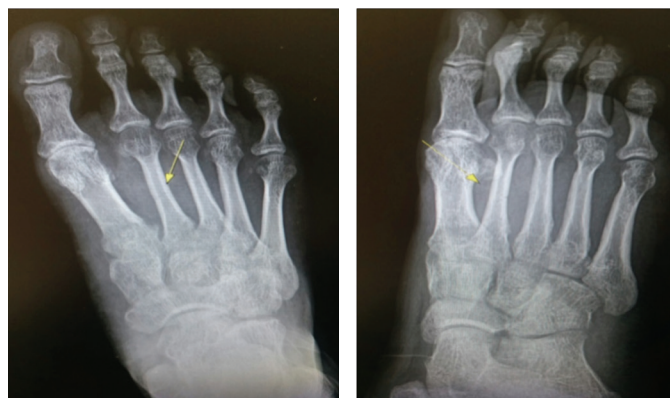

Fig. 5. X-ray images taken on May 2, 2017.

recommended for the treatment of Lisfranc joint injuries. But despite adequate treatment, complications such as osteoarthritis and gait disturbances may occur, so secondary arthrodesis is recommended after initial surgery [12].

The most common complication of Lisfranc joint injuries is traumatic arthritis, which is known to be caused by insufficient anatomical reduction. Even if appropriate surgical intervention had been undertaken at the initial stage, post-traumatic foot deformity may occur in the absence of proper management [13,14]. So it is necessary to secure anatomical stability to prevent the occurrence of traumatic arthritis.

To ensure stability, the use of a functional foot orthotic or splint may be considered. However, a skin-contact device such as tape may be helpful for stabilization if walking exercise is being considered. In our patient, taping therapy was used to limit the extorsion of the first and second metatarsal bones in the Lisfranc joint so that the arch of the foot could not be collapsed. Kinesio taping is known to reduce pain and enhance muscle function and circulation. In addition, ankle joint stability is improved when taping is used [15]. In a study of nine collegiate volleyball athletes, static balance was significantly improved right after attachment of the tape compared with before attachment of the tape. Ankle taping could be a good way to prevent ankle injury [16]. The taping technique used in our patient was a new skill that is different from the conventional taping technique. It was performed by wrapping around the inside of the big toe towards the direction of the dorsum of the foot in accordance with the patient's situation. The taping therapy ensured that the Lisfranc joint was stable during recovery and helped the patient to gain mobility during gait training. After taping, the patient's walking and pain when standing improved remarkably.

It has been reported in previous studies that acupuncture (applied as the main mode of treatment in our patient) has anti-inflammatory and analgesic effects [17,18]. Remote acupuncture point needling and near acupuncture point needling are also effective in controlling the pain of ankle injuries [19]. In our patient, electroacupuncture was added to stimulation of acupuncture points to strengthen the pain control mechanism.

For therapeutic purposes of analgesia and muscle relaxation, modulated waves of 10 Hz and 100 Hz were applied. Blood circulation was improved with 10 Hz to induce muscle spasms and relax muscles. To suppress pain, 100 Hz was applied (based on the rationale in gate control theory).

It was difficult to find research on the management and treatment of Lisfranc joint injuries with Korean medical interventions. There are no studies comparing natural or other

treatments with Korean medical treatment. There are very few cases of midfoot fractures being treated with Korean medicine. In recent years, there have been studies on treatments of foot fractures and prognosis in the Korean medical community. However, much of the research and discussion have been conducted in medical fields including the academic world to investigate whether or not Korean medical treatments are necessary after fractures.

In addition to progress on national clinical guidelines, studies by Woo et al [20], Oh et al [21], and Kim and Lee [22] are under way to secure ground for the Korean medical treatment of ankle sprain and ankle ligament injuries.

At present, we do not know if or how Korean medical treatment of foot joint injuries after fracture can contribute to improvement in pain and function. Future research should aim to determine if acupuncture is effective in improving pain and function in relevant patients.

Though our observations came from one patient who underwent short-term treatment, nevertheless, this is the first report on the use of acupuncture and taping therapy to reduce pain after Lisfranc joint injury and aid ambulation. More cases are needed to investigate the effects of acupuncture treatment and taping therapy on Lisfranc joint injuries.

Conflicts of Interest

The authors have no conflicts of interest to declare.

References

- [1] Peicha G, Labovitz J, Seibert FJ, Grechenig W, Weiglein A, Preidler KW, et al. The anatomy of the joint as a risk factor for Lisfranc dislocation and fracture-dislocation. An anatomical and radiological case control study. *J Bone Joint Surg Br* 2002;84:981–985.
- [2] Park HW, Yi HS. Analysis of clinical outcome and prognosis for Lisfranc joint fracture and dislocation according to the injury mechanism and treatment method. *J Korean Foot Ankle Soc* 2014;18:124–128. [In Korean]
- [3] Goossens M, De Stoop N. Lisfranc's fracture-dislocations: etiology, radiology, and results of treatment. A review of 20 cases. *Clin Orthop Relat Res* 1983;176:154–162.
- [4] Thordarson DB, Hurvitz G. PLA screw fixation of Lisfranc injuries. *Foot Ankle Int* 2002;23:1003–1007.
- [5] Nunley JA, Vertullo CJ. Classification, investigation, and management of midfoot sprains: Lisfranc injuries in the athlete. *Am J Sports Med* 2002;30:871–878.
- [6] Kitaoka HB, Alexander IJ, Adelaar RS, Nunley JA, Myerson MS, Sander M. Clinical rating systems for the ankle-hindfoot, midfoot, hallux, and lesser toes. *Foot Ankle Int* 1994;15:349–353.
- [7] Park YH, Kim HJ, Kim SH. Fractures of the tarsal bone. *J Korean Fract Soc* 2016;29:276–282. [In Korean]
- [8] Richter M, Wippermann B, Krettek C, Schrott HE, Hufner T, Therman H. Fractures and fracture dislocations of the midfoot: occurrence, causes and long-term results. *Foot Ankle Int* 2001;22:392–398.
- [9] Ghate SD, Sistla VM, Nemade V, Vibhute D, Shahane SM, Samant AD. Screw and wire fixation for Lisfranc fracture dislocations. *J Orthop Surg (Hong Kong)* 2012;20:170–175.
- [10] Benirschke SK, Meinberg E, Anderson SA, Jones CB, Cole PA. Fractures and dislocations of the midfoot: Lisfranc and Chopart injuries. *J Bone Joint Surg Am* 2012;94:1325–1337.
- [11] Myerson M. The diagnosis and treatment of injuries to the Lisfranc joint complex. *Orthop Clin North Am* 1989;20:655–664.
- [12] Ly TV, Coetzee JC. Treatment of primarily ligamentous Lisfranc joint injuries: primary arthrodesis compared with open reduction and internal fixation. A prospective, randomized study. *J Bone Joint Surg Am* 2006;88:514–520.
- [13] Yim HS, Hong SH, Sung KS. Lisfranc joint injuries: diagnosis and treatment. *J Korean Fract Soc* 2016;29:283–293. [In Korean]
- [14] Sheibani-Rad S, Coetzee JC, Giveans MR, DiGiovanni C. Arthrodesis versus ORIF for Lisfranc fractures. *Orthopedics* 2012;35:e868–873.
- [15] Mohamed MA, Radwan NL, Azab ASR. Effect of Kinesio-taping on ankle joint stability. *Int J Med Res Health Sci* 2016;5:51–58.
- [16] Hwang JH, Kim CH, Kim JK. Effects of ankle taping on range of motion, postural stability, and placebo effect before and after exercise. *Korean J Sport Sci* 2011;20:793–803. [In Korean]
- [17] Kim JY, Koh HG, Nam SS. The recent study on pain modulation of acupuncture. *The Acupuncture* 2006;23:145–154. [In Korean]
- [18] Kavoussi B, Ross BE. The neuroimmune basis of anti-inflammatory acupuncture. *Integr Cancer Ther* 2007;6:251–257.
- [19] Kim DJ, Choi YJ, Kim DH, Um JY, Song GH, Lee JS, et al. The comparison of effectiveness between near acupuncture point needling and remote acupuncture point needling on treating ankle sprain of acute stage. *The Acupuncture* 2007;24:25–33. [In Korean]
- [20] Woo CH, Kwon OG, An HD. The comparative study on the effect of acupuncture treatment with or without indirect moxibustion treatment for acute ankle sprain. *J Oriental Rehab Med* 2010;20:141–152. [In Korean]
- [21] Oh SJ, Kim JS, Lee YG, Lim SC, Lee HJ. Effects of pharmacopuncture and Danggwisu-powder for lateral malleolus avulsion fracture: a case report. *The Acupuncture* 2015;32:203–210. [In Korean]
- [22] Kim JS, Lee YK. One case of ankle fracture treated with SAAM (舍岩)-acupuncture and Gamhungguitang Ga-Nokyong after short leg casting. *The Acupuncture* 2007;24:207–213. [In Korean]