

쌍생아에서 선천 거대세포바이러스 감염 증례

김이슬 · 강지만 · 이지훈 · 장윤실 · 박원순 · 김예진

성균관대학교 의과대학 삼성서울병원 소아청소년과

Discordant Congenital Cytomegalovirus Infection in Twins

Yi-Seul Kim, Ji-Man Kang, Ji-Hoon Lee, Yoon Sil Chang, Won Soon Park, Yae-Jean Kim

Department of Pediatrics, Samsung Medical Center, Sungkyunkwan University School of Medicine, Seoul, the Republic of Korea

Cytomegalovirus (CMV) infection is one of the most common congenital infections. The first case of discordant congenital CMV infection in twins occurred in Korea. A 31-year-old woman became pregnant with twins (dichorionic-diamniotic). An elective caesarean section was performed at 37 weeks. The first baby was male, weighing 2,410 g with an Apgar score of 8/9. The second baby was female, weighing 1,380 g with an Apgar score of 5/8. She had experienced intrauterine growth retardation, and presented with microcephaly, micrognathia, and joint stiffness. During the work-up for discordant twins, the second baby's serum test was positive for CMV immunoglobulin M. Her urine, blood, and cerebrospinal fluid (CSF) were CMV polymerase chain reaction positive. The first baby's CMV tests were negative. Ophthalmologic exam and audiometry performed on the second baby showed CMV retinitis and bilateral sensorineural hearing loss. She was treated with intravenous ganciclovir. Currently, she is bed-ridden and has significant developmental delay. Although the causes of discordant congenital CMV infection in twins are unclear, this case shows that discordant congenital CMV infection should be considered in twins with significant differences in intrauterine growth or clinical symptoms after birth.

Key Words: Congenital; Infection; Cytomegalovirus; Twins

Introduction

Cytomegalovirus (CMV) infection is one of the most common causes of congenital viral infection. Most neonates with congenital CMV infection are asymptomatic and approximately 10% of infected neonates are

symptomatic¹⁾. Symptomatic congenital CMV infection refers to neonates with symptoms at birth such as growth retardation, petechiae, jaundice, hepatomegaly, microcephaly, hypotonia, poor sucking, lethargy, intellectual disability, vision impairment, seizure or sensorineural hearing loss, ect. Among them, central nervous system impairments are the majority symptoms.

There are three routes of CMV transmission from mother to fetus or newborn. Transmission through placenta (congenital CMV infection) is most common, can involve all systems, and cause harmful sequelae. Maternal viremia causes placental infection and initiated fetal viremia. Therefore, placental histopathology is one of the best methods to confirm congenital CMV infection. The other two routes are ascending infection from the

Received: 15 September 2016

Revised: 13 October 2016

Accepted: 13 October 2016

Correspondence: Yae-Jean Kim

Department of Pediatrics, Samsung Medical Center, Sungkyunkwan University School of Medicine, Seoul, the Republic of Korea

Tel: +82-2-3410-3539, Fax: +82-2-3410-0043

E-mail: yaejeankim@skku.edu

maternal genital tract and ingestion or aspiration of secretions during delivery or via breastfeeding (acquired CMV infection) and rarely cause harmful sequelae.

The factors responsible for transmission to the fetus and severity of congenital CMV infection are not understood well. The fetus can be affected by CMV during all trimesters of pregnancy. Some studies suggested that gestational age at maternal CMV infection has no significant influence on the rate of transmission, increased risk of CMV transmission during late gestation²⁾, and maternal infection during early gestation resulting in severe damage of infected fetuses^{3,4)}. In addition, other factors such as genetic factors, maternal factors, placental barriers, and viral load could have effects on congenital CMV infection.

Congenital CMV infection in twins is rare and interesting because both of them have the same maternal influence. There was no case report of congenital CMV infection in twins in Korea. Furthermore, we experienced a case of discordant congenital CMV infection in dichorionic twins; one baby was affected with severe symptomatic congenital CMV infection while the other baby was completely normal.

Case

A 31-year-old previously healthy primiparous woman became pregnant with twins (dichorionic-diamniotic [DCDA]). She had no history of having episodes of fever, myalgia, or unusual fatigue during her pregnancy. A 34-week-prenatal ultrasound showed discordant twins and the female fetus was smaller and had bilateral ventriculomegaly. At 37 weeks, the mother had an elective caesarean section. Both fetuses were in a vertical position. The first newborn was male, weighed 2,410 g (range, 10% to 25%) with an Apgar score 8/9 at 1 and 5 minutes, respectively after birth, and received routine nursery care. The second newborn was female, weighed 1,380 g (less than 10%) with an Apgar score of 5/8. Her initial crying was weak and heart rate was under 100 times per minute; she was admitted to the neonatal intensive care unit. Her height was 41 cm

(less than 10%) and head circumference was 26 cm (less than 10%). Her body gauges showed symmetric intrauterine growth retardation (IUGR). In addition, microcephaly, micrognathia, and all joint rigidity were observed on initial physical examination.

During the work-up for IUGR and discordant twins, the second baby's serum test (performed at birth) revealed that the CMV-specific immunoglobulin M (IgM) was positive with negative CMV-specific IgG and she had CMV viremia (maximal blood CMV DNA was 1,500 copies/mL and maximal CMV antigenemia was 15/200,000 white blood cells, both performed 50 days after birth). Her cerebrospinal fluid CMV polymerase chain reaction (PCR), performed 3 days (after birth) was also positive at 2,000 copies/mL. The initial urine CMV PCR, performed 2 days (after birth) was positive (35,859,000 copies/mL) as well. Urine CMV PCRs were repeated until 6 months of age and the results were shown Fig. 1.

The counter baby's urine CMV PCR and serum CMV-specific IgM were negative. Maternal serum CMV-specific IgG (81 AU/mL) was positive and IgM was negative. Her vaginal CMV culture was negative, both placentas were fused, and there were no abnormal findings in either placenta biopsies. Neither CMV PCR nor culture of placenta were done.

Affected baby's brain ultrasonography exam showed ventriculomegaly, increased periventricular white matter echogenicity and multifocal parenchymal lesions with tissue loss at the age of 2 days (Fig. 2A, B). At the age of 4 months, her brain magnetic resonance imaging showed cortical malformation and extensive white matter volume loss with circumventricular calcification and cerebellar hypoplasia (Fig. 2C, D). She had a ventriculoperitoneal shunt operation at the age of 7 months due to progressed hydrocephalus.

An ophthalmologic examination at 3 days of age showed CMV retinitis and she received intravenous ganciclovir treatment for 6 weeks. After discontinuation of ganciclovir, CMV retinitis recurred and she received additional ganciclovir for 3 weeks and was then changed to oral valganciclovir for 7 weeks. Audiometry tests at 1 month of age showed sensorineural hearing loss in

both ears for which she received left cochlear implant at the age of 7 months. She had her first unprovoked seizure at 1 month and her electroencephalogram showed spiked waves on both frontal and left tem-

poro-occipital area. She has been treated with antiepileptic drugs since then. She had cricopharyngeal incoordination and received fundoplication operation at the age of 1 year. Currently, she is 4 years old, bed-

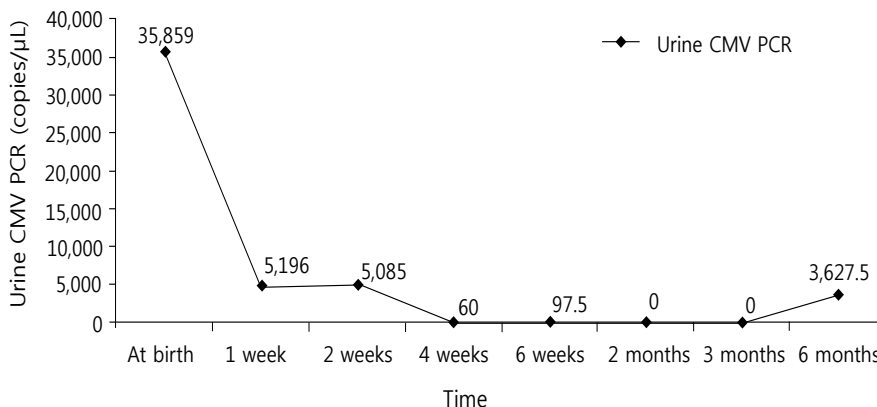


Fig. 1. The results of urine cytomegalovirus (CMV) polymerase chain reaction (PCR).

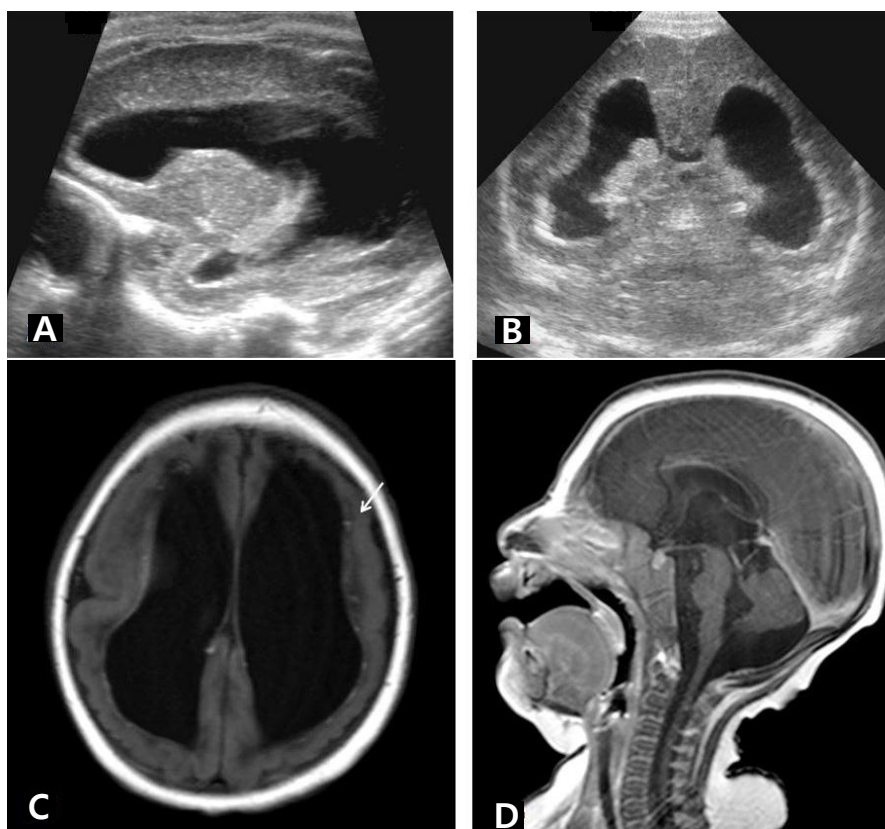


Fig. 2. (A, B) Brain ultrasonography performed 2 days after birth shows ventriculomegaly with increased periventricular echogenicity. (C, D) Brain magnetic resonance imaging at postnatal age 4 months shows cortical malformation and extensive white matter volume loss with circumventricular calcifications (arrow) and cerebellar hypoplasia.

ridden and has significant developmental delay.

Discussion

We report a case of discordant congenital CMV infection in DCDA twins from the same pregnancy. Mother did not have any other symptoms and prenatal diagnosis of CMV infection was not confirmed. Her CMV serology tests were reported as IgG positive and IgM negative after the delivery. However, since there was no data for CMV serostatus before pregnancy or before delivery of twins, it was not clear whether she had primary CMV infection or recurrent CMV infection. Although both babies had the same maternal factors and were exposed to the virus at the same time, they showed completely different courses.

It is commonly thought that clinical manifestations

of congenital CMV infection depend on chorionicity. Therefore, monochorionic twins were mostly reported to have the same outcomes while dichorionic twins have distinct outcomes⁵⁾. Egana-Ugrinovic et al.⁶⁾ reported congenital CMV infection among twin pairs according to chorionicity and clinical outcomes from 2006 to 2011. Among six twin pregnancies with congenital CMV infection, five were dichorionic and one was monochorionic. While only one of each dichorionic twin pair was infected in all the dichorionic pregnancies; both babies were infected in a monochorionic pregnancy. However, exceptional cases were also reported in other studies.

Table 1 shows several reported cases of diverse clinical outcomes of congenital CMV infection in twin pregnancies^{1,3,4,6-15)}. Among the 26 cases, 20 cases were dichorionic, five cases were monochorionic, and one case was triplet (two dichorionic, one monochorionic).

Table 1. Case Reports of Congenital CMV Infection in Twin Pregnancies

Study	Case	Chorionicity	Type of maternal infection	Congenital CMV infection	Clinical outcome
Seguin et al. (1988) ¹¹⁾	1	MC	Unknown	Uninfected/infected	Asymptomatic/symptomatic
Nigro et al. (1999) ¹³⁾	1	DC	Primary	Infected/infected	Asymptomatic/asymptomatic
Azam et al. (2001) ¹⁴⁾	1	DC	Unknown	Infected/uninfected	Symptomatic/asymptomatic
Lazzarotto et al. (2003) ³⁾	3	DC 2DC/1MC DC	Primary	Infected/uninfected Infected/infected/infected Infected/infected	Symptomatic (fetal death)/asymptomatic Symptomatic/symptomatic/symptomatic Asymptomatic/symptomatic
Kawana et al. (2004) ⁷⁾	1	DC	Primary	Infected/infected	Symptomatic (severe)/symptomatic
Yinon et al. (2006) ⁹⁾	6	DC	Primary Recurrent	Uninfected/infected Infected/infected Infected/infected Infected/infected Infected/infected Infected/infected	Asymptomatic/symptomatic (TOP) Asymptomatic/asymptomatic Asymptomatic/asymptomatic Asymptomatic/symptomatic (death) Symptomatic (IUFD)/symptomatic (IUFD) TOP*/TOP*
Manoura et al. (2006) ¹⁵⁾	1	DC	Recurrent	Infected/uninfected	Symptomatic/asymptomatic
Griesmaier et al. (2010) ¹⁰⁾	1	MC	Primary	Infected/infected	Symptomatic/symptomatic
Wu et al. (2011) ¹⁾	1	MC	Unknown	Infected/infected	Asymptomatic/symptomatic (fetal death)
Simioni et al. (2013) ⁴⁾	1	DC	Primary	Infected/uninfected	Asymptomatic/asymptomatic
Nakajima et al. (2015) ¹²⁾	1	MC	Unknown	Infected/infected	Symptomatic (severe)/symptomatic
Samedi et al. (2016) ⁸⁾	1	DC	Primary	Infected/infected	Symptomatic/asymptomatic
Egana-Ugrinovic et al. (2016) ⁶⁾	6	MC DC	Unknown	Infected/infected Uninfected/infected Uninfected/infected Uninfected/infected Uninfected/infected Uninfected/infected	Symptomatic/symptomatic Asymptomatic/symptomatic TOP/asymptomatic TOP (due to NTD)/asymptomatic IUFD/asymptomatic Asymptomatic/asymptomatic
Present study	1	DC	Unknown	Infected/uninfected	Symptomatic/asymptomatic

*Amniotic fluid results were positive and TOP was performed due to parents' request.

Abbreviations: CMV, cytomegalovirus; MC, monochorionic; DC, dichorionic; TOP, termination of pregnancy; IUFD, intrauterine fetal death; NTD, neural tube defect.

Among the 20 dichorionic twins, 11 pairs (55%) were infected/uninfected and nine pairs (45%) were both infected. Among five monochorionic twins, four pairs were both infected and only one pair was infected/uninfected. Kawana et al.⁷⁾ showed congenital CMV infection in DCDA twins and both babies were infected and symptomatic. However, they had different severity; first baby had more severe sequelae than second baby. They found that higher frequency of CMV-positive cells in the placenta was related to severe outcomes and placenta would play an important role in vertical transmission as the protective factor by producing interferon. Samedì et al.⁸⁾ reported the similar case. One of the twins had confirmed symptomatic congenital CMV infection and that baby's placental biopsy revealed CMV inclusion. However, the other baby had confirmed asymptomatic congenital CMV infection diagnosed by urine CMV culture and blood CMV PCR. Yinon et al.⁹⁾ studied the effect of placenta types (fused or separated) on congenital CMV infection in twins. Although presence of fused placentas might increase the risk of infection of both twins, there were some cases of discordant infection in fused placentas. Therefore they concluded that the placenta type cannot predict the pattern of infection in twins. In our case, both placentas were fused and biopsy results normal. However, there were different clinical outcomes between both babies. Lazzarotto et al.³⁾ reported discordant congenital CMV infection twins and they suggested that high viral load in the amniotic fluid was related to severe clinical outcomes. In our case, maternal amniotic fluid test was not examined and we don't know whether viral loads were different between both amniotic fluid or not. In some cases of congenital CMV infection in monozygotic twins, babies have equal manifestations^{5,6,10)} as expected because they have the same genetic identity, exposure to the same viral strain and are influenced by the same maternal factors. However, there are three cases of discordant congenital CMV infection in monozygotic twins. Seguin and Cho¹¹⁾ reported the case of only one monozygotic twin affected by CMV infection. First baby was uninfected, asymptomatic and second baby was infected, had

IUGR and severe sequelae. They could not provide the apparent reason for involvement of only one twin in the report. Wu et al.¹⁾ reported a similar case. First baby was infected but asymptomatic and had normal growth and the other fetus was infected, had IUGR and died in the uterus. They suggested that the combination of growth retardation and intrauterine viral infection impaired fetal immune response and different fetal immune status might be lead to different clinical courses. Although our case was dichorionicity, the infected fetus had IUGR. Nakajima et al.¹²⁾ reported congenital CMV infection in monozygotic twins with twin-to-twin transfusion syndrome. Although both babies were infected by CMV, donor baby had more severe manifestations than recipient. Because both babies had the same genetic factors and gestational age at infection, intrauterine hemodynamics was considered to be an important factor for the discordant manifestation.

The causes of discordant congenital CMV infection in twins are unclear. There will be multiple factors including genetic factors, maternal factors, fetal immune response, placental barriers and type, viral load and virulence but also other unknown factors will play a role for the different clinical outcomes. Our study shows that discordant congenital CMV infection should be considered in twins with significant difference of intrauterine growth or clinical symptoms after birth.

References

1. Wu HY, Huang SC, Huang HC, Hsu TY, Lan KC. Cytomegalovirus infection and fetal death in one monozygotic twin. *Taiwan J Obstet Gynecol* 2011;50:230-2.
2. Bodeus M, Hubinont C, Goubau P. Increased risk of cytomegalovirus transmission in utero during late gestation. *Obstet Gynecol* 1999;93(5 Pt 1):658-60.
3. Lazzarotto T, Gabrielli L, Foschini MP, Lanari M, Guerra B, Eusebi V, et al. Congenital cytomegalovirus infection in twin pregnancies: viral load in the amniotic fluid and pregnancy outcome. *Pediatrics* 2003;112:e153-7.
4. Simioni C, Sanchez Oliveira Rde C, Moscovi T, D' Agostini

- Deutsch A, Cordioli E, Santos E. Twin pregnancy and congenital cytomegalovirus: case report and review. *J Matern Fetal Neonatal Med* 2013;26:622-4.
5. Ahlfors K, Ivarsson SA, Nilsson H. On the unpredictable development of congenital cytomegalovirus infection. A study in twins. *Early Hum Dev* 1988;18:125-35.
 6. Egana-Ugrinovic G, Gonce A, Garcia L, Marcos MA, Lopez M, Nadal A, et al. Congenital cytomegalovirus infection among twin pairs. *J Matern Fetal Neonatal Med* 2016;29:3 439-44.
 7. Kawana K, Nakayama M, Yasugi T, Ishiwata M, Marumo G, Sakai M, et al. Differential clinical manifestations of congenital cytomegalovirus infection between dizygotic twins: a case report. *Am J Perinatol* 2004;21:383-6.
 8. Samedi VM, Skappak C, Jantzie L, Trevenen C, Kamaluddeen M, Ekwalinga P, et al. Comparison of presentation, course, and outcome of congenital and acquired cytomegalovirus infection in twins. *AJP Rep* 2016;6:e1-5.
 9. Yinon Y, Yagel S, Tepperberg-Dikawa M, Feldman B, Schiff E, Lipitz S. Prenatal diagnosis and outcome of congenital cytomegalovirus infection in twin pregnancies. *BJOG* 2006; 113:295-300.
 10. Griesmaier E, Neubauer V, Blum S, Trawoger R, Keller M, Kiechl-Kohlendorfer U. Neurodevelopmental outcome following congenital cytomegalovirus infection in preterm infants with twin-to-twin transfusion syndrome: a case report. *Klin Padiatr* 2010;222:312-4.
 11. Seguin J, Cho CT. Congenital cytomegalovirus infection in one monozygotic twin. *JAMA* 1988;260:3277.
 12. Nakajima J, Sunohara D, Kawashima H. Congenital cytomegalovirus infection in monozygotic twins with twin-to-twin transfusion syndrome. *Indian Pediatr* 2015;52:429-31.
 13. Nigro G, La Torre R, Anceschi MM, Mazzocco M, Cosmi EV. Hyperimmunoglobulin therapy for a twin fetus with cytomegalovirus infection and growth restriction. *Am J Obstet Gynecol* 1999;180:1222-6.
 14. Azam AZ, Vial Y, Fawer CL, Zufferey J, Hohlfeld P. Prenatal diagnosis of congenital cytomegalovirus infection. *Obstet Gynecol* 2001;97:443-8.
 15. Manoura A, Hatzidaki E, Korakaki E, Margari KM, Galanakis E, Giannakopoulou C. Symptomatic congenital cytomegalovirus infection in one twin after recurrent maternal infection. *Pediatr Int* 2006;48:88-90.

요약

거대세포바이러스 감염은 선천감염의 가장 흔한 원인 중의 하나이다. 본 증례는 쌍생아에서 다른 임상 양상을 보인 선천 거대세포바이러스 감염 증례에 대한 국내 첫 보고이다. 31세 초산부가 쌍생아(2 용모막, 2 양막)를 임신하였다. 임신 34주 산전 초음파에서 한쪽 태아의 크기가 작고 양측 뇌실 확장증이 발견되었으며 임신 37주경에 제왕절개로 분만하였다. 첫 번째 신생아는 남자로서 출생 체중 2,410 g, 아프가 점수 8/9점으로 출생하였으며 두 번째 신생아는 여자로서 출생 체중 1,380 g, 아프가점수 5/8점으로 출생하였다. 두 번째 신생아는 자궁 내 성장지연, 소두증, 소하악증, 사지 관절의 강직을 보였다. 불일치 쌍생아에 대한 원인을 찾기 위한 검사를 진행하였으며 두 번째 신생아의 혈액검사서 거대세포바이러스 immunoglobulin M이 양성반응을 보였으며 소변과, 혈액, 뇌척수액에서 거대세포바이러스 중합효소연쇄반응이 양성소견을 보였다. 반면에 정상으로 출생한 남아의 거대세포바이러스에 대한 검사는 모두 음성이었다. 감염된 환자의 안과적 검진에서 거대세포바이러스 망막염이 관찰되었고, 후에 실시한 청력검사에서 양측의 감음 난청이 확인되었다. 환자는 ganciclovir 치료를 받았으며 현재 여아는 심한 발달지연이 있으며 침대에서 누워서 생활하는 중이다. 이와 같이 쌍생아에서의 선천 거대세포바이러스 감염증이 한 명에게만 발생하는 경우의 원인은 현재까지 명확하지 않다. 하지만 이 증례를 통하여 심한 불일치 쌍생아의 경우에 선천 거대세포바이러스 감염의 가능성을 고려해 보아야 한다.