

Randomized Controlled Trials of Miniscalpel Acupuncture for Lumbar Spinal Stenosis Cited in the China National Knowledge Infrastructure Database

Sang Hoon Yoon^{1,2}, Yoon Sik Kim², Min Goo Kwon^{1,2} and Chan Young Kwon^{3,4,*}

¹Gwangju Chung–Yeon Korean Medicine Center

²Chung–Yeon Medical Institute

³Yanggu Public Health Center

⁴Department of Clinical Korean Medicine, Graduate School, Kyung Hee University



Key words :

Acupuncture;
Korean Medicine;
Lumbar Spinal Stenosis;
Miniscalpel Acupuncture

[Abstract]

Objectives : This study analyzed the current status of randomized controlled trials (RCTs) of miniscalpel acupuncture for lumbar spinal stenosis (LSS) in China.

Methods : A literature search was performed using the China National Knowledge Infrastructure (CNKI) database. All studies up to June 7th, 2017 were searched. The quality of included RCTs was assessed with the Jadad scale.

Results : Five RCTs were finally included in this review. The overall quality of the RCTs was assessed as low. All articles evaluated miniscalpel acupuncture as monotherapy or in combination with filiform needle therapy, drug injection therapy, Tuina treatment, thermal coagulation therapy, or spinal decompression. Miniscalpel acupuncture as monotherapy or adjunctive therapy showed greater therapeutic effect and fewer adverse effects.

Conclusion : Miniscalpel acupuncture is a safe and effective nonpharmacological treatment for LSS. However, high-quality studies with consistent treatment protocols are needed to confirm these findings.

Received : 2017. 06. 28.
Revised : 2017. 07. 18.
Accepted : 2017. 07. 26.
On-line : 2017. 08. 20.

* Corresponding author : Bangsan Branch Center of Yanggu Public Health Center, 37, Janggeorigil, Jangpyeong-ri, Bangsan-myeon, Yanggu-gun, Gangwon-do, Republic of Korea
Tel : +82-33-480-2637 E-mail : beanalogue@naver.com

I. Introduction

Lumbar spinal stenosis (LSS) is a common disease-causing pain in the lumbar spine and lower extremities. Various clinical symptoms and impaired walking are caused by nerve compression due to spinal canal stenosis¹. An epidemiologic study of 1,009 Japanese showed a prevalence rate of 9.3%². Stenosis is the most common reason for lumbar surgery for those aged over 65 years in the USA³.

LSS is classified as congenital or acquired. Although the majority of cases are caused by degenerative changes, factors such as spondylolisthesis, spondylolysis, trauma, and iatrogenic diseases are also contributors⁴.

The treatment of LSS is divided into nonsurgical and surgical treatment. Drug therapy, physiotherapy, and injection therapy are available nonsurgical treatments, while minimally invasive lumbar decompression (MILD), spinal decompression, fusion, and interspinous process implantation are available surgical procedures⁵. According to a review published in 2016, most nonsurgical treatments lack evidence for efficacy, while spinal decompression shows a low to moderate success rate⁶.

Miniscalpel acupuncture is a unique treatment with origins in the ancient stiletto needle (鉞鍼)⁷. It involves an acupuncture needle with a sharp knife at the tip, combining the effects of both acupuncture and microsurgery⁸, and may improve motor function by dissecting adherent tissues⁹, promoting local blood circulation¹⁰, and resolving nerve entrapment¹¹.

Based on these characteristics, a case study on 437 LSS patients treated with miniscalpel acupuncture, acupuncture, physical therapy, and drug treatment¹², and a case study on 3 LSS patients treated with miniscalpel acupuncture and standard methods¹³ were conducted in Korea. Both reported significant improvement and efficacy. However, no additional study has been conducted

in China to evaluate the efficacy of miniscalpel acupuncture for LSS. The purpose of this study was to analyze the current status of randomized controlled trials (RCTs) of miniscalpel acupuncture for LSS.

II. Methods

1. Study Identification and Selection

The China National Knowledge Infrastructure (CNKI) database was searched for RCTs. The search terms were ‘针刀’, ‘刀针’, ‘铍针’, ‘椎管狭窄症’ (the cross-language search option was selected), and all items up to June 7th, 2017 were screened. RCTs involving miniscalpel acupuncture for patients with LSS were selected. Two reviewers independently identified potential studies and disagreements were resolved with mediation by a third reviewer.

2. Quality Assessment

The quality of an RCT was assessed with the Jadad scale¹⁴. The following 5 points were considered.

- 1) Is the study randomized?
- 2) Is the study double-blind?
- 3) Are the reasons for patient withdrawal and dropout identified for each treatment group?
- 4) Was the method of randomization reported and adequate?
- 5) Was the double-blind method reported and adequate?

We awarded a score of 1 or 0 for items 1) to 3), according to enforcement and reporting; a score of 1 or -1 was awarded for items 4) and 5), according to the appropriateness of randomization and double-blinding. If not reported, a score of 0 was awarded.

Two reviewers independently performed the evaluation, and disagreements were resolved with mediation by third reviewer.

III. Results

1. Research and Outcomes

A total of 29 potentially relevant papers were identified, of which 1 was a duplicate. After reviewing the title and abstracts of 28 papers, we excluded 21 as irrelevant to the subject and conducted further evaluation. One review and 1 observational study were further excluded, leaving a total of 5 RCTs¹⁵⁻¹⁹ meeting our inclusion criteria (Fig. 1).

2. Basic Characteristics of Included Studies

Of the 5 studies, 2 were published in 2014^{16,17}, while the others were published in 2010¹⁵, 2015¹⁸, and 2016¹⁹, respectively. Two^{17,18} were dissertations, 4¹⁵⁻¹⁸ were 2-arm parallel studies and 1¹⁹ was a 4-arm parallel-group study, 2^{16,17} compared the effect of filiform needle therapy with miniscalpel acupuncture, 1¹⁵ compared the effect of drug injection therapy with miniscalpel acupuncture, 1¹⁸ compared miniscalpel acupuncture combined with Tuina treatment with miniscalpel acupuncture

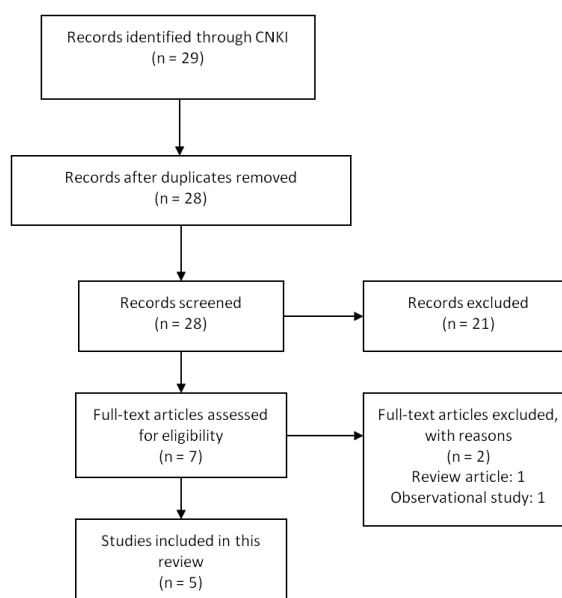


Fig. 1. PRISMA flow chart of this review

alone, and 1¹⁹ compared monotherapy with either miniscalpel acupuncture or thermal coagulation therapy. The subject characteristics, interventions, evaluation indexes, and research results are summarized in Table 1.

3. Evaluation of Study Quality

The overall quality of studies was low; of the 5, 3¹⁷⁻¹⁹ scored 2 points, 1¹⁵ scored 1 point, and 1¹⁶ scored 0 points on the Jadad scale (Table 2). None reported approval from an institutional review board (IRB), but 4 studies¹⁶⁻¹⁹ reported consent from participants.

Table 2. Jadad scores of included studies

Author(year)	Jadad score					IRB	Consent form
	1	2	3	4	5		
Liu (2010)	1	0	0	0	0	-	-
Ma (2014)	1	0	0	-1	0	-	+
Zhang (2014)	1	0	0	1	0	-	+
Xiong (2015)	1	0	0	1	0	-	+
Zhong (2016)	1	0	0	1	0	-	+

Table 1. Characteristics of included studies

Author (year)	Sample size (included—analyzed)	Mean age	Population	Mean disease period	Treatment intervention	Control intervention	Outcome	Results (*, p<0.05 **, p<0.01 ≡, p>0.05)	Adverse effects
Liu (2010)	60(30:30) —60(30:30)	TG:40.5±12.5 CG:39.7±13.6	LSS	TG:10.9±5.6 CG:11.6±5.4 (year)	MA (once/wk, 2 wks)	Sacral canal injection (once/wk, 2 wks)	1. Reduction of pain in low back and leg 2. Clinical efficacy	1. totally disappeared: TG>CG*, improved: TG<CG*, ineffective: TG<CG* 2. effective rate: TG>CG*, total effective rate: TG>CG*	NR
Ma (2014)	60(30:30) —60(30:30)	TG:44.32±7.03 CG:43.59±6.67	LSS	TG:7.3±2.2 CG:7.3±2.1 (month)	MA (3 times/wk, 2 wks)	Acupuncture (7 times/wk, 2 wks)	1.ODI	1. Both groups showed significant improvement after treatment (p<0.05, respectively), while TG was significantly superior to CG (p<0.05).	NR
Zhang (2014)	60(30:30) —60(30:30)	TG:54.50±8.80 CG:56.43±8.70	LSS	TG:10.00±4.41 CG:9.30±4.15 (month)	MA (1 time/wk, 2 wks)	Acupuncture (7 times/wk, 2 wks)	1.VAS 2.JOA 3.Clinical efficacy	1. TG showed significant improvement after treatment (p<0.01), but not in TG (p>0.05). TG was significantly superior to CG (p<0.05). 2. Both groups showed significant improvement after treatment (p<0.01, respectively), while TG was significantly superior to CG (p<0.01). 3. total effective rate: TG>CG*	There was no significant side effect.

Xiong (2015)	60(30:30) -60(30:30)	TG:64.63±8.801 CG:66.93±6.082	LSS	TG: 11 cases CG: 8 cases (>2 years) TG: 19 cases CG: 22 cases (<2 years)	MA (1 time/wk, 3 wks) Tuina (1 time/2 days, 3 wks)	MA (1 time/wk, 2 wks)	1.VAS 2.JOA 3.Clinical efficacy(JOA)	1. TG was significantly superior to CG at 1 wk and 2 wks after treatment initiation (p<0.05, respectively), while there was no significant difference between TG and CG at 3 wks (p>0.05). 2. TG was significantly superior to CG at 1 wk and 2 wks after treatment initiation (p<0.05 and p<0.01, respectively), while there was no significant difference between TG and CG at 3 wks (p>0.05). 3. effective rate: TG≐CG	NR
Zhong (2016)	48(12:12:12:12) -48(12:12:12:12)	74.0±9.1	LSS	NR	GR2: MA GR3: PTRT+MA (1 time)	GR1: PTRT GR2: LWD	1. Procedure time, amount of bleeding, average length of stay 2.VAS 3.Clinical efficacy(JOA)	1. GR1, GR2, and GR3 had significantly less operative time, amount of bleeding, and average length of stay than GR4 (p<0.05, respectively). 2. GR1 and GR2 were significantly superior to GR3 and GR4 at 1 month, 6 months, and 12 months after treatment (p<0.05, respectively). 3. total effective rate: GR1≐GR2≐GR3≐GR4	NR

Abbreviations: CG, control group; GR, group; JOA, Japanese Orthopaedic Association score; LSS, lumbar spinal stenosis; LWD, lamina windowing decompression; MA, miniscalpel acupuncture; NR, not recorded; OD, Oswestry Disability Index; PTRT, percutaneous target radiofrequency thermocoagulation; TG, treatment group; VAS, visual analogue scale.

4. Efficacy and Safety of Miniscalpel Acupuncture for LSS

1) Miniscalpel Acupuncture vs. Drug Injection Therapy

Liu et al. (2010)¹⁵⁾ conducted a 2-week study on 60 patients with LSS; 30 patients were treated once a week with miniscalpel acupuncture, and 30 were treated once a week with lidocaine 5 ml, normal saline 10 ml + dexamethasone 10 mg, and normal saline 10 ml + triamcinolone acetonide 40 mg + methylcobalamin 400 μ g injected into the sacral canal. Treatment efficacy was based on the degree of symptom improvement and pain reduction in the back and lower extremities. The results showed a significantly higher rate of complete pain relief in the miniscalpel acupuncture group, while the drug injection treatment group had a higher rate of those who showed only some improvement or no effect. The overall efficacy rate was significantly higher in the group treated with miniscalpel acupuncture. The prevalence of adverse effects was not reported.

2) Miniscalpel Acupuncture vs. Filiform Needle Therapy

Ma et al. (2014)¹⁶⁾ conducted a 2-week study on 60 patients with LSS; 30 patients were treated 3 times a week with miniscalpel acupuncture and 30 in the control group were treated 7 times a week with filiform needle therapy. Treatment efficacy was evaluated with the Oswestry Disability Index (ODI). Both groups had significant improvement in ODI scores, with the miniscalpel acupuncture group showing greater improvement than the control group. The prevalence of adverse effects was not reported.

Zhang (2014)¹⁷⁾ conducted a 2-week study on 60 patients with LSS; 30 patients were treated once a week with miniscalpel acupuncture and 30 in the control group were treated 7 times a week with filiform needle therapy. Treatment efficacy was evaluated with the Visual Analogue Scale (VAS) and the Japanese Orthopaedic Association score (JOA),

and effectiveness was evaluated according to the degree of symptom improvement. Both groups showed improved VAS and JOA scores, with the miniscalpel acupuncture group showing greater improvement than the filiform needle therapy group. The overall efficacy rate was significantly higher in the miniscalpel acupuncture group. No adverse effects were reported with interventions

3) Miniscalpel Acupuncture with Tuina Treatment vs. Miniscalpel Acupuncture

Xiong (2015)¹⁸⁾ conducted a 3-week study on 60 patients with LSS; 30 patients were treated with miniscalpel acupuncture and Tuina treatment once a week or on alternate days; 30 patients in the control group were treated with miniscalpel acupuncture alone once a week. VAS and JOA scores were evaluated and the efficacy was assessed according to JOA improvement. The group receiving combined treatment showed greater improvement in both VAS and JOA scores in the first 2 weeks than the group receiving miniscalpel acupuncture treatment alone. However, there was no significant difference in the VAS and JOA scores or the efficacy rate between the 2 groups by week 3. The prevalence of adverse effects was not reported.

4) Miniscalpel Acupuncture with Thermal Coagulation Therapy vs. Miniscalpel Acupuncture vs. Thermal Coagulation Therapy vs. Spine Decompression Treatment

Zhong et al. (2016)¹⁹⁾ conducted a study on 48 patients with LSS, with 12 patients in each of 4 groups: a percutaneous high-frequency thermal coagulation therapy group, a miniscalpel acupuncture treatment group, a thermal coagulation therapy with miniscalpel acupuncture treatment group, and a spinal decompression treatment group. Procedure times, amount of blood loss, mean hospital length of stay, and VAS and JOA scores were assessed for 12 months and the efficacy rate was assessed according to JOA score improvement. The procedure time, amount of blood loss, and mean

hospital length of stay were significantly reduced in all miniscalpel acupuncture, thermal coagulation therapy, and combined therapy groups. VAS was significantly reduced in the miniscalpel acupuncture and thermal coagulation therapy group, compared to the combined therapy or spinal decompression group. There was no significant difference in the efficacy rate. The prevalence of adverse effects was not reported.

5. Miniscalpel Acupuncture Treatment of Lumbar Spinal Stenosis

Table 3 summarizes miniscalpel acupuncture according to the treatment period, equipment type, anesthesia, region of insertion, angle of insertion, blade orientation, depth of insertion, stimulation point, stimulation method, and adjunctive imaging techniques.

IV. Discussion

LSS presents with various clinical symptoms resulting from narrowing of the spinal canal and disturbance of blood circulation in the nerves caused by intervertebral disc herniation, hypertrophy of the ligamentum flavum, and the facet joints¹⁾. Incision of the hypertrophic ligamentum flavum and facet joints is required to decompress and resolve symptoms. Hence, current guidelines promote open or endoscopic surgical procedures²⁰⁾. As tissue is incised with a blunt tip, miniscalpel acupuncture has the effects of both filiform needle therapy and microsurgery.

In order to investigate the current status of RCTs that evaluated miniscalpel acupuncture for LSS, we searched CNKI and obtained a total of 5 studies¹⁵⁻¹⁹⁾. Although patient consent was documented in 4¹⁶⁻¹⁹⁾ of the 5 studies, none mentioned IRB approval and the overall quality was low bases

on the Jadad scale. Thus, IRB approval should be reinforced.

The outcomes of included studies indicated that miniscalpel acupuncture was more effective for LSS than filiform needle therapy and drug injection therapy. One study¹⁵⁾ compared miniscalpel acupuncture with drug injection therapy and showed significantly greater efficacy at 2 weeks. Despite showing apparent symptom improvement with both methods, 2 studies^{16,17)} comparing filiform needle therapy and miniscalpel acupuncture supported miniscalpel acupuncture as superior.

In addition, although therapeutic effect was quickly obtained with Tuina treatment combined with miniscalpel acupuncture, a similar level of therapeutic effect was obtained with miniscalpel acupuncture alone on the final outcome assessment. One study¹⁸⁾ compared the effect of miniscalpel acupuncture alone or in combination with Tuina treatment, and showed no difference by week 3, despite significantly better outcomes in weeks 1 and 2.

The results of a study comparing miniscalpel acupuncture, thermal coagulation therapy, and spinal decompression treatment suggested that miniscalpel acupuncture was not only more effective, but also safer than spinal decompression treatment. The study¹⁹⁾ showed significant reduction in procedure time, amount of blood loss, and mean hospital length of stay with miniscalpel acupuncture or thermal coagulation therapy alone or in combination, compared to spinal decompression treatment alone. Moreover, the therapeutic effect was greater than with spinal decompression.

One study¹⁷⁾ reported the prevalence of adverse effects among participants. No adverse effects were significant, thereby confirming that miniscalpel acupuncture is an effective and safe non-pharmacological therapy for LSS.

After analyzing the efficacy and safety, we evaluated the techniques of miniscalpel acupuncture used in each study (Table 3). Liu et al. (2010)¹⁵⁾ approached the interlaminar space 1 cun (寸) lateral to the spinous process and decompressed the canal

Table 3. Technique of miniscalpel acupuncture used in the included studies

Author (year)	Treatment factor	Contents
Liu (2010)	period	1 time per week, 2 weeks total
	type	–
	anesthesia	used
	region of insertion	1 cm lateral to the spinous process
	angle of insertion	straight
	blade orientation	–
	depth of insertion	to the stimulation point (contact with nerve root, patient complains of lower limb numbness – slightly withdraw needle at this point)
	stimulation point	1. nerve root 2. interlaminar space
	stimulation method	–for upper and lower longitudinal cutting and left and right horizontal stripping, if tension is increased, shake miniscalpel up and down
	adjunctive imaging technique	–
Ma (2014)	period	3 times per week, 2 weeks total
	type	0.4 mm × 40 mm
	anesthesia	–
	region of insertion	1. interspinous point and both upper and lower interspinous points 2. transport point*: acupoint used in bladder acupuncture – 1st line parallel to both sides of the spinous process
	angle of insertion	1. interspinous: straight insertion 2. transport point: straight insertion
	blade orientation	1. interspinous: sagittal 2. transport point: sagittal
	depth of insertion	1. interspinous: 2–3 cm 2. transport point: 3–4 cm
	stimulation point	1. interspinous: interspinous ligament 2. transport point: erector spinae muscle
	stimulation method	1. interspinous: cut with a lifting–thrusting method 2 to 3 times, and then cut twice to each side 2. transport point: cut with a lifting–thrusting method 2 to 3 times with oblique cut, lateral stab 2 to 3 times, then turn miniscalpel 90°, cut 2 to 3 times
	adjunctive imaging technique	–
Zhang (2014)	period	1 time per week, 2 weeks total
	type	0.8 mm × 210 mm
	anesthesia	–
	region of insertion	Huatuo Jiaji (EX B2) Point†
	angle of insertion	straight insertion
	blade orientation	–
	depth of insertion	To the stimulation point
	stimulation point	ligamentum flavum

Xiong (2015)	stimulation method	–to incise only the ligamentum flavum without damaging the dural sac and nerve roots, make a large incision and perform decompression without cutting completely
	adjunctive imaging technique	c–arm, endoscopy
	period	3 times per week, 2 weeks total
	type	–
	anesthesia	used
	region of insertion	1. transverse process 2. facet joint 3. other sensitive points
	angle of insertion	–
	blade orientation	sagittal
	depth of insertion	to the stimulation point
	stimulation point	1. bone surface of transverse process 2. from medial margin of facet joint to superior edge of lamina
Zhong (2016)	stimulation method	–upper and lower longitudinal cutting and left and right horizontal stripping.
	adjunctive imaging technique	–
	period	1 time
	type	No. 3 Hanzhangzhendao* (NR × 80 mm)
	anesthesia	used
	region of insertion	1. interspinous point 2. both sides of spinous process 3. intersection of facet joint lateral margin and transverse process upper margin 4. erector spinae muscle
	angle of insertion	–
	blade orientation	–
	depth of insertion	to the stimulation point
	stimulation point	1. interspinous ligament 2. ligamentum flavum 3. dorsal ramus of spinal nerve 4. erector spinae muscle
stimulation method	1. ligamentum flavum: when needle tip contacts top of lamina, upper and lower longitudinal cutting and left and right horizontal stripping (to 0.5–cm depth) 2. intersection of facet joint lateral margin and transverse process upper margin: cut with lifting–thrusting method to avoid nerve damage	
adjunctive imaging technique	c–arm	

*transport point: 背俞穴, † Huatuo Jiaji (EX B2) Point : 夹脊穴, ‡ Hanzhangzhendao : 汉章针刀

by incising the ligamentum flavum. The authors used a blind technique, based on anatomical landmarks and response to contact with the nerve roots. They gradually approached the ligamentum flavum until numbness and paresthesias were perceived in the lower extremities, indicating contact. Incision after slight withdrawal allowed decompression under blind conditions. However, an unskilled approach can lead to critical damage of the dura mater and nerve roots.

Ma et al. (2014)¹⁶ used the safest method and the most treatment sessions, by stimulating only the muscles and ligaments through short insertions, with 3 treatment sessions per week. Whether the intervention directly targeted deep spinal canal stenosis is unclear, but we believe the treatment emphasized stabilization of the vertebral body by loosening regional muscles and ligaments. Zhang (2014)¹⁷ also used miniscalpel acupuncture for decompression of the ligamentum flavum. However, Zhang assured safety by approaching the interlaminar space while observing the dura mater and nerve roots via c-arm imaging and endoscopy during incision of the ligamentum flavum.

Xiong (2015)¹⁸ treated the transverse process, ligamentum flavum, and other tender points for decompression. Xiong also approached the interlaminar space by contacting the medial border of the facet joint. As a blind procedure, this technique also requires a highly-skilled surgeon.

Zhong et al. (2016)¹⁹ treated the ligamentum flavum, interspinous ligament, posterior nerves, and erector spinae muscles with miniscalpel acupuncture. Incision of the ligamentum flavum was made under c-arm guidance, while preventing possible injury to the dura mater and nerve roots by limiting the insertion depth to 0.5 cm. Further incisions were also made from the lateral margin of the facet joint to the superior border of the transverse process, possibly targeting the dorsal ramus of the spinal nerve, a major contributor to lumbar pain.

With the exception of Ma et al. (2014)¹⁶, 4^{15,17-19} of 5 researchers approached the interlaminar space

and incised the ligamentum flavum. Zhang (2014)¹⁷ and Zhong et al. (2016)¹⁹ used c-arm guidance while Liu (2010)¹⁵ and Xiong (2015)¹⁸ used blind procedures.

This study has the following limitations. Research was limited to studies conducted in China, there was heterogeneity between the treatments used, and the methodological quality was low. However, the study is significant for summarizing the current status of RCTs of miniscalpel acupuncture for LSS in China, as well as providing guidelines for future research by analyzing methodology, clinical efficacy, safety, and results according to clinical implications.

In this review, we found that miniscalpel acupuncture is a safe and effective nonpharmacological treatment for LSS. However, high-quality studies with consistent treatment protocols are needed to confirm these findings.

V. Reference

1. Katz JN, Harris MB. Clinical practice. Lumbar spinal stenosis. *N Engl J Med*. 2008;358(8):818-25.
2. Ishimoto Y, Yoshimura N, Muraki S et al. Prevalence of symptomatic lumbar spinal stenosis and its association with physical performance in a population-based cohort in Japan: the Wakayama Spine Study. *Osteoarthritis Cartilage*. 2012;20(10):1103-8.
3. Deyo RA, Gray DT, Kreuter W, Mirza S, Martin BI. United States trends in lumbar fusion surgery for degenerative conditions. *Spine (Phila Pa 1976)*. 2005;30(12):1441-5; discussion 1446-7.
4. Arnoldi CC, Brodsky AE, Cauchoix J et al. Lumbar spinal stenosis and nerve root entrapment syndromes. Definition and classification. *Clin Orthop Relat Res*. 1976;(115):4-5.
5. Lurie J, Tomkins-Lane C. Management of

- lumbar spinal stenosis. *BMJ*. 2016;352:h6234.
6. Inoue G, Miyagi M, Takaso M. Surgical and nonsurgical treatments for lumbar spinal stenosis. *Eur J Orthop Surg Traumatol*. 2016; 26(7):695–704.
 7. Son YH, Yoon SH, Yuk DI, Sung IS, Kim MJ, Hong KE. Research Literature for Periodical Consideration about Dochim. *The Acupunct*. 2013;30(4):175–80.
 8. Ma C, Wu S, Li G, Xiao X, Mai M, Yan T. Comparison of miniscalpel–needle release, acupuncture needling, and stretching exercise to trigger point in myofascial pain syndrome. *Clin J Pain*. 2010;26(3):251–7.
 9. Zhu HZ, Quan WC, Zhang XF et al. Evaluation on clinical therapeutic effect of needle–knife therapy on cervical spondylosis. *Zhongguo Zhen Jiu*. 2006;26(5):316–8.
 10. Li S, Shen T, Liang Y, Zhang Y, Bai B. Effects of Miniscalpel–Needle Release on Chronic Neck Pain: A Retrospective Analysis with 12–Month Follow–Up. *PLoS One*. 2015;10(8): e0137033.
 11. Lim NR, Jang EH, Park MY, Kim SC. Case Study of Oriental Medicine Treatment with acupotomy Therapy of the Tarsal tunnel Syndrome. *J Pharmacopuncture*. 2009;12(1):109–17.
 12. Yuk DI. Clinical Study on 437 Patients with Lumbar Spine Stenosis Treated by Acupotomy combined with Oriental Medical Treatments [dissertation]. Daejeon: Daejeon University. 2013. Korean.
 13. Han YS, Jang WS, Jung KY et al. Study and three Cases Report for Lumbar Spinal Stenosis Treatment Using a Combination of Acupotomy and Existing Treatments. *Korean J Orient Physiol Pathol*. 2012;26(1):120–7.
 14. Jadad AR, Moore RA, Carroll D et al. Assessing the quality of reports of randomized clinical trials: is blinding necessary? *Control Clin Trials*. 1996;17(1):1–12.
 15. Liu HF, Liu XW. Clinical study of xiaozhendao for treatment of lumbar spinal stenosis. *Chin Med Herald*. 2010;7(6):58–9.
 16. Ma LZ, Sun HB, Chen PF, Feng WW. Clinical study of miniscalpel acupuncture on 30 cases of lumbar spinal stenosis. *J New Chin Med*. 2014;46(2):177–8.
 17. Zhang ZH. Clinical research on treating Yellow ligament hypertrophy Lumbar spinal stenosis by visual acupotomy mirror to release Jiaji points on waist [dissertation]. Shandong: Shandong University. 2014. Chinese.
 18. Xiong JW. Clinical study of miniscalpel acupuncture combined with Tuina on degenerative lumbar spinal stenosis [dissertation]. Beijing: Beijing University. 2015. Chinese.
 19. Zhong YX, Qiao JL, Ding Y et al. Therapeutic evaluation of percutaneous target radiofrequency thermocoagulation combined with needle knife techniques therapy in age–related lumbar spinal stenosis. *Pract Geriatr*. 2016;30(1):69–72.
 20. Overvest GM, Jacobs W, Vleggeert–Lankamp C, Thomé C, Gunzburg R, Peul W. Effectiveness of posterior decompression techniques compared with conventional laminectomy for lumbar stenosis. *Cochrane Database Syst Rev*. 2015;(3):CD010036.