

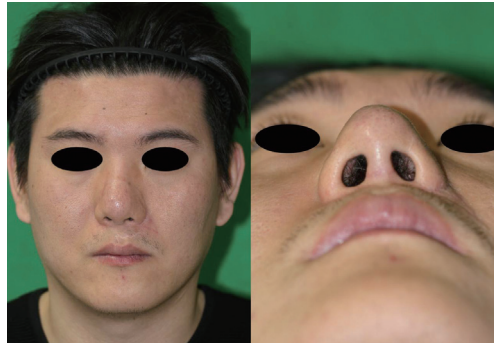

Fig. 4.

Postoperative view flap 5 months after surgery showing the formation of the reentrant area on the initially vague alar-facial groove and minimal scarring caused by the V-Y advancement.

reconstruct the alar-facial groove. This technique reduces tension and yields more prominent results by providing a force in the medial direction.

Patient Consent

The patient provided written informed consent for the publication and the use of their images.

References

1. Han D, Mangoba DS, Lee D, et al. Reconstruction of nasal alar defects in asian patients. *Arch Facial Plast Surg* 2012;14:312-7.
2. Ueda K, Shigemura Y, Hara M, et al. Skirt flap for nasal alar reconstruction. *Plast Reconstr Surg Glob Open* 2014;2:e157.
3. Park JL, Oh CH, Hwang K, et al. Correction of an alar web with a feather-edge rolled-in flap. *J Craniofac Surg* 2014;25:2192-5.

Received: 21 Feb 2017 • Revised: 11 Jun 2017 • Accepted: 22 Jun 2017
 pISSN: 2234-6163 • eISSN: 2234-6171
<https://doi.org/10.5999/aps.2017.44.5.470>
Arch Plast Surg 2017;44:470-471



Copyright © 2017 The Korean Society of Plastic and Reconstructive Surgeons
 This is an Open Access article distributed under the terms of the Creative Commons Attribution Non-Commercial License (<http://creativecommons.org/licenses/by-nc/4.0/>) which permits unrestricted non-commercial use, distribution, and reproduction in any medium, provided the original work is properly cited.

We hereby report a case of a 41-year-old woman with a history of liposuction of the right hip 6 months previously who presented to her dermatologist with bilateral recurring erythematous skin nodules. On palpation, 1 cm tender nodules were identified in the bilateral hip region in close approximation to the liposuction scars and a shave biopsy was performed from the lesions on the right side. The clinical differential diagnosis included panniculitis, tumid lupus erythematosus, and infection. A biopsy was performed and the histopathologic examination revealed an interstitial palisading granulomatous dermatitis with dermal mucin deposition confirmed by colloidal iron stain (Figs. 1–3). We examined multiple H&E sections, and there was no evidence of polarizable or non-polarizable foreign material. Special stains (Gomori Methenamine silver stain [GMS], Periodic acid-Schiff [PAS], and Acid-fast bacilli stain [AFB]) were negative for fungus and mycobacteria and culture studies performed also were negative.

In light of the patient's history of liposuction immediately adjacent to the area of the nodules, we concluded that granulomatous dermatitis was induced by the liposuction procedure. There was no known history of any injectable material used in our case. The

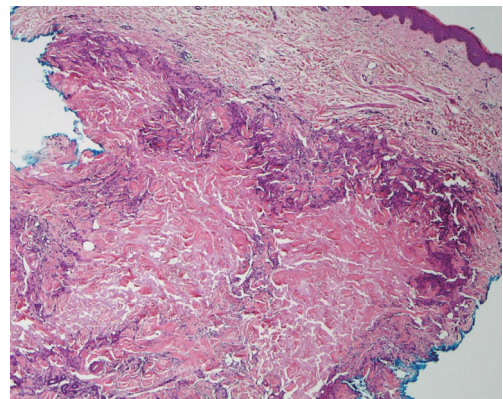


Fig. 1.

Interstitial granulomas (H&E, ×40). Section of skin showing dermal palisading granulomatous inflammation with central area of interstitial mucin deposition.

Interstitial Granulomatous Dermatitis with Granuloma Annulare-Like Pattern Following Liposuction

Indu Agarwal¹, Antoinette Thomas¹, Mohit Agarwal², Thomas Cibull¹

¹Department of Pathology, NorthShore University Health System, Evanston, IL; ²Department of Radiology, Medical College of Wisconsin, Wauwatosa, WI, USA

Correspondence: Indu Agarwal
 Department of Pathology, NorthShore University Health System, 2650 Ridge Avenue, Evanston, Illinois, USA 60201
 Tel: +1-8475702779, Fax: +1-8475700289
 E-mail: induinpath@yahoo.co.in

No potential conflict of interest relevant to this article was reported.

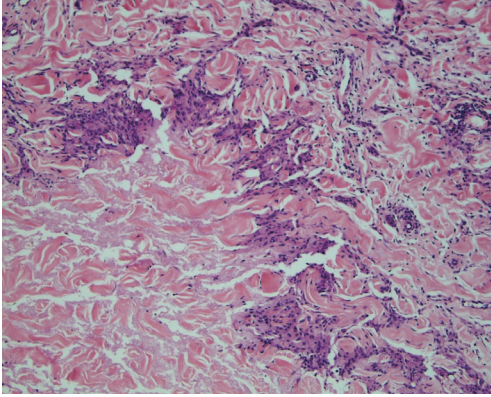


Fig. 2. Interstitial granuloma with mucin (H&E, × 100). Sections demonstrating presence of palisading granulomatous dermatitis surrounding interstitial mucin deposits.

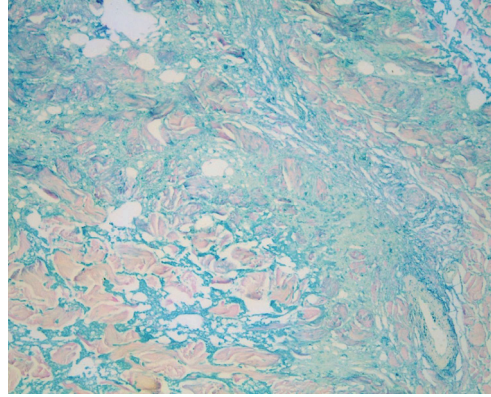


Fig. 3. Special stain highlighting mucin. (Colloidal iron stain, × 100). Colloidal iron stain highlights the mucin (blue) in the central part of dermal interstitial granulomas.

lesions have not recurred so far to the best of our knowledge.

Well-known adverse effects of liposuction include allergic contact dermatitis, seroma, post-inflammatory changes, and infection [1,2]. Rarely, a granuloma annulare-like reaction pattern secondary to foreign material has been reported after liposuction [3]. This is the first report to our knowledge of interstitial granulomatous dermatitis with a granuloma annulare-like pattern following liposuction, unassociated with any history of injected foreign material or foreign material by histologic examination.

References

1. Lehnhardt M, Homann HH, Daigeler A, et al. Major and lethal complications of liposuction: a review of 72 cases in Germany between 1998 and 2002. *Plast Reconstr Surg* 2008;121:396e-403e.
2. Zosso C, Lienhard R, Siegrist HH, et al. Post liposuction infections by rapidly growing mycobacteria. *Infect Dis (Lond)* 2015;47:69-72.
3. Shanesmith RP, Vogiatzis PI, Binder SW, et al. Unusual palisading and necrotizing granulomas associated with a lubricating agent used in lipoplasty. *Am J Dermatopathol* 2010;32:448-52.