

# Mitral Valve Replacement with a Pulmonary Autograft in an Infant

Yong Ho Jeong, M.D., Tae-Jin Yun, M.D.

*Division of Pediatric Cardiac Surgery, Asan Medical Center, University of Ulsan College of Medicine*

A 76-day-old infant weighing 3.4 kg was referred for surgical intervention for severe mitral valve stenosis caused by leaflet fibrosis and calcification. He had experienced a cerebral infarction in the left middle cerebral artery territory, which was deemed attributable to an embolism of a calcified particle from the dysmorphic mitral valve. Because mitral valve replacement using a prosthetic valve was not feasible in this small baby, mitral valve replacement with a pulmonary autograft was performed. After a brief period of extracorporeal membrane oxygenation (ECMO) support, he was weaned from ECMO and was discharged home without further cardiovascular complications.

*Key words:* 1. Pulmonary autograft  
2. Mitral valve replacement  
3. Ross II operation

## Case report

A male baby was born at 34 weeks and 4 days of gestational age with a birth weight of 1,840 g and transferred to the neonatal intensive care unit. He had been prenatally diagnosed with dysplasia and regurgitation of both the mitral and tricuspid valves. Immediate postnatal echocardiography showed severe mitral regurgitation with multiple calcified nodule, multiple atrial septal defects, and a huge patent ductus arteriosus. Cardiac computed tomography on postnatal day 8 also showed thickening and calcification of the mitral and tricuspid valves (Fig. 1). Follow-up echocardiography on postnatal day 30 revealed newly developing mitral stenosis with left atrial enlargement (chamber area, 9.95 cm<sup>2</sup>) and left ventricular hypertrophy and dysfunction. The maximal mitral inflow velocity was 2.1 m/sec, and the mean and peak pressure gradients across the mitral

valve were 10 mm Hg and 18 mm Hg, respectively (Fig. 2). The annulus diameters of the mitral valve and pulmonary valve were 15.1 mm and 9.7 mm, respectively. Brain ultrasound at 63 days showed newly-appeared diffuse high echogenicity in the left middle cerebral artery (MCA) territory, and brain magnetic resonance imaging confirmed a subacute to chronic infarction in the left MCA territory and an acute infarction at the left caudate head, anterior limb of the internal capsule, and the anterior putamen and globus pallidus region. As the risk of embolism of a calcified particle from the mitral valve was deemed too high and the patient's mitral stenosis was deteriorating, we elected to perform a surgical intervention for the mitral valve. On postnatal day 76 (body weight, 3.4 kg), the baby was brought into the operating theater. After cardiopulmonary bypass was instituted, a left atriotomy was made and mitral valvuloplasty was attempted,

*Received: August 25, 2017, Revised: September 30, 2017, Accepted: October 12, 2017, Published online: April 5, 2018*

*Corresponding author: Tae-Jin Yun, Division of Pediatric Cardiac Surgery, Asan Medical Center, University of Ulsan College of Medicine, 88 Olympic-ro 43-gil, Songpa-gu, Seoul 05505, Korea (Tel) 82-2-3010-3589 (Fax) 82-2-3010-6966 (E-mail) tjyun@amc.seoul.kr*

© The Korean Society for Thoracic and Cardiovascular Surgery. 2018. All right reserved.

© This is an open access article distributed under the terms of the Creative Commons Attribution Non-Commercial License (<http://creativecommons.org/licenses/by-nc/4.0>) which permits unrestricted non-commercial use, distribution, and reproduction in any medium, provided the original work is properly cited.

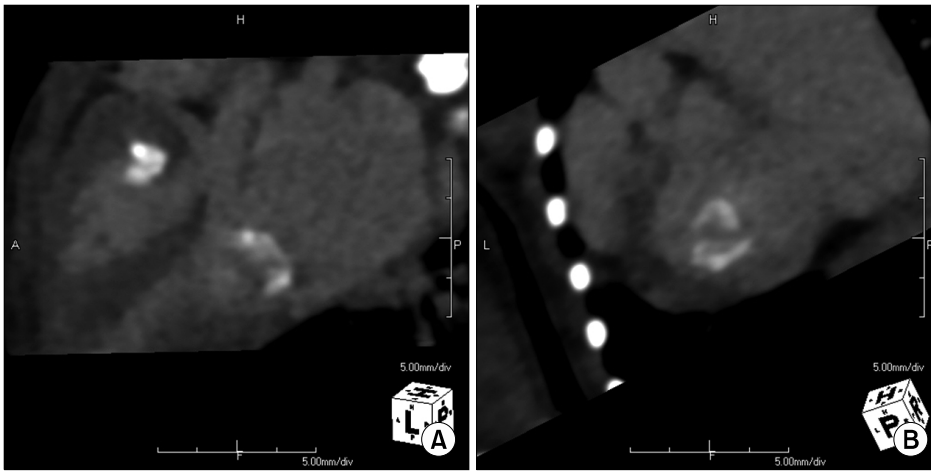


Fig. 1. (A, B) Cardiac computed tomography showing calcified mitral and tricuspid valves.

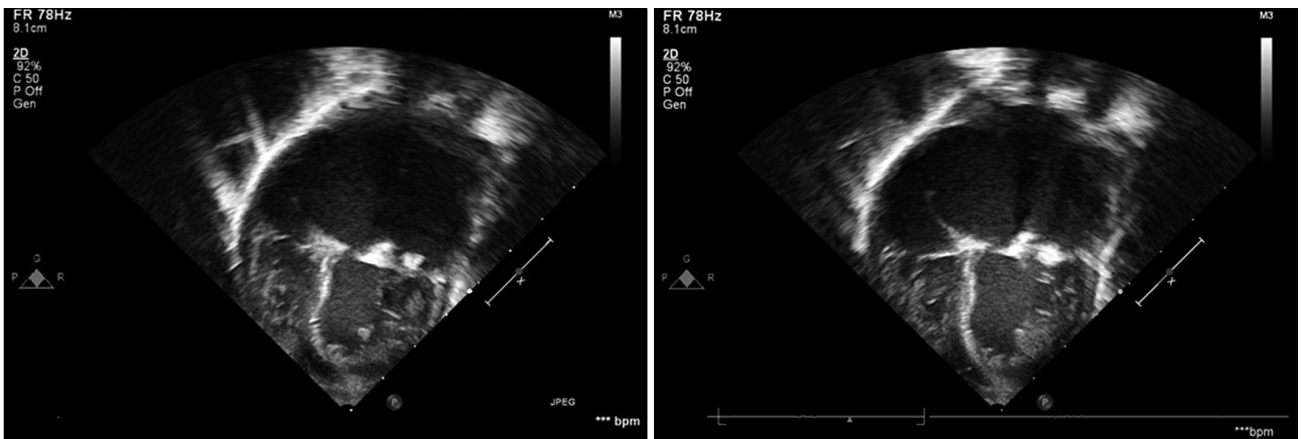
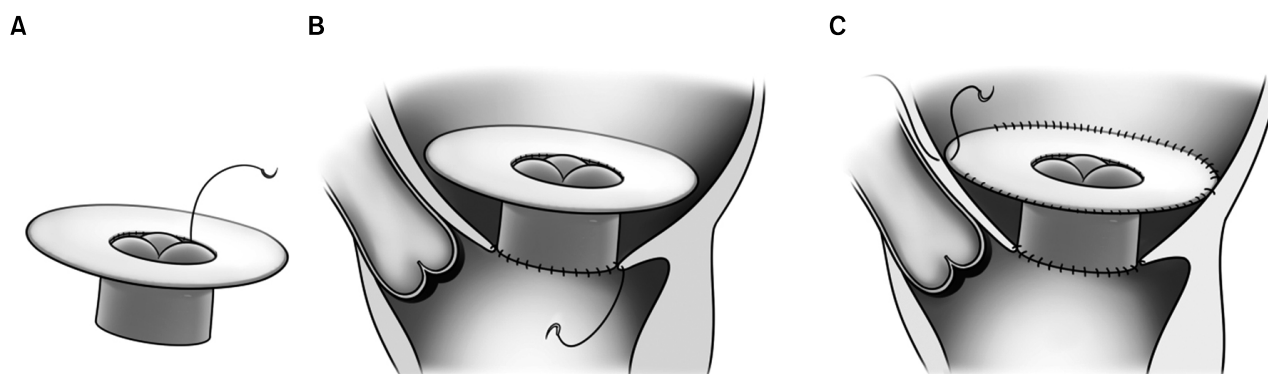


Fig. 2. Preoperative echocardiography showing mitral valve calcification and left atrial enlargement.

which consisted of the excision of calcified nodules from the mitral valve leaflets, anterior leaflet extension using autologous pericardium, and unilateral Reed annuloplasty of the posteromedial commissure. However, intraoperative transesophageal echocardiography after the patient was removed from cardiopulmonary bypass showed severe mitral regurgitation, and the baby was put back on bypass for a Ross II operation. After a pulmonary autograft was harvested, a 2-cm-wide autologous pericardial cuff was reconstructed at the base of the pulmonary valve using 7-0 polypropylene sutures with the 'top hat' modification (Fig. 3A). The left atriotomy was reopened and the mitral valve was re-exposed and excised. The pulmonary autograft was anchored at the mitral valve annulus level with a continuous suture technique using 6-0 polypropylene sutures, and

the pericardial cuff was attached to the left atrium at the supramitral level (Fig. 3B, C). Right ventricle to pulmonary artery continuity was reconstructed using a 12-mm Contegra conduit. Because of the hemodynamic instability after the completion of the Ross II procedure, we elected to put the patient on a left ventricular assist device in the operating room, which was converted to central extracorporeal membrane oxygenation (ECMO) in the intensive care unit. Two days after the operation, the patient was weaned from ECMO. Heparin was used for postoperative anticoagulation. The baby was extubated on postoperative day 11, and transferred to the general ward on postoperative day 18. Postoperative echocardiography performed on postoperative day 22 showed an autograft mitral valve annulus of 10.5 mm with mild stenosis, with a mean pressure gra-



**Fig. 3.** The 'top hat' modification of Ross II operation. The pulmonary homograft was harvested and the pericardial cuff was sewn onto the proximal end of the autograft (A). The homograft was sewn at the mitral valve annulus (B), and the pericardial cuff was sutured to the left atrial free wall (C).

dient of 5.5 mm Hg and mild central regurgitation. The baby was discharged home on postoperative day 33 without further complications. Warfarin was used for postoperative anticoagulation with a target international normalized ratio of 2.0.

### Discussion

Surgical options for infants with mitral valve stenosis or regurgitation are limited, given that an ideal prosthetic valve for very small babies is not available. Bioprosthetic valves are too large for infants and rapidly calcify and degenerate [1]. The smallest mechanical valves available in practice (15–16 mm in orifice diameter) are still too large for young infants weighing less than 4 kg. Even if we could implant a mechanical prosthetic valve in small babies by modifying the surgical technique (i.e., supra-annular implantation), the need for lifelong anticoagulation and the higher risk of postoperative morbidity and mortality would need to be taken into account [1]. Because prosthetic valve replacement is not a feasible option for children younger than 2 years, mitral valve replacement using the autologous pulmonary valve as an autograft was attempted by Ross and Kabbani in 1997 (hence, the name of the operation [Ross II]) [2]. In a recent study of 92 Ross II operations, the rates of freedom from degeneration, reoperation, and death at 5 years postoperatively were 93.4%, 94.2%, and 86.0%, respectively [3]. That study, however, did not include any patients who were younger than 4 years.

Information regarding the early and late outcomes of Ross II operations in young patients is sporadic [4–8]. The surgical technique employed for this baby was different from the technique suggested in other studies, in that the pulmonary autograft was not encased in a prosthetic graft prior to the implantation, considering the growth potential of the pulmonary autograft. Longer term follow-up is mandatory to ascertain the benefits of this technical modification.

In conclusion, mitral valve replacement using a pulmonary autograft may be a feasible surgical option for small babies, particularly when their cardiac chamber is too small to accommodate prosthetic valves.

### Conflict of interest

No potential conflict of interest relevant to this article was reported.

### References

1. Beierlein W, Becker V, Yates R, et al. *Long-term follow-up after mitral valve replacement in childhood: poor event-free survival in the young child.* Eur J Cardiothorac Surg 2007;31:860-5.
2. Ross DN, Kabbani S. *Mitral valve replacement with a pulmonary autograft: the mitral top hat.* J Heart Valve Dis 1997;6:542-5.
3. Kabbani S, Jamil H, Nabhani F, et al. *Analysis of 92 mitral pulmonary autograft replacement (Ross II) operations.* J Thorac Cardiovasc Surg 2007;134:902-8.
4. Kawahito T, Egawa Y, Yoshida H, et al. *Experience of mi-*

- tral valve replacement using a pulmonary autograft (Ross II operation) in an infant: report of a case.* Kyobu Geka 2015;68:523-7.
5. Kabbani SS, Sabbagh NA, Kudsi AY, Nabhani F, Jamil H. *Update on the mitral pulmonary autograft.* Asian Cardiovasc Thorac Ann 2011;19:253-9.
  6. Yamagishi M, Shuntoh K, Matsushita T, et al. *Mitral valve replacement by a Gore-Tex reinforced pulmonary autograft in a child.* J Thorac Cardiovasc Surg 2003;126:1218-9.
  7. Pace Napoleone C, Oppido G, Angeli E, Giardini A, Gargiulo G. *Ross-kabbani operation in an infant with mitral valve dysplasia.* Cardiol Res Pract 2009;2009:593659.
  8. Lee JW, Kim KI, Jung SH, Choi E, Song MG. *Mitral valve replacement with a pulmonic autograft.* Korean J Thorac Cardiovasc Surg 2001;34:361-4.