

Tips for Successful Septal Myectomy in Patients with Hypertrophic Cardiomyopathy

Jae Hyun Kim, M.D., Ph.D.

Department of Thoracic and Cardiovascular Surgery, Keimyung University Dongsan Medical Center

Septal myectomy is the gold-standard treatment of hypertrophic cardiomyopathy. However, it involves the risk of incomplete resection of septal muscles or iatrogenic septal perforation depending on the surgeon's practice. Herein, we suggest a few tips for successful septal myectomy and present a relevant case.

Key words: 1. Cardiomyopathy, hypertrophic
2. Hypertrophic obstructive cardiomyopathy
3. Surgery, technique

Introduction

Septal myectomy is the procedure of choice for treating hypertrophic cardiomyopathy (HCM). However, it involves the risk of incomplete resection of septal muscles or iatrogenic septal perforation depending on the surgeon's practice. Herein, we suggest a few tips for successful septal myectomy and present a relevant case.

Technique

A 50-year-old man presented with dyspnea on exertion (New York Heart Association functional class III) and was diagnosed with HCM, severe mitral regurgitation, moderate aortic regurgitation, moderate tricuspid regurgitation, persistent atrial fibrillation, and a large left atrium. The peak left ventricular outflow tract (LVOT) velocity was 3.16 m/sec and the peak pressure gradient was 40 mm Hg. Those parameters did not significantly change during the Valsalva maneuver. The left atrial anteroposterior di-

mension was 71 mm and the left atrial volume was 338 mL.

1) Tip 1: Measure the length and depth of the excess septal muscle on the heart computed tomogram and reconfirm these findings on trans-esophageal echocardiography

Preoperatively, chest computed tomography was conducted and reconstructed following the axis of the LVOT. The depth and length of the muscle targeted for resection were measured (Fig. 1A). Under general anesthesia, transesophageal echocardiography was performed and the measurements were reconfirmed.

After a median sternotomy, cardiopulmonary bypass was instituted using ascending aortic cannulation and bicaval venous cannulation. Aortic cross-clamp and cardioplegic cardiac asystole followed. A transverse aortotomy was made on the ascending aorta, and the aortic valve leaflets were retracted using 5-0 Prolene sutures for better exposure of the sub-aortic area. The thickened septum was verified

[†]This paper was presented in the 2017 International Heart Valve Disease Forum.

Received: September 13, 2017, Revised: October 20, 2017, Accepted: October 23, 2017, Published online: June 5, 2018

Corresponding author: Jae Hyun Kim, Department of Thoracic and Cardiovascular Surgery, Keimyung University Dongsan Medical Center, 56 Dalseong-ro, Jung-gu, Daegu 41931, Korea (Tel) 82-53-250-8387 (Fax) 82-53-250-7307 (E-mail) jaemax31@gmail.com

© The Korean Society for Thoracic and Cardiovascular Surgery. 2018. All right reserved.

© This is an open access article distributed under the terms of the Creative Commons Attribution Non-Commercial License (<http://creativecommons.org/licenses/by-nc/4.0>) which permits unrestricted non-commercial use, distribution, and reproduction in any medium, provided the original work is properly cited.

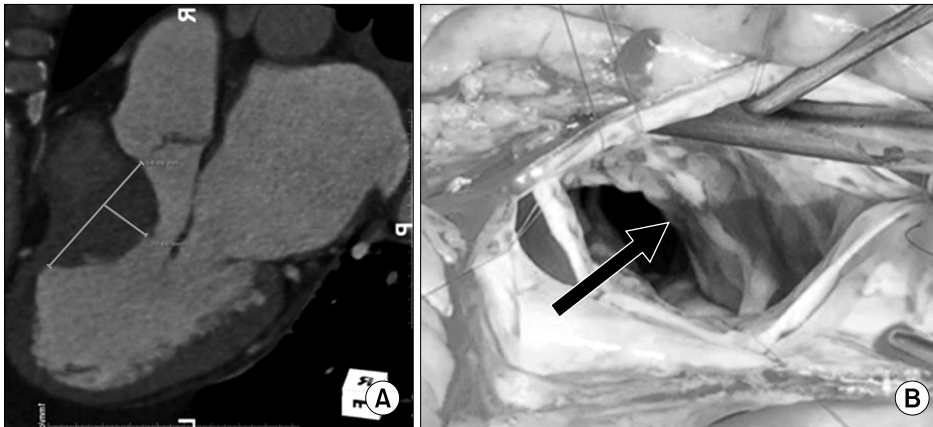


Fig. 1. (A) Measurement of the depth and length of the muscle targeted for resection on the heart computed tomogram. (B) Operative photo showing the hypertrophied septal muscle (arrow).

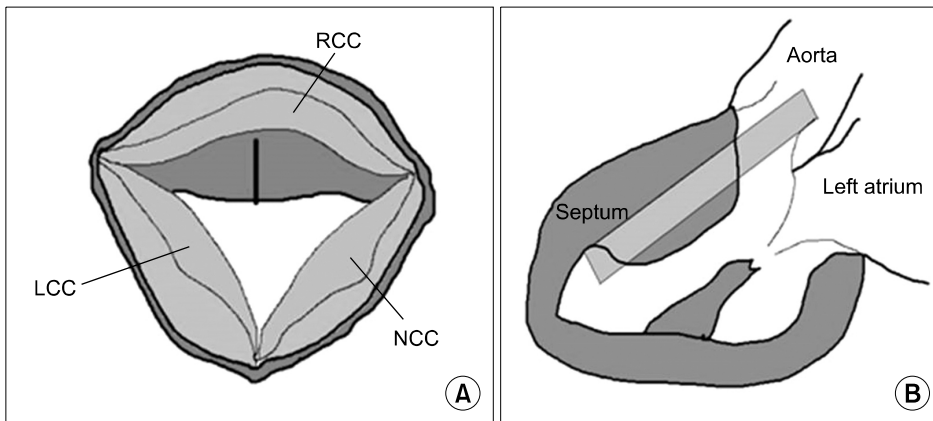


Fig. 2. Illustration showing how the muscle depth is cut along the longitudinal axis using a cutter knife to mark the reference plane for resection. (A) Axial view. (B) Longitudinal view. LCC, left coronary cusp; RCC, right coronary cusp; NCC, non-coronary cusp.

(Fig. 1B).

2) Tip 2: Using a long blade, mark the desired depth of muscle resection along the longitudinal axis

A frequent cause of incomplete muscle resection is losing the resection plane and axis during myectomy, usually starting from the sub-annular area. As a way to avoid losing the resection plane, marking the depth of muscle resection along the longitudinal axis is extremely helpful (Fig. 2). However, a long-bladed surgical instrument is seldom available unless it is custom-made. Therefore, we used a sterilized stationary cutter knife. After inserting the desired length of blade under the hypertrophied muscle, muscle cutting was performed to the desired depth, bearing in mind that the blade width was about 1 cm. Using the reference line of resection, septal myectomy was performed. A larger scalpel (#20) was also useful for myectomy. In extended myectomy, the resection

ranges from just to the right of the nadir of the right aortic sinus leftward to the mitral anterior leaflet. The upper end was located approximately 4 mm below the aortic ring [1].

3) Tip 3: Excise anomalous muscle bundles and abnormal subvalvular attachments

In a recent report, more than 80% of patients had various intraventricular anomalies [2]. Therefore, anomalous muscle bundles and abnormal subvalvular attachments must be verified and treated in order to obtain optimal results. In our case, aberrant muscle bundles were found and resected. A taut anterolateral papillary muscle restricting a mitral valve was partially resected, and papillary muscle splitting was also conducted. After the operation, the total weight of resected muscle was 12 g (Fig. 3A, B).

In this patient, we performed septal myectomy, mitral ring annuloplasty, aortic valve non-coronary cusp central plication and tricuspid ring annuloplasty, a

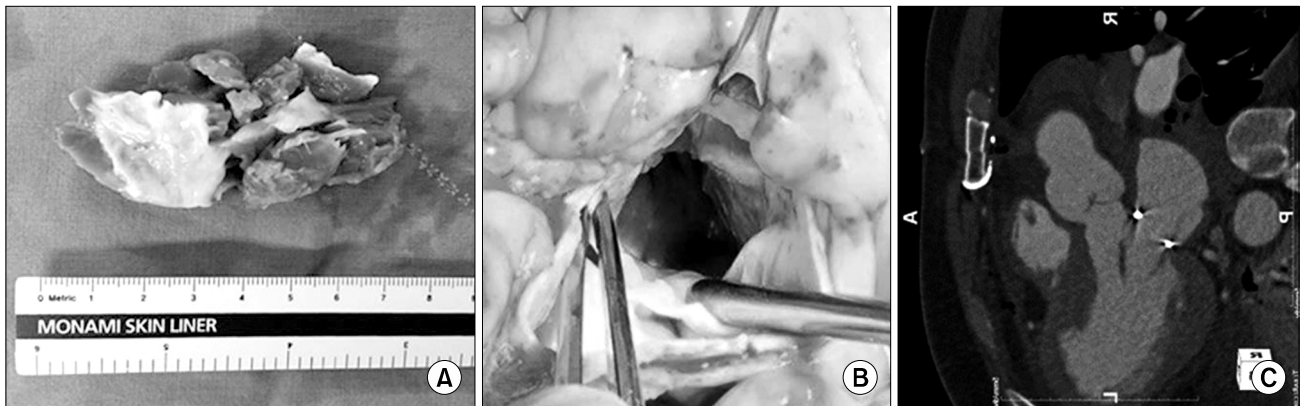


Fig. 3. (A) Operative photo showing the resected muscle (weight, 12 g). (B) Operative photo showing the relieved left ventricular outflow tract. (C) Postoperative heart computed tomogram showing the relieved left ventricular outflow tract.

maze operation, and left atrial circumferential resection. The aortic cross-clamp time and cardiopulmonary bypass time were 174 minutes and 206 minutes, respectively. After the operation, the patient was discharged on postoperative day 8 without any sequelae. A postoperative transthoracic echocardiogram confirmed no LVOT obstruction or residual valvular regurgitation. The peak LVOT velocity was 1.86 m/sec and the peak pressure gradient was 14 mm Hg. During the Valsalva maneuver, the peak LVOT velocity was 2.3 m/sec and the peak pressure gradient was 21 mm Hg. Chest computed tomography after the operation revealed a relieved LVOT (Fig. 3C).

Discussion

HCM is the most common genetic cardiac disorder; it is inherited as an autosomal dominant trait, with a prevalence of 0.2% (3). Clinical symptoms vary from an asymptomatic state to severe heart failure or sudden cardiac death.

Surgical septal myectomy is the gold standard for the treatment of patients with severe drug-refractory symptoms or LVOT obstruction [3]. Said and Schaff [1] described the details of extended septal myectomy with comprehensive illustrations. However, there is a definite learning curve with this procedure in order to avoid major technical complications, such as complete heart block, ventricular septal defect, injury to the aortic or mitral valves, and incomplete resection [1]. A frequent cause of incomplete muscle resection is losing the resection plane and axis dur-

ing myectomy. To avoid losing the resection plane, cutting the depth of the muscle to be resected along the longitudinal axis using a cutter knife is a helpful method. Using this as a reference line, extended septal myectomy can be easily performed.

In addition to septal myectomy, the recognition and treatment of various intraventricular anomalies are critical for the success of the procedure. According to Wang et al. [2], more than 80% of patients had various intraventricular anomalies, which were classified into 4 types: anomalous muscular bundles between the interventricular septum and ventricular apex, anomalous chordae to the interventricular septum, adhesion to the interventricular septum or ventricular free wall, and an accessory muscle to the leaflet.

Regarding mitral regurgitation, systolic anterior motion (SAM) of the anterior leaflet of the mitral valve is a unique pathophysiological feature of HCM, and SAM causes LVOT obstruction and mitral valve regurgitation. In most patients with HCM, mitral regurgitation related to SAM of the mitral valve is relieved through an adequate myectomy [4]. Concomitant mitral valve surgery is rarely necessary unless intrinsic mitral valve disease is present. In this case, mitral repair was inevitable due to a severely dilated annulus and redundant leaflets. When mitral valve procedures are required, repair is preferred to replacement.

Conflict of interest

No potential conflict of interest relevant to this ar-

ticle was reported.

References

1. Said SM, Schaff HV. *Surgical treatment of hypertrophic cardiomyopathy*. *Semin Thorac Cardiovasc Surg* 2013;25:300-9.
2. Wang S, Cui H, Yu Q, et al. *Excision of anomalous muscle bundles as an important addition to extended septal myectomy for treatment of left ventricular outflow tract obstruction*. *J Thorac Cardiovasc Surg* 2016;152:461-8.
3. Gersh BJ, Maron BJ, Bonow RO, et al. *2011 ACCF/AHA guideline for the diagnosis and treatment of hypertrophic cardiomyopathy: executive summary: a report of the American College of Cardiology Foundation/American Heart Association Task Force on Practice Guidelines*. *J Am Coll Cardiol* 2011;58:2703-38.
4. Hong JH, Schaff HV, Nishimura RA, et al. *Mitral regurgitation in patients with hypertrophic obstructive cardiomyopathy: implications for concomitant valve procedures*. *J Am Coll Cardiol* 2016;68:1497-504.