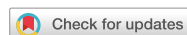

Research Article



Received: Jun 1, 2018
Accepted: Aug 22, 2018

Kim HS, Jung D, Lee H, Han YS, Oh S, Sim HY

*Correspondence to

Hee-Sun Kim, DDS, MSD, PhD

Associate Professor, Department of Dentistry,
Seoul Metropolitan Government-Seoul
National University Boramae Medical Center
(SMG-SNU BMC), 20 Boramae-ro 5-gil,
Dongjak-gu, Seoul 07061, Korea.
E-mail: hskamy@naver.com

Hye-Young Sim, DDS, MSD, PhD

Assistant Professor, Department of Dentistry,
Seoul Metropolitan Government-Seoul
National University Boramae Medical Center
(SMG-SNU BMC), 20 Boramae-ro 5-gil,
Dongjak-gu, Seoul 07061, Korea.
E-mail: othodo@hanmail.net

Copyright © 2018. The Korean Academy of
Conservative Dentistry

This is an Open Access article distributed
under the terms of the Creative Commons
Attribution Non-Commercial License (<https://creativecommons.org/licenses/by-nc/4.0/>)
which permits unrestricted non-commercial
use, distribution, and reproduction in any
medium, provided the original work is properly
cited.

Conflict of Interest

No potential conflict of interest relevant to this
article was reported.

Author Contributions

Conceptualization: Kim HS; Data Curation: Oh
S; Investigation: Kim HS; Methodology: Lee H,
Han YS, Jung D; Project administration: Kim

C-shaped root canals of mandibular second molars in a Korean population: a CBCT analysis

Hee-Sun Kim ,¹ Daun Jung ,¹ Ho Lee ,¹ Yoon-Sic Han ,¹ Sohee Oh ,²
Hye-Young Sim

¹Department of Dentistry, Seoul Metropolitan Government-Seoul National University Boramae Medical Center (SMG-SNU BMC), Seoul, Korea

²Department of Biostatistics, Seoul Metropolitan Government-Seoul National University Boramae Medical Center (SMG-SNU BMC), Seoul, Korea

ABSTRACT

Objectives: The purpose of this study was to investigate the C-shaped root canal anatomy of mandibular second molars in a Korean population.

Materials and Methods: A total of 542 teeth were evaluated using cone-beam computed tomography (CBCT). The canal shapes were classified according to a modified version of Melton's method at the level where the pulp chamber floor became discernible.

Results: Of the 542 mandibular second molars, 215 (39.8%) had C-shaped canals, 330 (53%) had 3 canals, 17 (3.3%) had 2 canals, 12 (2.2%) had 4 canals, and 8 (1.7%) had 1 canal. The prevalence of C-shaped canals was 47.8% in females and 28.4% in males. Seventy-seven percent of the C-shaped canals showed a bilateral appearance. The prevalence of C-shaped canals showed no difference according to age or tooth position. Most teeth with a C-shaped canal system presented Melton's type II (45.6%) and type III (32.1%) configurations.

Conclusions: There was a high prevalence of C-shaped canals in the mandibular second molars of the Korean population studied. CBCT is expected to be useful for endodontic diagnosis and treatment planning of mandibular second molars.

Keywords: C-shaped canal; Mandibular second molar; Korean; CBCT







INTRODUCTION

Variations in canal configuration can cause challenges in the debridement and obturation of canals [1,2]. One of these variations is the C-shaped canal, which is most commonly seen in mandibular second molars, although it can also be observed in maxillary and mandibular premolars and molars [3-7]. This variation causes considerable difficulties in visualization, instrument access, and identification of canal anatomy [2,8-11]. Preoperative recognition of such variations is an essential for the successful endodontic treatment of mandibular second molars [10,12].

Since the first report by Cooke and Cox in 1979 [1], many investigators have evaluated the root canal anatomy of mandibular second molars. The prevalence of C-shaped canals has been reported to vary depending on the population and ethnic group [1,4,7,10,12-30]. The mandibular second molars in Asian populations have shown a high prevalence of C-shaped canals in many studies [6,18,20,25,30].

HS, Sim HY; Supervision: Kim HS; Validation: Sim HY; Visualization: Lee H; Writing - original draft: Kim HS; Writing - review & editing: Sim HY, Jung D, Lee H, Han YS, Oh S.

ORCID iDs

Hee-Sun Kim 
<https://orcid.org/0000-0002-1445-6565>
Daun Jung 
<https://orcid.org/0000-0002-0278-5476>
Ho Lee 
<https://orcid.org/0000-0002-0413-2954>
Yoon-Sic Han 
<https://orcid.org/0000-0001-8060-5330>
Sohee Oh 
<https://orcid.org/0000-0002-3010-448X>
Hye-Young Sim 
<https://orcid.org/0000-0002-3338-4245>

Cone-beam computed tomography (CBCT) has recently been suggested as a useful method for investigating root canal anatomy. Its 3-dimensional images provide a more precise and thorough understanding of the root canal system than is possible using traditional 2-dimensional radiography [5,10,12,23]. Furthermore, due to its noninvasive nature, CBCT facilitates larger sample sizes in comparison to studies using microscopic analysis [10,23,30].

Therefore, the purpose of this study was to investigate the C-shaped root canal configurations of mandibular second molars in a Korean population using *in vivo* CBCT images.

MATERIALS AND METHODS

This study was approved by the Seoul Metropolitan Government-Seoul National University Boramae Medical Center (SMG-SNU BMC) Institutional Review Board (IRB No. 20161207/26-2016-160/122).

The subjects were Korean patients who underwent CBCT for diagnostic purposes at SMG-SNU BMC from January to December 2014. CBCT was mainly performed as part of planning for the surgical extraction of impacted teeth or implant surgery. A total of 540 mandibular second molars were selected according to the following criteria:

1. Mandibular second molars with bilateral fully developed roots.
2. No root canal fillings, posts or crown restorations, or periapical lesions.

The subjects were aged from 15 to 63 years, and their mean age was 27.7 years. There were 159 female subjects (318 teeth) and 111 male subjects (222 teeth).

The CBCT images were taken with a Dinnova system (Willmed, Gwangmyeong, Korea), with the following settings: 95 kVp, 9.0 mA, a 20 × 7-cm field of view, 0.2 mm³ voxel size, and 1.0 mm slice thickness. OnDemand 3D software (Cybermed, Seoul, Korea) was used to display the tomographic sections.

The number of root canals was counted at the level where the pulp chamber floor became discernible. The canal shapes were classified as subtypes of C-shaped canal systems according to the modified Melton's method proposed by Fan et al. (**Figure 1**) [2].

- Category I (C1): The shape was an uninterrupted “C” with no separation or division.
Category II (C2): The canal shape resembled a semicolon resulting from a discontinuation of the “C” outline, but either the α or β angle should be no less than 60°.
Category III (C3): Two or 3 separate canals and both angles, α and β , were less than 60°.
Category IV (C4): A single round or oval canal.
Category V (C5): No canal lumen could be observed.

C4 canals were not classified as C-shaped canals [2].

The data were expressed as numbers with percentages for categorical variables. The prevalence of C-shaped canals with respect to age, sex, and tooth position was evaluated. For comparisons, the data were assessed using the χ^2 test or the Fisher's exact test according to

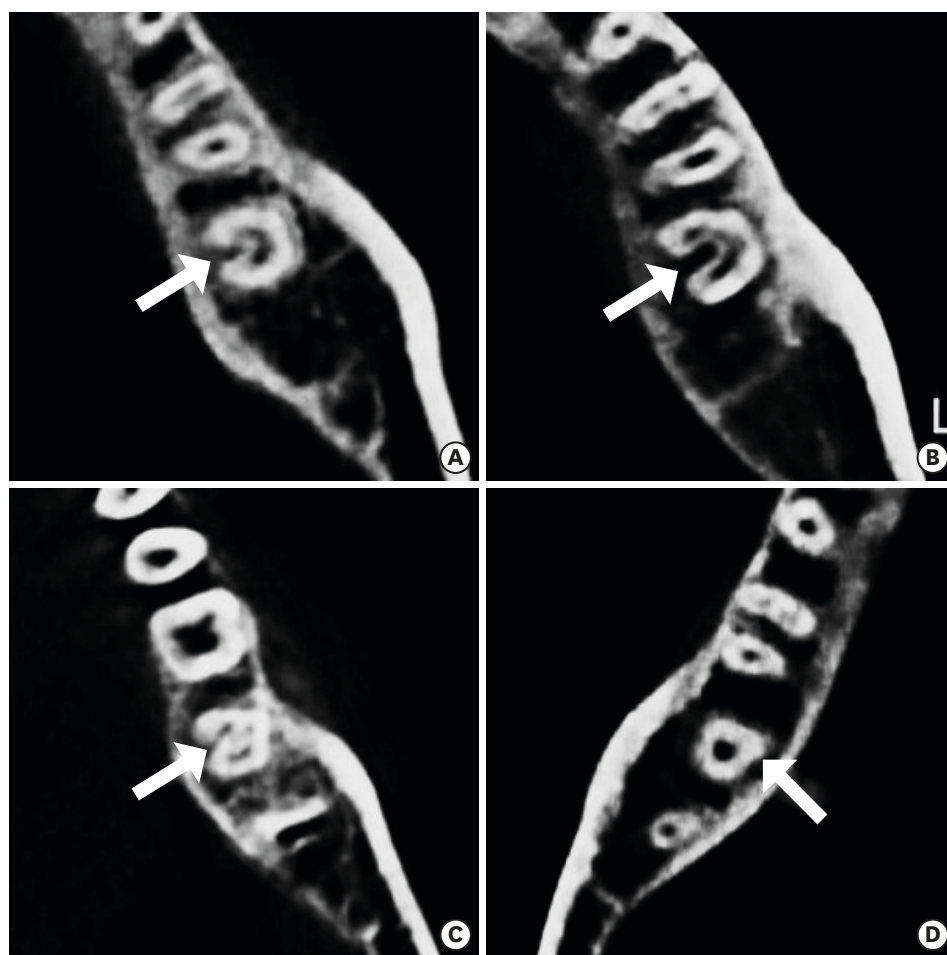


Figure 1. Classification of C-shaped canal systems using a modified version of Melton's method. (A) category I (C1), (B) category II (C2), (C) category III (C3), and (D) category IV (C4).

the expected numbers in the corresponding cells. Statistical significance was set at $p < 0.05$. All statistical analyses were performed using SPSS version 20 (IBM Corp., Armonk, NY, USA).

RESULTS

Thirty-nine of the C-shaped canals (18.1%) were classified as category I, 98 (45.6%) as category II, and 78 (36.3%) as category III (**Table 1**). Category IV (not classified as a C-shaped canal) morphology was observed in 9 (1.7%) of the mandibular second molars, and category V was not observed in this study (**Table 2**).

Table 1. Configurations of C-shaped canals

Category	Male	Female	Total
Category I (C1)	14 (22.2)	25 (16.4)	39 (18.1)
Category II (C2)	30 (47.6)	68 (44.7)	98 (45.6)
Category III (C3)	19 (30.2)	59 (38.8)	78 (36.3)

Values are presented as number (%).

Table 2. Number and frequency of root canals in mandibular second molars

Root canal	Male	Female	Total
1 canal	0 (0.0)	9 (2.8)	9 (1.7)
2 canals	12 (5.4)	6 (1.9)	18 (3.3)
3 canals	144 (64.9)	142 (44.7)	286 (53.0)
4 canals	3 (1.4)	9 (2.8)	286 (53.0)
C-shaped canal	63 (28.4)	152 (47.8)	215 (39.8)

Table 3. Number and frequency of C-shaped canals by tooth position

Tooth position	Male	Female	Total
Left	28 (44.4)	81 (53.3)	109 (50.7)
Right	35 (55.6)	71 (46.7)	106 (49.3)

Table 4. Number and frequency of C-shaped canals by sex and age

Age	Male		Female	
	Number	C-canals	Number	C-canals
10s	8	2 (25.0)	40	21 (52.5)
20s	148	40 (27.0)	182	86 (47.3)
30s	46	12 (26.1)	72	34 (47.2)
40s	12	5 (41.7)	20	10 (50.0)
50s	6	4 (66.7)	4	1 (25.0)
60s	2	0 (0.0)	-	-
Total	222	63 (28.4)	318	152 (47.8)

Among the 540 mandibular second molars examined, the prevalence of C-shaped canals was 39.8% (**Table 2**). Of the C-shaped canals, 50.7% were found on the left side of the mandible, while 49.3% were on the right side (**Table 3**). However, the correlation between the presence of a C-shaped canal with tooth position was not significant ($p > 0.05$). Bilateral C-shaped canals occurred in 71.6% of cases (154 of 215 C-shaped canals), which was a statistically significant trend.

The distribution of C-shaped canals by age is shown in **Table 4**. No statistically significant difference was observed.

Statistically significant differences were found in the distribution of C-shaped canals by sex. Female patients showed a prevalence of 47.8%, while males showed a prevalence of 28.4% (**Table 2**).

The most common canal configuration of mandibular second molars was 3 separate canals (53%) with 2 or 3 separate roots (2 mesial roots, 1 distal root) (**Table 2**).

DISCUSSION

Studies of mandibular second molars have demonstrated that C-shaped canals are more frequent in East Asian populations than in other ethnic groups [5-7,12,18,20,21,24,25,30]. Cooke and Cox [1] and Weine [4] reported that 2.7%, 7.6%, and 8.1% of mandibular second molars in Americans were identified as C-shaped, respectively [10]. In the literature, C-shaped canals were found in 8% of participants in Turkish studies [12,19], 10% in a Saudi Arabian study [17], 19.1% in a Lebanese study [14], 7.5% in an Indian study [23], 3% in a Sri Lankan study [22], 22.4% in a Burmese study [15], 10% in a Thai study [16], and 15.3% in a Brazilian study [10]. In the Chinese population, investigators have reported a high prevalence of C-shaped canals, ranging from 29% [6] to 41% [25]. The C-shaped canal was found to be most common in the Korean population, with a

reported prevalence ranging from 31% [18] to 44.5% [20]. According to the results of this study, the prevalence of C-shaped canals was 39.8%, which is similar to the results of previous studies.

In this study, age and tooth position (left *versus* right) showed no correlation with the prevalence of C-shaped canals in the mandibular second molars. These data are consistent with the findings of previous reports [5,10,12,30].

Moreover, the prevalence of C-shaped canals was significantly higher in females than males, which is in accordance with the results of a recent study [30]. This result is in contrast to the findings of earlier investigators [5,10,12,20]. The discrepancies in these results may have been due to differences in the subjects and the sample size.

The C-shaped canals of this study were bilateral in 71% of the sample. Zheng et al. [5] reported that a bilateral distribution was present in 82% of their sample, and Kim et al. [30] reported a bilateral distribution of 81% among their participants. In contrast, Ladeira et al. [10] reported that bilateral C-shaped canals were less frequent (31.7%) in Brazilians. These data indicate that it is important for dentists to consider the possibility of a C-shaped canal in the opposite second molar if a patient has a C-shaped canal in a mandibular second molar.

The most common configuration types of the C-shaped canals were C2 (semicolon-shaped) canals (45.6%), which is similar to the results of the previous study by Seo and Park [18]. However, in other studies, the C1 (continuous C-shaped) canal type was the most common at the orifice level [5,12,30]. Different sample sizes and ethnic backgrounds of subjects might explain these inconsistencies.

CONCLUSIONS

There was a high prevalence of C-shaped canals in the mandibular second molars of the Korean population studied. CBCT is expected to be useful for endodontic diagnosis and treatment planning of mandibular second molars.

REFERENCES

1. Cooke HG 3rd, Cox FL. C-shaped canal configurations in mandibular molars. *J Am Dent Assoc* 1979;99:836-839.
[PUBMED](#) | [CROSSREF](#)
2. Fan B, Cheung GS, Fan M, Gutmann JL, Bian Z. C-shaped canal system in mandibular second molars: part I--anatomical features. *J Endod* 2004;30:899-903.
[PUBMED](#) | [CROSSREF](#)
3. Melton DC, Krell KV, Fuller MW. Anatomical and histological features of C-shaped canals in mandibular second molars. *J Endod* 1991;17:384-388.
[PUBMED](#) | [CROSSREF](#)
4. Weine FS. The C-shaped mandibular second molar: incidence and other considerations. *J Endod* 1998;24:372-375.
[PUBMED](#) | [CROSSREF](#)
5. Zheng Q, Zhang L, Zhou X, Wang Q, Wang Y, Tang L, Song F, Huang D. C-shaped root canal system in mandibular second molars in a Chinese population evaluated by cone-beam computed tomography. *Int Endod J* 2011;44:857-862.
[PUBMED](#) | [CROSSREF](#)

6. Zhang R, Wang H, Tian YY, Yu X, Hu T, Dummer PM. Use of cone-beam computed tomography to evaluate root and canal morphology of mandibular molars in Chinese individuals. *Int Endod J* 2011;44:990-999.
[PUBMED](#) | [CROSSREF](#)
7. Seo DG, Gu Y, Yi YA, Lee SJ, Jeong JS, Lee Y, Chang SW, Lee JK, Park W, Kim KD, Kum KY. A biometric study of C-shaped root canal systems in mandibular second molars using cone-beam computed tomography. *Int Endod J* 2012;45:807-814.
[PUBMED](#) | [CROSSREF](#)
8. Walid N. The use of two pluggers for the obturation of an uncommon C-shaped canal. *J Endod* 2000;26:422-424.
[PUBMED](#) | [CROSSREF](#)
9. Liewehr FR, Kulild JC, Primack PD. Obturation of a C-shaped canal using an improved method of warm lateral condensation. *J Endod* 1993;19:474-477.
[PUBMED](#) | [CROSSREF](#)
10. Ladeira DB, Cruz AD, Freitas DQ, Almeida SM. Prevalence of C-shaped root canal in a Brazilian subpopulation: a cone-beam computed tomography analysis. *Braz Oral Res* 2014;28:39-45.
[PUBMED](#) | [CROSSREF](#)
11. Jafarzadeh H, Wu YN. The C-shaped root canal configuration: a review. *J Endod* 2007;33:517-523.
[PUBMED](#) | [CROSSREF](#)
12. Helvacioğlu-Yigit D, Sinanoğlu A. Use of cone-beam computed tomography to evaluate C-shaped root canal systems in mandibular second molars in a Turkish subpopulation: a retrospective study. *Int Endod J* 2013;46:1032-1038.
[PUBMED](#)
13. Fan B, Min Y, Lu G, Yang J, Cheung GS, Gutmann JL. Negotiation of C-shaped canal systems in mandibular second molars. *J Endod* 2009;35:1003-1008.
[PUBMED](#) | [CROSSREF](#)
14. Haddad GY, Nehme WB, Ounsi HF. Diagnosis, classification, and frequency of C-shaped canals in mandibular second molars in the Lebanese population. *J Endod* 1999;25:268-271.
[PUBMED](#) | [CROSSREF](#)
15. Gulabivala K, Aung TH, Alavi A, Ng YL. Root and canal morphology of Burmese mandibular molars. *Int Endod J* 2001;34:359-370.
[PUBMED](#) | [CROSSREF](#)
16. Gulabivala K, Opananon A, Ng YL, Alavi A. Root and canal morphology of Thai mandibular molars. *Int Endod J* 2002;35:56-62.
[PUBMED](#) | [CROSSREF](#)
17. Al-Fouzan KS. C-shaped root canals in mandibular second molars in a Saudi Arabian population. *Int Endod J* 2002;35:499-504.
[PUBMED](#) | [CROSSREF](#)
18. Seo MS, Park DS. C-shaped root canals of mandibular second molars in a Korean population: clinical observation and *in vitro* analysis. *Int Endod J* 2004;37:139-144.
[PUBMED](#) | [CROSSREF](#)
19. Cimilli H, Cimilli T, Mumcu G, Kartal N, Wesselink P. Spiral computed tomographic demonstration of C-shaped canals in mandibular second molars. *Dentomaxillofac Radiol* 2005;34:164-167.
[PUBMED](#) | [CROSSREF](#)
20. Jin GC, Lee SJ, Roh BD. Anatomical study of C-shaped canals in mandibular second molars by analysis of computed tomography. *J Endod* 2006;32:10-13.
[PUBMED](#) | [CROSSREF](#)
21. Lu TY, Yang SF, Pai SF. Complicated root canal morphology of mandibular first premolar in a Chinese population using the cross section method. *J Endod* 2006;32:932-936.
[PUBMED](#) | [CROSSREF](#)
22. Peiris HR, Pitakotuwage TN, Takahashi M, Sasaki K, Kanazawa E. Root canal morphology of mandibular permanent molars at different ages. *Int Endod J* 2008;41:828-835.
[PUBMED](#) | [CROSSREF](#)
23. Neelakantan P, Subbarao C, Subbarao CV, Ravindranath M. Root and canal morphology of mandibular second molars in an Indian population. *J Endod* 2010;36:1319-1322.
[PUBMED](#) | [CROSSREF](#)
24. Karanxha L, Kim HJ, Hong SO, Lee W, Kim PS, Min KS. Endodontic management of a C-shaped maxillary first molar with three independent buccal root canals by using cone-beam computed tomography. *Restor Dent Endod* 2012;37:175-179.
[PUBMED](#) | [CROSSREF](#)

25. Wang Y, Guo J, Yang HB, Han X, Yu Y. Incidence of C-shaped root canal systems in mandibular second molars in the native Chinese population by analysis of clinical methods. *Int J Oral Sci* 2012;4:161-165.
[PUBMED](#) | [CROSSREF](#)
26. Nie YK, Bakar WZ, Alam MK. The occurrence of C-shaped root canal in Malaysian population. *Bangladesh J Med Sci* 2013;12:286-290.
[CROSSREF](#)
27. Plotino G, Tocci L, Grande NM, Testarelli L, Messineo D, Ciotti M, Glassman G, D'ambrosio F, Gambarini G. Symmetry of root and root canal morphology of maxillary and mandibular molars in a white population: a cone-beam computed tomography study *in vivo*. *J Endod* 2013;39:1545-1548.
[PUBMED](#) | [CROSSREF](#)
28. Chhabra S, Yadav S, Talwar S. Analysis of C-shaped canal system in mandibular second molars using surgical operating microscope and cone beam computed tomography: a clinical approach. *J Conserv Dent* 2014;17:238-243.
[PUBMED](#) | [CROSSREF](#)
29. Amoroso-Silva PA, Ordinola-Zapata R, Duarte MA, Gutmann JL, del Carpio-Perochena A, Bramante CM, de Moraes IG. Micro-computed tomographic analysis of mandibular second molars with C-shaped root canals. *J Endod* 2015;41:890-895.
[PUBMED](#) | [CROSSREF](#)
30. Kim SY, Kim BS, Kim Y. Mandibular second molar root canal morphology and variants in a Korean subpopulation. *Int Endod J* 2016;49:136-144.
[PUBMED](#) | [CROSSREF](#)