



## Case Report

# A Patient with Ankylosing Spondylitis Treated with Acupotomy and Traditional Korean Medicine



Beom Seok Kim, Jae Ik Kim, Hyo Bin Kim, Ye Ji Lee, Ki Jung Sung, Ju Hyun Jeon, Eunseok Kim, Young Il Kim\*

Department of Acupuncture and Moxibustion Medicine, College of Korean Medicine, Daejeon University, Daejeon, Korea

## ABSTRACT

### Article history:

Submitted: June 19, 2019

Revised: July 8, 2019

Accepted: July 22, 2019

### Keywords:

acupotomy, ankylosing spondylitis, Korean traditional medicine, questionnaire

This case report relates to a 40-year old male patient diagnosed with ankylosing spondylitis who was treated with acupotomy and traditional Korean medicine. He showed a significant improvement in joint range of motion (ROM) in cervical and lumbar vertebrae, and in pain and functional disorder symptoms. The patient received acupotomy, acupuncture, pharmacopuncture, herbal medicine and physical therapy (November 26, 2018 to December 17, 2018). Joint ROM for cervical and lumbar vertebrae was measured, and the pain level was assessed using a numerical rating scale. The functional disorder and quality of life scales were also assessed using the Bath Ankylosing Spondylitis Functional Index, Bath Ankylosing Spondylitis Disease Activity Index, Korean Health Assessment Questionnaire, and Modified Health Assessment Questionnaire. After applying acupotomy and traditional Korean medicine, the patient exhibited increased joint ROM and reduced pain, also in conjunction with improved responses in functional disorder and quality of life.

<https://doi.org/10.13045/jar.2019.00136>  
pISSN 2586-288X eISSN 2586-2898

©2019 Korean Acupuncture & Moxibustion Medicine Society. This is an open access article under the CC BY-NC-ND license (<http://creativecommons.org/licenses/by-nc-nd/4.0/>).

## Introduction

Ankylosing spondylitis is a representative disease of seronegative spondyloarthropathies and is a chronic inflammatory disease characterized by spondylitis and sacrocoxitis [1]. It is known that the gene HLA-B27 is a genetic factor associated with ankylosing spondylitis [2]. This disease gradually induces ossification of the articular capsules and spinal ligaments, as well as spasticity of the sacroiliac joint and spine, causing spinal deformation [3]. Symptoms are similar to joint disorders for example repeated improvement and deterioration in the spine, hip joints and shoulder joints, and sometimes presents as vertebral body fusion “bamboo spine” in X-ray images of the lumbar vertebrae [3]. The prevalence rate of ankylosing spondylitis is around 0.1%-0.4%, with males having a far higher occurrence rate than females (10 male versus 1 female) [3].

The primary treatment goal in ankylosing spondylitis is to maintain and recover function, by reducing the level of pain experienced [1]. Use of Non-steroidal anti-inflammatory drugs or local steroids can reduce pain. However, surgery is the only

treatment for spinal curvature to enable a straight posture [1].

In Western medicine clinical research is focused on treatment and functional assessment of ankylosing spondylitis [2,3]. However, in traditional Korean medicine, there is currently insufficient research. Acupotomy is acupuncture treatment that exfoliates the conglutination of soft tissues using a needle with a flat-shaped tip similar to a scalpel, and is widely used for diseases causing chronic pain [4]. To date research into traditional Korean medicine treatment for ankylosing spondylitis has not been published, particularly regarding acupotomy treatment. However, there are case reports on acupuncture [5], pharmacopuncture [6], and herbal medicine administration [7], and, there are a report has been published where Chinese traditional medicine has been used to treat ankylosing spondylitis using [8]. Thus, this current study performed combination treatment including acupotomy and Korean medicine, on a patient with ankylosing spondylitis who had limited mobility and severe pain, resulting in Significant improvement in mobility and pain. This study was exempt from IRB deliberation (IRB No: DJDSKH-19-E-08).

\*Corresponding author.

Department of Acupuncture and Moxibustion Medicine, College of Korean Medicine, Daejeon University, Daejeon, Korea

E-mail: [omdkim01@dju.kr](mailto:omdkim01@dju.kr)

ORCID: Beom Seok Kim <https://orcid.org/0000-0001-9572-288X>, Young Il Kim <https://orcid.org/0000-0001-9221-3238>

## Case Report

### Participant

Moon OO (Male, 40 years)

### Principal Complaints

Back, neck and shoulder pain, lumbar pain, limited flexion and extension as well as spasticity in cervical vertebrae, and limited flexion and extension in lumbar vertebrae.

### Onset and Cause

Symptoms first occurred during 1998 with no specific cause. Pain and spasticity became severe during 2015.

### Past History

The patient had a 10-year history of treatment for gastrointestinal disturbance at a local clinic from 2003 to 2013.

### Family History

None

### Present Status

The patient first presented with symptoms in 1998 and was diagnosed with ankylosing spondylitis at a local clinic. During treatment with analgesic and relevant steroid injections, the patient complained of severe symptoms without cause in 2015, and was hospitalized at the OO Korean Medicine hospital from November 26 to December 17, 2018.

### Physical Examination

Foraminal compression and distraction tests (physical examinations of the neck) exhibited a normal status however, Spurling's test and Jackson Compression test were not performed (due to spasticity in the cervical portion). Initially, the cervical range of motion (ROM) showed 0° in each of flexion, extension, lateral bending and rotation. Physical lumbar tests, (such as Straight Leg Raising, Bragard, Patrick, Ankle dorsiflexion, and Ankle Plantarflexion) all showed a normal status, and assessment of the initial ROM in the lumbar area was measured as flexion 60°, extension 0°, lateral bending 35°/35° and rotation 45°/45°.

### Blood Test

An antibody to hepatitis B surface antigen qualitative test showed a weakly positive result, and erythrocyte sedimentation rate was elevated to 23 mm/hr. Other tests, including blood chemistry, complete blood cell count, and urinalysis, all showed normal values.

### Radiology Findings

X-ray images indicated ankylosing spondylitis, and narrowing of the L4-5 disc space in the L-S spine A/L, and the patient was diagnosed as having ankylosing spondylitis in C-spine A/L (Figs. 1-4).

### Treatment Methods

#### Acupotomy

The patient underwent acupotomy treatment for 3 sessions per week, on Monday, Tuesday and Friday, for 9 sessions in total during his 22 days of hospitalization. The practitioner explained the principles, side effects, and treatment effects of the acupotomy therapy before treatment, and obtained a signed informed consent form from the patient (Appendix A).

Before performing acupotomy, the practitioner asked the Family

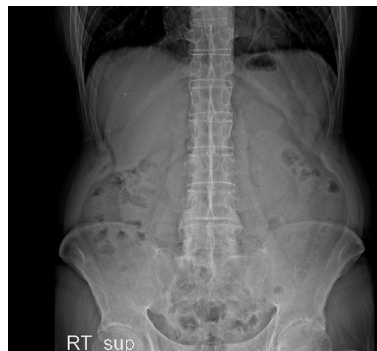

Fig. 1. L-S Spine anterior posterior (2018.11.26).

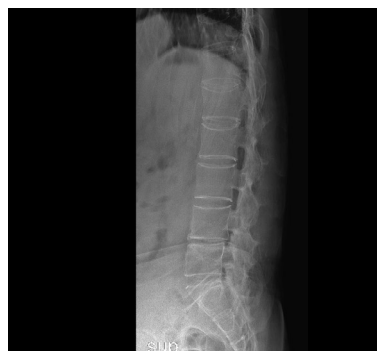

Fig. 2. L-S spine lateral (2018.11.26).

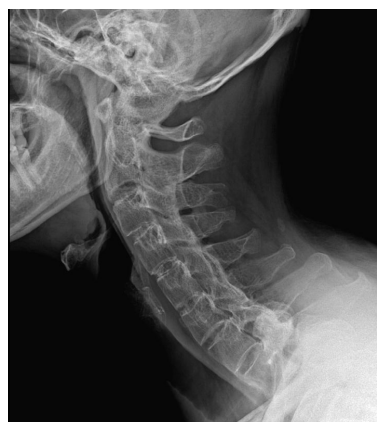

Fig. 3. C-spine lateral (2018.11.26).

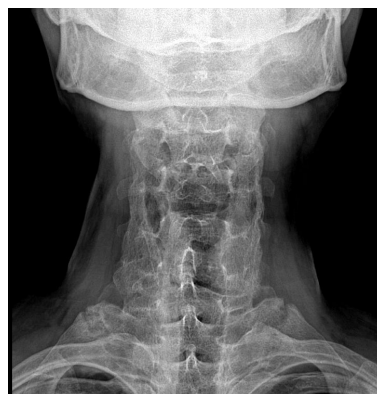

Fig. 4. C-spine anterior posterior (2018.11.26).

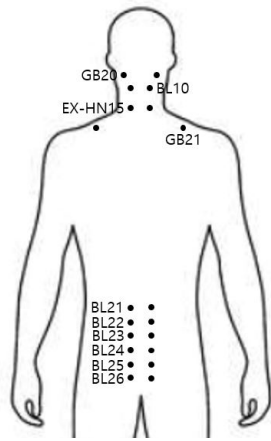


Fig. 5. Acupotomy points.

Medicine Department to perform local anesthesia with 0.5 mL of 2% lidocaine hydrochloride salt hydrate (Daehan Corp.) using a 13 mm, 30 g needle on the area surrounding the site for acupotomy. In addition, the practitioner disinfected the acupotomy site using a disposable swab soaked in alcohol and a povidon stick (Green Corp.). DongBang acupotomy needles (DongBang Corp., 0.75 mm x 80 mm disposable) were used. The needles were placed in parallel with the nerves and blood vessels, to a depth of 5 mm -10 mm on hard nodules of the cervical vertebrae (such as GB20, GB21, BL10, and EX-HN15), and lumbar vertebrae (such as BL21, BL22, BL23, BL24, BL25, and BL26). Afterwards, a needle was slid in and out, then was taken out (Fig. 5).

Acupotomy was performed by a specialist with 10 years' experience in acupotomy treatment who worked in the Acupuncture and Moxibustion Medicine Department. The practitioner wore sterilized latex gloves and a surgical mask before treatment, and recorded the occurrence of any abnormal response on the entire body and local sites after treatment. Additionally, the practitioner gave an explanation to the patient about symptoms that might occur after treatment such as bleeding, drop in blood pressure, tenderness, or dizziness.

#### Acupuncture

Acupuncture was performed once on the day of acupotomy (before acupotomy), and twice (in the morning and afternoon) on the days without acupotomy treatment. DongBangchim needles (DongBang Corp., 0.25 mm x 30 mm, disposable, sterilized stainless steel) were used to perform the acupuncture, and left in-site for 15 minutes. Acupuncture treatment was performed on the cervical vertebrae acupoints (GB20, BL10, GB12, GB21, and EX-HN15), the lumbar vertebrae in the proximal area (BL21, BL22, BL23, BL24, BL25, and BL26), and the distal area (SI3, BL62, TE3, GB39, GB34, BL40, ST36, and BL60) [4].

#### Pharmacopuncture

Pharmacopuncture treatment was performed every day, in the morning. Bee venom pharmacopuncture was performed on Monday, Wednesday, Friday and Saturday, and Soyeom pharmacopuncture was performed on Tuesday, Thursday and Sunday (once per day for both pharmacopuncture treatments). Bee venom pharmacopuncture (Korean Pharmacopuncture Research Institute) is mixed with refined 99.9% pure melittin, 0.10 mg/mL was administered (using a 13 mm 30 g needle) per pharmacopuncture treatment with a total of 2 mL used for each

Table 1. Composition of Jakyakgamcho-tang.

| Scientific name            | Amounts (g) per pack |
|----------------------------|----------------------|
| <i>Paeoniae Alba Radix</i> | 16                   |
| <i>Glycyrrhizae Radix</i>  | 8                    |

Table 2. Composition of Samgieum-gagam.

| Scientific name                     | Amounts (g) per pack |
|-------------------------------------|----------------------|
| <i>Rehmanniae Radix Preparata</i>   | 12                   |
| <i>Eucommiae Cortex</i>             | 6                    |
| <i>Achyranthis Bidentatae Radix</i> | 6                    |
| <i>Angelicae Gigantis Radix</i>     | 6                    |
| <i>Lycii Fructus</i>                | 6                    |
| <i>Paeoniae Alba Radix</i>          | 6                    |
| <i>Cnidii Rhizoma</i>               | 4                    |
| <i>Poria Cocos</i>                  | 4                    |
| <i>Cinnamomi Cortex</i>             | 4                    |
| <i>Angelicae Pubescentis Radix</i>  | 3                    |
| <i>Angelicae Dahuricae Radix</i>    | 3                    |
| <i>Glycyrrhizae Radix</i>           | 3                    |
| <i>Zingiberis Rhizoma Crudus</i>    | 12                   |
| <i>Jujubae Fructus</i>              | 8                    |

treatment. It was performed on the acupoints GB20, GB21, BL10, and EX-HN15 in the cervical vertebrae portion, and BL21, BL22, BL23, BL24, BL25, and BL26 in the lumbar vertebrae portion. During bee venom pharmacopuncture, the syringe was not inserted all the way into the muscle, but to a depth of 3 mm - 5 mm to give a hypodermic injection. Soyeom pharmacopuncture (Korean Pharmacopuncture Research Institute) was also performed on BL10 and EX-HN15 in the cervical vertebral portion, and BL24 and BL26 in the lumbar vertebrae portion, with a total of 2 mL, 0.25 mL per acupoint, using a 13 mm 30 g needle [4].

#### Herbal Medicine

Jakyakgamcho-tang and Samgieum-gagam herbal medicine was prescribed. During the first 3 days in hospital Jakyakgamcho-tang was administered 3 times per day, 30 minutes after each meal (120 mL per pack). Samgieum-gagam was administered 3 times per day, 30 minutes after each meal for 19 days (120 mL per pack) at 30 minutes after each meal (Tables 1 and 2).

#### Physical therapy

The patient had deep-layer thermal treatment using microwaves on both cervical and lumbar vertebrae, once per day for 15 minutes.

Table 3. ROM Before and After Treatment.

|                |                 | D <sub>0</sub> | ≥ D <sub>7</sub> | ≥ D <sub>14</sub> | ≥ D <sub>21</sub> |
|----------------|-----------------|----------------|------------------|-------------------|-------------------|
| Cervical spine | Flexion         | 0°             | 5°               | 10°               | 10°               |
|                | Extension       | 0°             | 5°               | 10°               | 10°               |
|                | Lateral bending | 0°/0°          | 0°/0°            | 5°/5°             | 5°/5°             |
|                | Rotation        | 0°/0°          | 10°/10°          | 10°/10°           | 10°/10°           |
| Lumbar spine   | Flexion         | 60°            | 70°              | 70°               | 70°               |
|                | Extension       | 0°             | 0°               | 0°                | 0°                |
|                | Lateral bending | 35°/35°        | 35°/35°          | 35°/35°           | 35°/35°           |
|                | Rotation        | 45°/45°        | 45°/45°          | 45°/45°           | 45°/45°           |

**Evaluation**

The patient was assessed for ROM and numerical rating scale (NRS) [9] at 7 AM, before starting the acupotomy treatment, for 21 days. In addition, the Bath Ankylosing Spondylitis Functional Index (BASFI) [10] (Appendix B), the Bath Ankylosing Spondylitis Disease Activity Index (BASDAI) [11] (Appendix C), the Modified Health Assessment Questionnaire (M-HAQ) [12] (Appendix D), and the Korean Health Assessment Questionnaire (K-HAQ) [13] (Appendix E) were used before acupotomy treatment on the first day of hospitalization, and 21 days after the first assessment. The results of the 2 assessments were compared. BASFI, BASDAI and M-HAQ were assessed in the form of interviews since there is not a Korean version, and K-HAQ was assessed in survey form.

**Progress**

In the cervical vertebral ROM of the patient, flexion, extension, lateral bending and rotation were all measured as 0° initially before treatment. The patient showed improvement at discharge, with flexion of 10°, extension 10°, lateral bending 5°/5°, and rotation 10°/10°. In lumbar ROM measurement, the patient showed normal values in lateral bending and rotation. However, the patient was limited initially, showing flexion of 60° and extension 0°. When discharged from hospital, the patient showed a slight improvement in flexion of 70°, but no improvement in extension with 0° (Table 3). In early hospitalization, the NRS in both cervical and lumbar vertebrae of the patient were measured to be 7 and 6, respectively. Both NRS reduced consistently until the 9<sup>th</sup> day of hospitalization and scored 2.5 in the cervical vertebrae and 1.5 in the lumbar vertebrae. However, no further improvement was observed after that date (Fig. 6).

BASFI score improved from 5.5 in early hospitalization to 4.0 at discharge, and the BASDAI score also showed an improvement from 6.2 to 5.2. In addition, K-HAQ showed improvement, with a decrease from a score of 11 in early hospitalization, to 7 at discharge. Stiffness and activity scores were 100 and 2 respectively, in early hospitalization which improved to 70 for stiffness and 1 for activity in the M-HAQ (Tables 4 and 5).

**Discussion**

Ankylosing spondylitis commonly develops in young male adults less than 40 years old, and is a chronic disease, mainly affecting the spine and sacroiliac joints causing synostosis, thereby

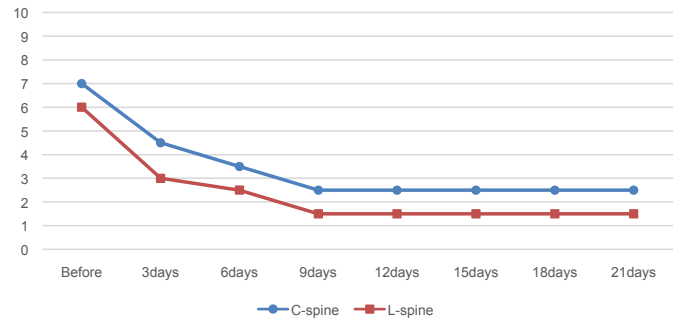


Fig. 6. The change of NRS at before and after acupotomy treatment. NRS, numerical rating scale.

Table 4. BASFI and BASDAI Before and After Treatment.

|        | D <sub>0</sub> | ≥ D <sub>21</sub> |
|--------|----------------|-------------------|
| BASFI  | 5.5            | 4.0               |
| BASDAI | 6.2            | 5.2               |

BASFI, Bath Ankylosing Spondylitis Functional Index; BASDAI, Bath Ankylosing Spondylitis Disease Activity Index.

Table 5. K-HAQ and M-HAQ Before and After Treatment.

|       |                | D <sub>0</sub> | ≥ D <sub>21</sub> |
|-------|----------------|----------------|-------------------|
| K-HAQ |                | 11             | 7                 |
| M-HAQ | Stiffness      | 100            | 70                |
|       | Activity score | 2              | 1                 |

K-HAQ, Korean Health Assessment Questionnaire; M-HAQ, Modified Health Assessment Questionnaire.

resulting in spasticity of the spine and constraint in ROM [1]. It is known to be associated with the HLA-B27 gene which is present in 4% of the general population. However, in Caucasian patients with ankylosing spondylitis, between 90% to 100% have the HLA-B27 gene, whereas 83% of Korean ankylosing spondylitis patients have the gene [14]. Detection of HLA-B27 can help with early diagnosis of the disease if X-ray images cannot accurately confirm the condition, even if the patient is exhibiting symptoms of ankylosing spondylitis [14]. In the clinical setting, if a patient displays onset before 40 years of age, has lumbar pain lasting more than 3 months, shows early spasticity and decreased pain by exercise, then the patient may have ankylosing spondylitis [1]. Radiology can show the sacroiliac joint facet blurred on initial X-ray images and as the condition progresses punched-out erosion appears. Pseudo-widening and adjacent sclerosis are also observed, and the gap in the sacroiliac joint facets is reduced to nothing [15]. In the spine, the lumbar frontal curve is lost, osteoporosis appears, the facet joint is blurred, and a temporary bridge (bamboo spine) is formed around the spine in severe cases [15].

Treatment of pain with Non-steroidal anti-inflammatory drugs and local steroid injections are crucial in controlling pain [1]. Swimming is recommended to maintain spinal activity, and to prevent deformation of the spine and contact sports are also recommended to avoid bone fractures. Surgical treatment (spine osteotomy) may be considered when there's a narrow visual range, due to significant curved back deformation and severe pain [16].

The acupotomy treatment applied to ankylosing spondylitis in this case study is a new treatment that combines the theory of acupuncture and moxibustion medicine, with surgical therapy of modern medicine, in order to perform the functions of both acupuncture and scalpel simultaneously [4]. More specifically, acupotomy is a treatment for chronic pain caused by soft tissue damage, by performing incision, amputation or synechotomy, of soft tissue [4]. In addition, the acupotomy treatment exfoliates the chronically damaged adhesive tissues from soft tissues, peritendineum, muscles or ligaments, and exerts a mechanical stimulation in order to dilate the microcirculatory system to increase nutritional supply to tissue lesions, releasing the constraints of the muscles, thereby inducing local recovery [4]. There were 60 papers associated with acupotomy that were published before February 12, 2018, 33 reports discussed soft tissue, osseous tissue and pain triggering points in skeletal muscles, and 27 did not specify the lesion [17]. Acupotomy treatment can be seen to be highly adaptable to muscular skeletal diseases. Furthermore, Korean medicine treatments, including acupuncture, pharmacopuncture and herbal medicine, all require a treatment period of at least 4 weeks [5-7]. On the other hand, acupotomy treatment has the advantage of being a relatively simple procedure, which shows rapid improvement as observed in this study (up to the 9<sup>th</sup> day after treatment). It also causes less pain than a surgical procedure [4] and has a significant effect on patients who show no further improvement with conventional medicine or conservative treatments, as well as with those who have an objection to surgical procedures.

From a radiological perspective, assessment of ankylosing spondylitis after treatment is performed based on different physical examinations. There is measurement of the rear curved angle in the thoracic vertebrae, the frontal curved angle in the lumbar vertebrae or the horizontal angle in the sacral vertebrae, and ROM (finger to floor distance, occiput to wall distance, Smythe's test, and chest expansion) [12]. In addition, the following functional tests are used: Arthritis Impact Measurement Scale 2 [18], BASFI [10], BASDAI [11], M-HAQ [12], K-HAQ [13], Spondylitis Functional Index [19], Dougados Functional Index [19]. In

rheumatic diseases, these functional assessment questionnaires have a high correlation with the objective factors of a disease, such as pain level, turgescence and spasticity or deformation in joints and therefore the values of assessments of treatment effects are recognized [20].

The critical point of acupotomy treatment of ankylosing spondylitis was to choose the acupotomy points that allow incision of the origins of musculus splenius capitis, trapezius muscle and musculus splenius cervicis, as well as interspinal ligaments in the case of the cervical vertebral portion. In addition, the main objective was to exfoliate the conglutination and induration of the attached site in cervical vertebra tissues, in order to eliminate the restrictions. In the lumbar vertebrae portion, it was intended to eliminate the restrictions and pain by choosing the acupotomy points (tilting acupotomy) that allow exfoliation not only the conglutinated tissues at near the upper and lower zygapophyses, intervertebral foramen and transverse process muscles, but also the ligamenta flava in deeper parts. In this case study, a combination treatment of acupotomy and Korean medicine was performed on the male patient with ankylosing spondylitis. As a result, the ROM of both cervical and lumbar vertebrae showed improvement to a certain degree. In addition, the NRS score for the cervical and lumbar vertebrae of the patient in early hospitalization, showed improvement up to the 9th day, and was maintained at the same level until discharge. The combined treatment of acupotomy and Korean medicine improved ROM and NRS scores. However, after the patient exhibited a certain degree of improvement no more improvements were observed. This is thought to be due to the long duration of disease, and the characteristics of ankylosing spondylitis that requires consistent management.

In future studies, a follow-up discussion about additional treatment methods to reduce any remaining pain and discomfort after acupotomy therapy will be necessary. In addition, the survey questionnaire indicators for BASFI, BASDAI, K-HAQ and M-HAQ also showed improvement after treatment, and the combination treatment of acupotomy therapy and Korean medicine was effective not only for improving the level of pain in patients, but also in improving functional disorders. However, there are several limitations to this case study. This study included just 1 patient and there was not a control for this study, and the patient did not have a follow-up consultation after discharge. In addition, the patient was not able to complete the survey questionnaires (BASFI, BASDAI and M-HAQ) BASFI, BASDAI and M-HAQ on his own, and these surveys were completed in the form of an interview because there was no Korean version available. Moreover, specificity was relatively low for ankylosing spondylitis in the case of the K-HAQ, and further objective assessment criteria were not applied (except for symptom assessment or questionnaires). Additionally, pharmacopuncture and herbal medicine administration were empirically selected. This study performed both acupotomy and Korean combination treatment simultaneously however, it is not clear whether acupotomy treatment alone has caused the positive effects. In order to verify the effectiveness of acupotomy on patients with ankylosing spondylitis, large-scale clinical trials are required. However, as verified in this study, the patient with ankylosing spondylitis who had experienced no significant benefits from using analgesic and local steroid injections for 20 years, after the combined treatment with acupotomy and Korean medicine showed an improvement in ROM, NRS, BASFI, BASDAI, K-HAQ and M-HAQ. This suggests potential benefits of acupotomy treatment on patients with ankylosing spondylitis.

## Conflicts of Interest

The authors have no conflicts of interest to declare.

## References

- [1] Suk SI, Lee CK, Baek GH, Song KS, Lee MC, Lee HM et al. The Korean Orthopaedic Association. Orthopaedics, 7th ed. Seoul (Korea): Newest Medicine Company; 2013. p. 312-315. [in Korean].
- [2] Sjöf L, Desiree H. Ankylosing spondylitis: clinical features. *Rheum Dis Clin North Am* 1998;24:663-676.
- [3] Kim TH, Lee IH, Kim BY, Bae SC, Yoo DH, Park CY et al. A Clinical Study of 78 Cases of Ankylosing Spondylitis. *Korean J Med* 1991;41:73-80. [in Korean].
- [4] Yook TH, No JD, Kim JH, Kim JW, Nam DW, Yang KY et al. Korean Acupuncture & Moxibustion Society Textbook Compilation Committee. *Acupuncture Medicine*, 4th ed. Seoul (Korea): Hanmi Medicine Publish Company; 2016. p. 173-180, 204-228 472-474, 487, 491-494, 510-512. [in Korean].
- [5] Lv Z, Zhou X, Chen A. Acupuncture Therapy versus Disease-modifying Antirheumatic Drugs for the Treatment of Ankylosing Spondylitis-a Meta-analysis. *Forsch Komplementmed* 2015;22:395-402. [in German].
- [6] Seo DM, Lee SH, Lee JD, Choi DY, Kim CH, Lee YH et al. Effect of herbal acupuncture on ankylosing spondylitis and its evaluation of functional scale. *J Korean Acupunct Moxib Soc* 2002;19:234-246. [in Korean].
- [7] Sun TC, Jang HJ, Sun JK. A case Report of Chengsim Yeunja-Tang for Ankylosing Spondylitis associated with Severe Ulcerative Colitis. *Korean J Intern Med* 2005;26:685-691. [in Korean].
- [8] You YQ, Chen CX, Xu CC, Li ZQ, Cai MM, Liu LQ. Clinical Observation on the Treatment of Ankylosing Spondylitis with Sacroiliac Joint Acupotomy. *Rheum Arthritis* 2016;5:14-18. [in Chinese].
- [9] Gwak JI, Suh SY. The Assessment Tools in Palliative Medicine. *Korean J Hosp Palliat Care* 2009;12:177-193. [in Korean].
- [10] Calin A, Garrett S, Whitelock H, Kennedy LG, O'Hea J, Mallorie P et al. A new approach to defining functional ability in ankylosing spondylitis: The development of the Bath Ankylosing Spondylitis Functional Index. *J Rheumatol* 1994;21:2281-2285.
- [11] Garrett S, Jenkinson T, Kennedy LG, Whitelock H, Gaisford P, Calin A. A new approach to defining disease status in ankylosing spondylitis: The Bath Ankylosing Spondylitis Disease Activity Index. *J Rheumatol* 1994;21:2286-2291.
- [12] Daltroy LH, Larson MG, Roberts NW, Liang MH. A modification of the Health Assessment Questionnaire for the spondyloarthropathies. *J Rheumatol* 1990;17:946-950.
- [13] Bae SC, Cook EF, Kim SY. Psychometric evaluation of a Korean Health Assessment Questionnaire for clinical research. *J Rheumatol* 1998;25:1975-1979.
- [14] Choi SJ, Park MH. HLA-B27 frequency in Korean patients with ankylosing spondylitis. *Seoul J Med* 1987;28:247-250.
- [15] Yoo MC, Lee SE, Kim KT, Lee HK, Cho JH. Clinical and Radiological Features of Ankylosing Spondylitis. *J Korean Soc Spine Surg* 1995;2:72-80. [in Korean].
- [16] Suk KS, Kim KT, Kim JM, Chung KH. Significance of chin-brow Vertical Angle in Correction of Kyphotic Deformity of Ankylosing Spondylitis Patients. *J Korean Soc Spine Surg* 2002;9:115-120. [in Korean].
- [17] Yoon SH, Jeong SY, Kwon CY, Jo HG, Kim YI. A Proposal for Standardization of Acupotomy Terms and Definition Among Korean Researchers. *J Korean Med* 2018;39:13-28. [in Korean].
- [18] Meenan RF, Mason JH, Anderson JJ, Guccione AA, Kazis LE. AIMS2. The content and properties of a revised and expanded Arthritis Impact Measurement Scales Health Status Questionnaire. *Arthritis Rheum* 1992;35:1-10.
- [19] Dougados M, Gueguen A, Nakache JP, Nguyen M, Mery C, Amor B. Evaluation of a functional index and an articular index in ankylosing spondylitis. *J Rheumatol* 1988;15:302-307.
- [20] Spiegel JS, Leake B, Spiegel TM, Paulus HE, Kane RL, Ward NB et al. What are we measuring? An examination of self-reported functional status measures. *Arthritis Rheumatol* 1988;31:721-728.

## Appendix A

|   |  |
|---|--|
| Patient number:<br>Name:<br>Age:<br>Gender: M / F<br>Dep.:<br>Ward:<br>Date of Admission:   | <h3>Patient Information and Consent Form</h3>  |
|   | <div style="display: flex; justify-content: space-around; width: 100%;"> <span>Doctor: _____</span> <span>Signature: _____</span> </div> |
| <p>▪ <b>What is Acupotomy therapy?</b><br/>         Acupotomy therapy is the Oriental therapy peeling deep inside the lesions, using a bladed needle which has a thick flat-head and cylindrical body. Its purpose is to resolve chronic soft tissue injury and adhesion, recovering kinetic state. It is an efficient therapy for chronic accumulated injury.</p> <p>▪ <b>Procedure method</b><br/>         We use a specialized Acupotomy targeting to inner core muscles where tenderness appears.</p> <p>▪ <b>Alternative treatment</b><br/>         We can substitute general acupuncture and pharmacopuncture treatment for Acupotomy.</p> <p>▪ <b>Expected results without Acupotomy</b><br/>         Recovery from disease could be delayed.</p> <p>▪ <b>Possible side effects and precautions</b><br/>         Though we sterilize a needle and Acupotomy site directly, inflammation may possibly occur according to patient's immunity. From anesthetic, side effects including shock, malignant hyperthermia, convulsion, vomiting, dizziness, or allergic response can appear. On the day of the treatment, DO NO STIMULATE the Acupotomy sites by washing, taking a bath, or drinking. You are recommended to AVOID EXCESSIVE MOVEMENT for 3 days after treatment. You have to BE CAREFUL OF INFECTION on the Acupotomy sites, where sterilized gauze will be applied. This treatment has more possibility of infection than general acupuncture, and side effects including palpitation, dizziness, and hypotension may occur after treatment.</p> <p>▪ <b>Please check if you are included</b></p> <p><input type="checkbox"/> You have central nervous system diseases</p> <p><input type="checkbox"/> You have possibility of pregnancy</p> <p><input type="checkbox"/> You have severe hypertension</p> <p><input type="checkbox"/> You are taking antithrombotic drugs like Warfarin, Aspirin and else, OR you are suffering hemostatic disorder.</p> <p><input type="checkbox"/> You have any surgery history or you are currently receiving treatment ( Name of Disease : )</p> |  |
| <p><b>I received sufficient explanation about the Acupotomy treatment, and fully understand causable complications (inflammation, palpitation, dizziness, or hypotension) with Acupotomy. I agree to this consent and entrust the treatment to medical attendant.</b></p>   |  |
| <div style="background-color: #e0e0e0; padding: 5px; margin-bottom: 10px;"> <p>▪ Dates : _____, 2019</p> <p>▪ Patient : _____      ▪ Signature : _____</p> <p>▪ Substitute (Relation with patient : ) : _____      ▪ Signature : _____</p> </div> <p>-&gt; For: <input type="checkbox"/> The patient could not comprehend this form due to somatopsychic disorder.</p> <p><input type="checkbox"/> The patient is underage.</p> <p><input type="checkbox"/> It is obvious that this explanation could adversely affect the patient's condition.</p> <p><input type="checkbox"/> The patient personally delegates right to consent to specific person.</p> <p><input type="checkbox"/> Others( _____ )</p>   |  |

**Appendix B**

**Bath Ankylosing Spondylitis Functional Index (BASFI)**

Date \_\_\_\_\_ Patient Name \_\_\_\_\_

Please draw a mark on each line below to indicate your ability with each of the following activities, during the past week:

|   |                       |
|---|-----------------------|
| 1. Putting on your socks or tights without help or aids (e.g. sock aids)?                     | EASY _____ IMPOSSIBLE |
|   | 0 _____ 10            |
| 2. Bending forward from the waist to pick up a pen from the floor without an aid?             | EASY _____ IMPOSSIBLE |
|   | 0 _____ 10            |
| 3. Reaching up to a high shelf without help or aids (e.g. helping hand)?                      | EASY _____ IMPOSSIBLE |
|   | 0 _____ 10            |
| 4. Getting up out of an armless dining room chair without using your hands or any other help? | EASY _____ IMPOSSIBLE |
|   | 0 _____ 10            |
| 5. Getting up off the floor without any help from lying on your back?                         | EASY _____ IMPOSSIBLE |
|   | 0 _____ 10            |
| 6. Standing unsupported for 10 minutes without discomfort?                                    | EASY _____ IMPOSSIBLE |
|   | 0 _____ 10            |
| 7. Climbing 12-15 steps without using a handrail or walking aid (one foot on each step)?      | EASY _____ IMPOSSIBLE |
|   | 0 _____ 10            |
| 8. Looking over your shoulder without turning your body?                                      | EASY _____ IMPOSSIBLE |
|   | 0 _____ 10            |
| 9. Doing physically demanding activities (e.g. physiotherapy exercises, gardening or sports)? | EASY _____ IMPOSSIBLE |
|   | 0 _____ 10            |
| 10. Doing a full day's activities whether it be at home or work?                              | EASY _____ IMPOSSIBLE |
|   | 0 _____ 10            |



**Appendix C**

**The Bath Ankylosing Spondylitis Disease Activity Index (BASDAI)**

Date \_\_\_\_\_ Patient Name \_\_\_\_\_

Please place a mark on each line below to indicate your answer to each question relating to the past week

|  |
|--|
| 1. How would you describe the overall level of fatigue/tiredness you have experienced?<br>NONE _____ VERY SEVERE                             |
| 2. How would you describe the overall level of AS neck, back or hip pain you have had?<br>NONE _____ VERY SEVERE                             |
| 3. How would you describe the overall level of pain/swelling in joints other than neck, back, hips you have had?<br>NONE _____ VERY SEVERE   |
| 4. How would you describe the overall level of discomfort you have had from any areas tender to touch or pressure?<br>NONE _____ VERY SEVERE |
| 5. How would you describe the overall level of morning stiffness you have had from the time you wake up?<br>NONE _____ VERY SEVERE           |
| 6. How long does your morning stiffness last from the time you wake up?<br><br>_____<br>0 hrs      ½      1      1½      2 or more hours     |

**Appendix D**

**Questions added to the health assessment questionnaire (HAQ)**

Date \_\_\_\_\_ Patient Name \_\_\_\_\_

How much stiffness have you had because of your illness in the past week? Place a mark on the line to indicate the severity of the stiffness

| Activities   | (0)<br>Without ANY<br>Difficulty | (1)<br>With SOME<br>Difficulty | (2)<br>With MUCH<br>Difficulty | (3)<br>Unable<br>To Do |
|--|----------------------------------|--------------------------------|--------------------------------|------------------------|
| Are you able to carry heavy package such as grocery bags?                          | _____                            | _____                          | _____                          | _____                  |
| Are you able to sit for long periods of time, such as at work?                     | _____                            | _____                          | _____                          | _____                  |
| Are you able to work at a flat-topped table or desk?                               | _____                            | _____                          | _____                          | _____                  |
| Driving a car<br>(Check here _____ if you DO NOT have a driver's license or a car) |                                  |                                |                                |                        |
| Are you able to look in the rear-view mirror?                                      | _____                            | _____                          | _____                          | _____                  |
| Are you able to turn your head to drive in reverse?                                | _____                            | _____                          | _____                          | _____                  |

**Appendix E****Korean Health Assessment Questionnaire (K-HAQ)**

Date \_\_\_\_\_

Patient Name \_\_\_\_\_

1. Can you wear your clothes? (including tying shoes and buttoning).  
There is no difficulty at all. (0) / have some difficulties.(1) / have a lot of difficulties.(2) / Can't do it.(3)
2. Can you wash your hair?  
There is no difficulty at all. (0) / have some difficulties.(1) / have a lot of difficulties.(2) / Can't do it.(3)
3. Can you stand up straight from the armless chair?  
There is no difficulty at all. (0) / have some difficulties.(1) / have a lot of difficulties.(2) / Can't do it.(3)
4. Can you lie down on bed, and get up?  
There is no difficulty at all. (0) / have some difficulties.(1) / have a lot of difficulties.(2) / Can't do it.(3)
5. Can you eat with chopsticks?  
There is no difficulty at all. (0) / have some difficulties.(1) / have a lot of difficulties.(2) / Can't do it.(3)
6. Can you drink a glass full of water?  
There is no difficulty at all. (0) / have some difficulties.(1) / have a lot of difficulties.(2) / Can't do it.(3)
7. Can you open a new milk carton?  
There is no difficulty at all. (0) / have some difficulties.(1) / have a lot of difficulties.(2) / Can't do it.(3)
8. Can you walk on a flat road?  
There is no difficulty at all. (0) / have some difficulties.(1) / have a lot of difficulties.(2) / Can't do it.(3)
9. Can you walk up the five steps?  
There is no difficulty at all. (0) / have some difficulties.(1) / have a lot of difficulties.(2) / Can't do it.(3)
10. Can you wash your whole body, clean your water?  
There is no difficulty at all. (0) / have some difficulties.(1) / have a lot of difficulties.(2) / Can't do it.(3)
11. Can you take a bath in the bathtub?  
There is no difficulty at all. (0) / have some difficulties.(1) / have a lot of difficulties.(2) / Can't do it.(3)
12. Can you sit on the toilet and get up?  
There is no difficulty at all. (0) / have some difficulties.(1) / have a lot of difficulties.(2) / Can't do it.(3)
13. Can you pick up a 1.8-liter soy sauce bottle right above your head?  
There is no difficulty at all. (0) / have some difficulties.(1) / have a lot of difficulties.(2) / Can't do it.(3)
14. Can you bend over and pick up the clothes on the floor?  
There is no difficulty at all. (0) / have some difficulties.(1) / have a lot of difficulties.(2) / Can't do it.(3)
15. Can you open the car door?  
There is no difficulty at all. (0) / have some difficulties.(1) / have a lot of difficulties.(2) / Can't do it.(3)
16. Can you open a bottle cap that I've opened before?  
There is no difficulty at all. (0) / have some difficulties.(1) / have a lot of difficulties.(2) / Can't do it.(3)
17. Can you open and lock the faucet?  
There is no difficulty at all. (0) / have some difficulties.(1) / have a lot of difficulties.(2) / Can't do it.(3)
18. Can you buy things at the market?  
There is no difficulty at all. (0) / have some difficulties.(1) / have a lot of difficulties.(2) / Can't do it.(3)
19. Can you ride in a car and get off?  
There is no difficulty at all. (0) / have some difficulties.(1) / have a lot of difficulties.(2) / Can't do it.(3)
20. Can you do household chores such as cleaning floors?  
There is no difficulty at all. (0) / have some difficulties.(1) / have a lot of difficulties.(2) / Can't do it.(3)