

Case Report

KM-based Treatment of Viral Hepatitis A accompanied with Pancreatitis: A case report

Chang-Gue Son

Liver and Immunology Research Center, Oriental Medical College in Daejeon University

Objectives: Hepatitis A is a typical acute hepatitis caused by hepatovirus, and then most patients recover easily without progression to chronic condition. However, certain cases have the risk of severe symptoms or even death. This case report presented a hepatitis A accompanied with pancreatitis, which had been completely recovered in a Korean medicine hospital.

Case presentation: A 38-year woman had felt the malaise, mild chilling, muscle pain and abdominal discomfort for 10 days, which led her visit doctors and took anti-pyretic analgesics and digestants. The symptoms, especially epigastric pain and fatigue, became worse, and then she hospitalized in a Korean medicine hospital. Based on the drastic elevations of hepatic enzymes (aspartate transaminase 1,604 IU/L and alanine transaminase 2,825IU/L) with an anti-HAV IgM positive, she was diagnosed with hepatitis A. After bed rest and herbal drug treatment (CGX and Innae-Tang) for 5 days, the laboratory abnormalities and subjective symptoms had been improved gradually, except the upper gastric discomfort and pain. Those symptoms had anticipated the comorbidity with HAV-induced pancreatitis, supported by the high level of serum lipase release. Another 5-day hospitalized treatment improved all subjective symptoms and then the laboratory results were completely normalized including detection of anti-HAV IgG within 15 days after discharge.

Conclusion: This study presented a typical hepatitis A accompanied with pancreatitis, which should be considered in diagnosis and management of hepatitis A.

Key Words : Hepatitis A, Hepatitis A virus, Pancreatitis, Korean medicine

Introduction

Among several viruses infecting liver, hepatitis A virus (HAV) is a typical agent that causes acute hepatitis. Hepatitis A occurs through a fecal-oral transmission fashion; thus, hygiene and socio-economic status is an important factor in incidence of hepatitis A¹⁾. Along with the economic development, the incidence rate of hepatitis A is declining in most countries

including South Korea²⁾.

HAV usually induces asymptomatic infection in young children age, and hepatitis A vaccination confers lifelong immunity. Owing to improvement of public health facility and vaccination program, the incidence of symptomatic acute hepatitis A has been minimized in South Korea³⁾.

Recently, however there were nationwide outbreaks of acute hepatitis A in South Korea, as over 50,000 patients in 2009 and roughly 20,000

• Received : 11 Februar 2020

• Revised : 9 October 2020

• Accepted : 18 November 2020

• Correspondence to : Chang-Gue Son

Liver and Immunology Research Center, Dunsan Oriental Hospital of Daejeon University

35353 Daedukdae-ro 176 bun-gil 75, Seo-gu, Daejeon, Republic of Korea

Tel : +82-42-484-6484, Fax : +82-42-470-9005, E-mail : ckson@dju.ac.kr

in 2019. Then, the major patients of hepatitis A are belonged to young adult generation, especially 20s and 30s⁴). This reason is suggested that those generations has the lowest rate of anti-HAV seroprevalence, below 20% comparing to 70% in other generations⁵). The hygiene improvement and low inoculation against HAV led to the high susceptibility in young adults. The illness severity of HAV infection increases with age, accordingly adult' hepatitis A can be medical problem⁶). The mortality also increases with age likely 0.1% among children < 15 year, 0.3% in 15-39 year, 1.8-5.4% in aged group > 50 year^{7,8}). In addition, comorbidity of acute pancreatitis in patient with hepatitis A can bring to the severe symptom and fulminant hepatitis⁹).

On the other hand, many cases of hepatitis A could be misdiagnosed as a common cold or gastrointestinal disorder. Furthermore, no availability of chemical/immunological diagnostic tools leads to the diagnostic difficulty of this disease in Korean Medicine (KM) clinics. To share the updated knowledge for hepatitis A, this study presents a severe case of hepatitis A accompanied with pancreatitis in adult woman.

Case presentation

1. Characters of patient and diagnosis

A 38-year woman had felt the malaise, mild chilling, muscle pain and abdominal discomfort for 10 days, which led her took anti-pyretic analgesics and digestants prescribed by doctors from a Western clinic and a KM clinic. The symptoms, especially epigastric pain and fatigue, became worse, and then she hospitalized with an anticipation of HAV infection in a Korean medicine hospital. Based on the drastic elevations

of hepatic enzymes (AST 1,604 IU/L and ALT 2,825IU/L) and an anti-HAV IgM positive, she was diagnosed with hepatitis A. In an x-ray examination for abdomen, accumulated gas in colon was shown (Fig. 1A). She had no known personal or family history of liver disease, atypical travel within two months, use of alcohol or eating contaminated food or water. Physical examination indicated a strong tenderness in epigastric and right flank areas and strong yellowish-color urination. She had mild-red tongue with moderate fur and floating pulse. His symptom differentiation was the “*Accumulation of damp heat in liver and stomach* (肝胃濕熱蘊結)”.

2. Treatment and clinical outcome

After admission, bed rest was guided and herbal drugs (*CGX* and *Innae-Tang*, Table 1) and acupuncture (twice daily mainly at LI4, LR3, PC6 and SP4) were given to the patient. On 3rd day in hospital, the laboratory abnormalities rapidly decreased by half levels of hospitalized day (AST 603 IU/L and ALT 1, 593 IU/L). Most of subjective symptoms also had been improved gradually, however the bilirubin level slightly elevated from 3.8 mg/dl to 4.2 mg/dl with yellowish change of sclera. In particular, the patient complained upper gastric discomfort and pain continually with slight improvement. These symptoms anticipated the HAV-induced pancreatitis, and her serum lipase and amylase were checked along with abdominal ultrasonography on hospital day 5. The abnormally high level of lipase was detected in blood test. Although the decreased hepatic parenchymal echo, mild splenomegaly, and thickened wall with small polyp in gall bladder were found, no specific change of pancreas

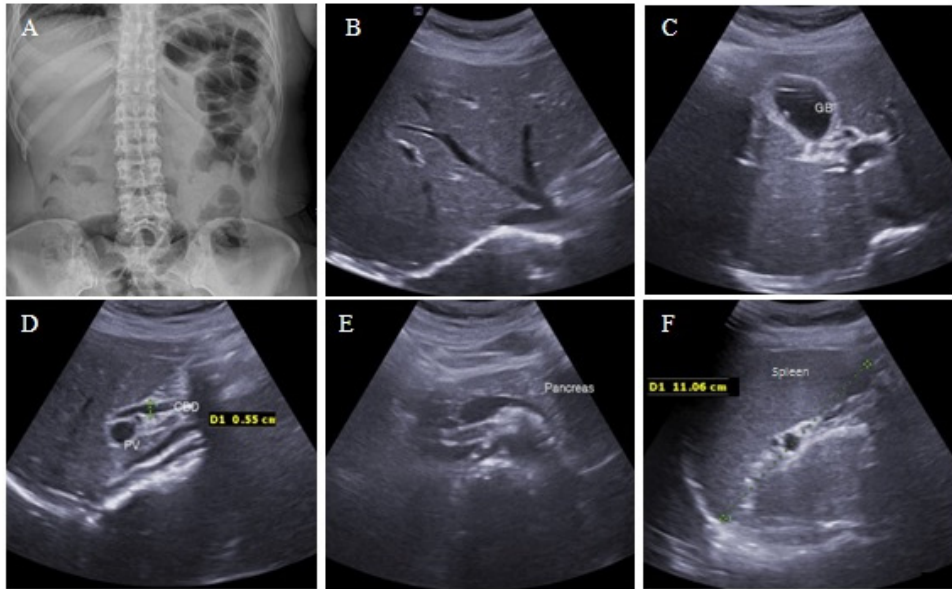


Fig. 1. X-ray examination and Ultrasonography for abdomen.

Simple X-ray shows gas (A), and ultrasonography findings (B to F) indicate the decreased hepatic parenchymal echo, thickened wall with small polyp in gall bladder and mild splenomegaly.

was observed in abdominal ultrasonography (Fig. 1B to F). On 10th hospital day, she was discharged with improvement of all subjective symptoms and the laboratory results (AST 106 IU/L, ALT 472 IU/L) and total bilirubin 1.4 mg/dl). The blood tests including lipase level were completely normalized with the development of anti-HAV IgG in 15 days after discharge (Fig. 2). During hospitalization, no specific conventional drug was used, except supplication of normal saline mixed with vitamin C and B1.

Discussion and Conclusion

HAV has an incubation period about 25 to 30 days, and then individual complains malaise, loss of appetite, fever, diarrhea, nausea, or abdominal discomfort. The symptom-presenting period is generally the peak point of hepatic enzymes, after that, jaundice distinctly appears. KM has been described hepatitis A as “Jaundice (黄疸)” which is presented in approximately 70% of patients among older children and adults¹⁰⁾. The

Table 1. Composition of CGX and Innae-Tang

Name of drug	Herbal name (gram for dose)
CGX*	<i>Artemisia capillaris</i> Herba (5), <i>Trionycis</i> Carapax (5), <i>Raphani Semen</i> (5), <i>Atractylodis</i> MacrocephalaeRhizoma (3), <i>Poriacocos</i> (3), <i>Alismatis</i> Rhizama (3), <i>Atractylodis</i> Fructus (2), <i>Glycyrrhizae Radix</i> (1), <i>Helenii Radix</i> (1)
Innae-Tang#	<i>Artemisia capillaris</i> Herba (50), <i>Raphani Semen</i> (20), <i>Glycyrrhizae Radix</i> (10)

* Dose is for a day/adult while #dose for 3 days as many times likely tea.

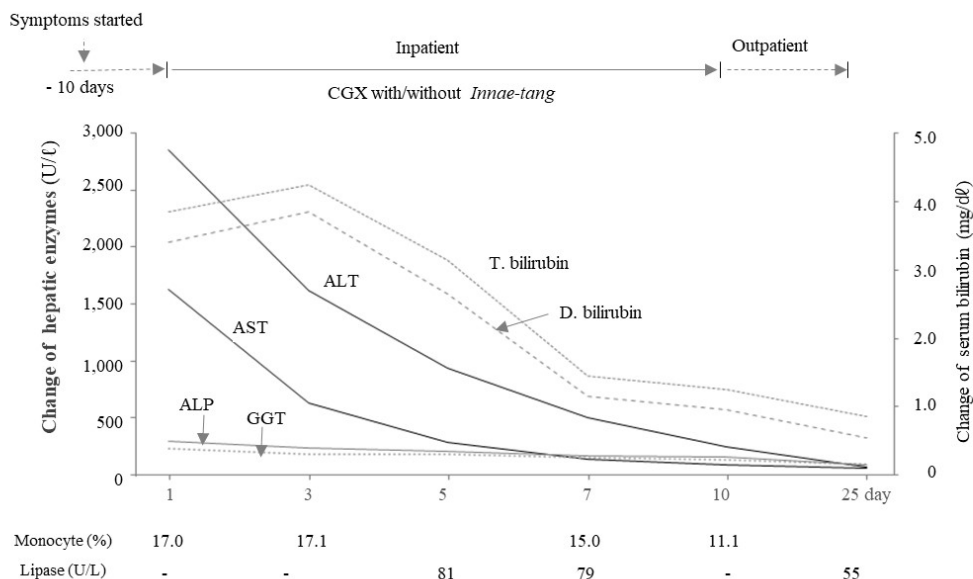


Fig. 2. Summary for changes of laboratory results and treatment courses.

The upper limits are follow: 40 IU/L for AST and ALT, 64 IU/L for γ -GTP, 120 IU/L for ALP, 1.2 mg/dL for total bilirubin, 0.3 mg/dL for direct bilirubin, 10% for monocyte and lipase 60 U/L, respectively.

present case might pass the peak point of hepatic injury when she hospitalized, thus the hepatic enzymes were rapidly lowered just after admission.

The specific treatment of hepatitis A is not necessary because most of hepatitis A normally resolved spontaneously within 2 months without chronic sequelae. Most important is the avoidance of unnecessary medications, potentially hepatotoxic drugs such as acetaminophen. The use of acetaminophen was known to affect the severity of acute hepatitis A¹¹⁾. The clinical symptoms of hepatitis A overlap with many other gastrointestinal and febrile conditions¹²⁾. Accordingly, hepatitis A patients are often misdiagnosed until their skin starts to be discolored. The current patient felt the 'flu-like' and indigestive symptoms at initial periods. Doctors in both Western clinic and KM clinic prescribed anti-pyretic analgesics and digestants for her before diagnosis as hepatitis A

in a KM hospital.

The patient of this case report had complained an unusual level of epigastric pain and tenderness even after hepatic enzymes and other subjective discomforts rapidly improved. It might be resulted from the HAV-induced pancreatitis. Although abdominal ultrasonography didn't show any typical feature of pancreatitis such as volume change of pancreas region, the serum lipase, a main parameter for pancreatitis, was elevated abnormally. The reason of non-drastring elevation of lipase level might be the late time point of the first test after certain improvement already. One systematic review study estimated 0.1% of frequency of acute pancreatitis by HAV infection¹³⁾. As shown in this case report, HAV-related acute pancreatitis could induce the severe abdominal pain, and furthermore thickened wall in gall bladder^{14,15)}. This patient showed an elevated

ratio of monocyte by 17.1% in peripheral blood counts too (Fig. 2). This can be explained by the fact that HAV suppresses monocyte-to-macrophage maturation¹⁶).

Although > 99% of hepatitis A recovered completely, 2~5% of clinical cases showed the relapse of symptom associated with re-elevation of ALT and re-detection of HAV RNA in blood several weeks later¹⁷). Hepatitis A can cause fulminant hepatitis with range of 0.015 ~ 0.5%, which has a high fatality. Among 300,000 cases of HAV infection in an outbreak of Shanghai China in 1988, 47 deaths were reported¹⁸). However, most of patients were young and healthy adults in this outbreak period, and then the mortality can be increased in cases of aged or persons having other diseases. The present case discharged on 10th hospital day, and the complete recovery was confirmed on 15 days after discharge (Fig. 2). This patient had been prescribed with herbal drugs, *CGX* and *Innae-Tang* (茵萊湯). *CGX* is a standardized herbal syrup with hepatoprotective effects against acute and chronic liver injury^{19,20}). *Innae-Tang* is composed of three herbs (*Artemisia capillaris* Herba, *Raphani Semen*, *Glycyrrhizae Radix*) to treat acute hepatic inflammation with jaundice, a condition of “*Accumulation of damp heat* (濕熱蘊結)” according to the KM-pharmacological theory. To facilitate digestion and help flow of *Qi* and *blood*, acupuncture treatment (LI4, LR3, PC6, SP4) also had been given to the patient. How much the KM-based treatments contributed to the recovery of this case comparing to Western-based common management is uncertain, It should be however notice that most cases of acute pancreatitis due to hepatitis viruses is associated with acute liver failure, having a chance of poor

prognosis⁹).

In summary, this study would be helpful to provide the practical information to care the patient with hepatitis A in KM field, in particular for differential diagnosis between hepatitis A accompanied with acute pancreatitis and other diseases such as gastrointestinal disorders.

Ethical statement

This case report had been approved by the institutional review board of Daejeon Korean Medicine Hospital of Daejeon University (#DJDSKH-20-E-27).

References

1. Chung GE, Yim JY, Kim D, Lim SH, Park MJ, Kim YS, et al. Seroprevalence of hepatitis a and associated socioeconomic factors in young healthy korean adults. Gut Liver. 2011;5(1):88-92.
2. Jacobsen KH, Koopman JS. Declining hepatitis A seroprevalence: a global review and analysis. Epidemiol Infect. 2004;132(6): 1005-22.
3. Seo JY, Seo JH, Kim MH, Ki M, Park HS, Choi BY. Pattern of hepatitis A incidence according to area characteristics using national health insurance data. J Prev Med Public Health. 2012;45(3):164-73.
4. Kang SH, Kim MY, Baik SK. Perspectives on Acute Hepatitis A Control in Korea. J Korean Med Sci. 2019;34(36):e230.
5. Lee H1, Cho HK, Kim JH, Kim KH. Seroepidemiology of hepatitis A in Korea: changes over the past 30 years. J Korean Med Sci. 2011;26(6):791-6.

6. Zamir C, Rishpon S, Zamir D, Leventhal A, Rimon N, Ben-Porath E. Control of a community-wide outbreak of hepatitis A by mass vaccination with inactivated hepatitis A vaccine. *Eur J Clin Microbiol Infect Dis* 2001;20:185-7.
7. Willner IR, Uhl MD, Howard SC, Williams EQ, Riely CA, Waters B. Serious hepatitis A: an analysis of patients hospitalized during an urban epidemic in the United States. *Ann Intern Med*. 1998;128:111-4.
8. Krugman S, Giles JP. Viral hepatitis. New light on an old disease. *JAMA*. 1970;212:1019-29.
9. Jain P, Nijhawan S, Rai RR, Nepalia S, Mathur A. Acute pancreatitis in acute viral hepatitis. *World J Gastroenterol*. 2007;13(43):5741-4.
10. WHO, available at <https://www.who.int/news-room/fact-sheets/detail/hepatitis-a>.
11. Yaghi C, Honein K, Boujaoude J, Slim R, Moucari R, Sayegh R. Influence of acetaminophen at therapeutic doses on surrogate markers of severity of acute viral hepatitis. *Gastroenterol Clin Biol*. 2006;30(5):763-8.
12. Matheny SC, Kingery JE. Hepatitis A. *Am Fam Physician*. 2012;86(11):1027-34; quiz 1010-2.
13. Haffar S, Bazerbachi F, Prokop L, Watt KD, Murad MH, Chari ST. Frequency and prognosis of acute pancreatitis associated with fulminant or non-fulminant acute hepatitis A: A systematic review. *Pancreatology*. 2017;17(2):166-75.
14. Ertekin V, Selimoglu MA, Konak M, Orbak Z. Association of hepatitis a and acute pancreatitis presenting as acute abdomen. *Pancreas*. 2005;31(3):298-9.
15. Basaranoglu M, Balci NC, Klör HU. Gallbladder sludge and acute pancreatitis induced by acute hepatitis A. *Pancreatology*. 2006;6(1-2):141-4.
16. Wünschmann S, Becker B, Vallbracht A. Hepatitis A virus suppresses monocyte-to-macrophage maturation in vitro. *J Virol*. 2002;76(9):4350-6.
17. Glikson M, Galun E, Oren R, Tur-Kaspa R, Shouval D. Relapsing hepatitis A. Review of 14 cases and literature survey. *Medicine*. 1992;71:14-23.
18. Cooksley WG. What did we learn from the Shanghai hepatitis A epidemic? *J Viral Hepat* 2000;7:1-3.
19. Hu XP, Shin JW, Wang JH, Cho JH, Son JY, Cho CK, et al. Antioxidative and hepatoprotective effect of CGX, an herbal medicine, against toxic acute injury in mice. *J Ethnopharmacol*. 2008;120(1):51-5.
20. Kwak KG, Wang JH, Shin JW, Lee DS, Son CG. A traditional formula, Chunggan extract, attenuates thioacetamide-induced hepatofibrosis via GSH system in rats. *Hum Exp Toxicol*. 2011;30(9):1322-32.

ORCID

Chang-Gue Son <https://orcid.org/0000-0003-4876-0167>