

Case Report

pISSN 2466-1384 · eISSN 2466-1392
Korean J Vet Res 2021;61(4):e35
<https://doi.org/10.14405/kjvr.2021.61.e35>

*Corresponding author:

Min Jang
Department of Veterinary Surgery, College of
Veterinary Medicine, Kyungpook National
University, 80 Daehak-ro, Buk-gu, Daegu
41566, Korea
Tel: +82-53-950-7795
Fax: +82-53-950-5994
E-mail: jangmin@knu.ac.kr

ORCID:
<https://orcid.org/0000-0002-2188-1906>

Conflict of interest:
The authors declare no conflict of interest.

Received: August 4, 2021
Revised: October 14, 2021
Accepted: November 9, 2021

Balance impairment caused by diazepam in 2 dogs with vestibular disease: case reports

Hyunseok Kim^{1,2}, Won-gyun Son¹, Inhyung Lee¹, Min Jang^{3,*}

¹Department of Veterinary Clinical Sciences, College of Veterinary Medicine, Seoul National University, Seoul 08826, Korea

²The Ian Animal Medical Center, Seoul 06014, Korea

³Department of Veterinary Surgery, College of Veterinary Medicine, Kyungpook National University, Daegu 41566, Korea

Following intravenous (IV) administration of diazepam as a preanesthetic agent, sudden balance impairment, such as falling, leaning, and rolling, was identified in 2 canine cases. The 2 dogs were anesthetized for brain magnetic resonance scan to diagnose about a history of head tilt. After end of the diagnostic procedures, during the anesthetic recovery period, balance impairment was also observed. However, the symptoms gradually ceased by IV administration of flumazenil. These 2 canine cases indicated that diazepam premedication was responsible for the acute balance impairment.

Keywords: diazepam; falling; flumazenil; leaning; rolling

The vestibular system generates neurological signals containing information about the forces of gravity and movement [1]. Based on these signals, the brain maintains balance and coordinates movements [1]. Vestibular system disease induces signs including nystagmus, head tilt, leaning, falling, and rolling [2]. Magnetic resonance imaging (MRI) is considered a valuable diagnostic tool for vestibular disease [2]. In veterinary medicine, general anesthesia is required for MRI scan, and diazepam is one of the options of premedication for anesthesia in sick patients to reduce the dose of general anesthetics and minimize hemodynamic changes [3]. It is suggested that benzodiazepine may impair postural control in humans medicine [4], however only balance impairment cases after midazolam injection were reported in veterinary medicine [5,6]. Here, the authors present 2 canine cases of sudden onset of leaning, falling, and rolling after diazepam premedication.

Case 1. An 11-year-old 3.1 kg castrated male Maltese suffering from acute left head tilt was referred to the diagnostic imaging center for MRI (Magnetom Essenza; Siemens Healthcare, Germany) scan of the brain. The owner noticed that the symptom had begun 2 days earlier. There were no abnormalities on complete blood count, serum chemistry, and thoracic radiography. The dog was bright, alert, and responsive. The neurological examination revealed a left-sided head tilt and horizontal nystagmus (fast phase to the right), and there were no detectable proprioceptive deficits and paresis. The heart rate (HR) of the patient was 102 bpm, and the respiratory rate (RR) was 30 rpm. The systolic blood pressure (BP) measured by Doppler (811-B; Parks Medical Electronics, USA) ultrasonic method was 136 mmHg. The dog was premedicated with intravenous (IV) 0.2 mg/kg diazepam (Diazepam; Samjin Pharm, South Korea). Immediately following the injection, an abrupt balance impairment characterized by leaning, falling, and rolling

was noticed. For additional premedication, 0.2 mg/kg butorphanol (Butorphanol; Myungmoon Pharm, South Korea) IV was injected, and anesthesia was induced with propofol (4 mg/kg IV, Provive 1%; Myungmoon Pharm). After the induction of anesthesia, the dog's leaning, falling, and rolling stopped. General anesthesia was maintained with sevoflurane (Sevoflurane; Piramal Critical Care Inc., USA) in 1.5 L/min oxygen using a semi-closed circle system (Royal 77; Royal Medical, South Korea). Throughout the peri-anesthetic period, the dog was administered with normal saline (0.9% NaCl, 0.9% NS; Dai Han Pharm, South Korea) at a rate of 5 mL/kg/h IV. Multiparameter patient monitor (Datex Ohmeda N-MRI2-00; G.E. Healthcare, Finland) was used to monitor the vital parameters of the dog, and during MRI scan, the initial readings were HR of 112 bpm, oscillometric mean BP of 102 mmHg, RR of 6 rpm, end-tidal carbon dioxide partial pressure (Et CO₂) of 45 mmHg, pulse oximetry (SpO₂) of 97%, and end-tidal sevoflurane concentration (Et Sevo) of 1.5%. The MRI scan was performed without any complications. After all MRI scan procedures, the vaporizer was turned off. Fifty-seven minutes after the diazepam premedication, the dog was extubated. Sixteen minutes after extubation, the leaning, falling, and rolling were observed again, and the dog was unable to maintain a standing position. At that time, flumazenil (0.01 mg/kg IV; Flunil; Bukwang Pharm, South Korea) was injected. Within 5 minutes of flumazenil administration, balance impairment gradually ceased, and the dog was able to maintain an upright posture. No balance impairment was found on follow-up examination after flumazenil administration. MR images showed high T2 and T1 intensities in the left tympanic bulla (Fig. 1). Based on the MRI results, the management of otitis media and interna was performed by the primary care veterinarian.

Case 2. A 14-year-old spayed female mongrel dog suffering

from acute left head tilt was referred to the diagnostic imaging center for brain MRI scan. The client reported that the head tilt had begun 3 days earlier. The results of the complete blood count and serum chemistry were within reference ranges, and there were no abnormalities in thoracic radiography. The neurological examination revealed a left-sided head tilt, horizontal nystagmus (fast phase to the right), and left-sided circling. There were no obvious proprioceptive deficits and paresis. The physical examination showed that HR, RR, and systolic BP were 120 bpm, 42 rpm, and 140 mmHg, respectively. For premedication, the dog was administered with 0.2 mg/kg diazepam IV. Immediately after the administration, the dog began leaning, falling, and rolling. Additional premedication with 0.2 mg/kg butorphanol IV was performed, and general anesthesia was induced with propofol (4 mg/kg IV). After anesthetic induction, the dog's leaning, falling, and rolling ceased. Anesthesia was maintained with sevoflurane in 2 L/min oxygen. The dog was administered with isotonic saline (0.9% NaCl) at a rate of 5 mL/kg/h IV during the peri-anesthetic period. During MRI scan, the measured vital parameters were as follows: HR of 87 bpm, oscillometric mean BP of 65 mmHg, RR of 21 rpm, Et CO₂ of 47 mmHg, SpO₂ of 98%, and Et Sevo of 1.3%. The MRI scan was performed without any complications, and after the scan, a cerebrospinal fluid (CSF) tap was performed. After all procedures, the vaporizer was turned off. Sixty minutes after the diazepam premedication, the dog was extubated. During the anesthetic recovery period, leaning and falling were again observed, and the dog was administered with flumazenil (0.01 mg/kg IV). Within 5 minutes of the administration of the flumazenil, balance maintenance ability was recovered, and the dog could retain an upright posture. The MR images showed high T2 intensities in the right tympanic bulla (Fig. 2), and the

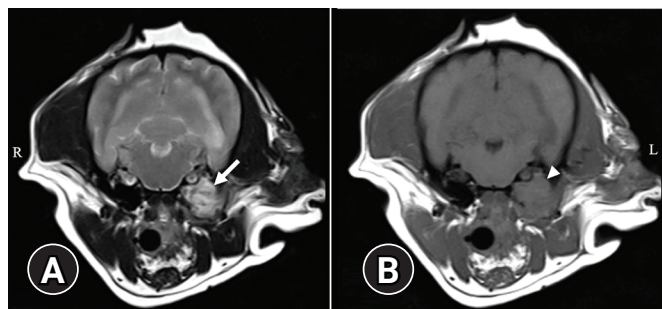


Fig. 1. (A) T2 and (B) T1 transverse magnetic resonance images. Hyper intense (white arrow) and isointense (white arrowhead) are identified in left tympanic bulla on T2 image and T1 image, respectively.

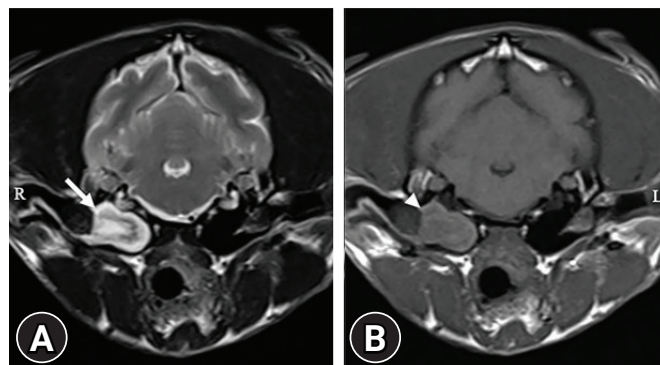


Fig. 2. (A) T2 and (B) T1 transverse magnetic resonance images. Hyper/hypo mixed intense (white arrow) and isointense (white arrowhead) are identified in right tympanic bulla on T2 image and T1 image, respectively.

CSF examination revealed no remarkable findings. Since the direction of the peripheral vestibular lesion was not matched with the clinical signs of the dog, geriatric vestibular syndrome was considered a priority. The management of idiopathic peripheral vestibular disease and right otitis media was performed by the primary care veterinarian.

In the 2 dogs of this case report, acute balance impairment including leaning, falling, and rolling, which were not observed before being referred to the center, occurred after the administration of diazepam. Additionally, the dogs suddenly lost the ability to maintain an upright posture although they were able to maintain their balance and walk before diazepam premedication. Hence, it is inferred that the main cause of the onset of the symptoms is the effect of diazepam. Diazepam is usually recommended as the treatment of vestibular dysfunction because the medicine decreases the resting activity of vestibular nuclei neurons [1]. The agent decreases the imbalance in vestibular nerve signal to the brain by suppressing vestibular tone of the contralateral normal vestibular system [1]. However, the presented cases showed that diazepam administration causes balance impairment.

Sedatives and anesthetics are known to influence balance control movement and vestibulo-ocular reflex [7-9]. There were canine case reports associated with only midazolam that demonstrated acute balance impairment in veterinary medicine [5,6], while it is documented that benzodiazepines, including diazepam, can affect postural control in human medicine [4]. The probable reason of benzodiazepine-induced balance impairment is presented to be the weak psychomotor functioning resulting from the effects of benzodiazepines on the central nervous system (CNS) [4]. Furthermore, the benzodiazepine effects on skeletal muscle contraction may also influence balance control [10].

Benzodiazepines, such as diazepam and midazolam, enhance the gamma-aminobutyric acid (GABA)_A receptor's affinity for GABA, which is an inhibitory neurotransmitter in CNS [3]. The results from the GABA action revealed that chloride conductance and hyperpolarization of postsynaptic cell membranes increase [3]. Diazepam has poor water solubility, and the elimination half-life following IV administration is approximately 3.2 hours in dogs [3]. In this report, since 2 dogs were recovered from general anesthesia within 1 hour from diazepam administration, diazepam would have affected during recovery periods. Flumazenil, which is a competitive benzodiazepine antagonist reverses the effects of benzodiazepines on the CNS [3]. In this case report, balance impairment was resolved by flumazenil administration and no balance impairment was found on fol-

low-up examination. This fact not only strongly suggests that the symptoms were caused by benzodiazepines but also makes it possible to recommend clinicians to consider flumazenil administration when balance impairment occurs after diazepam administration.

It is difficult to search for information about the effect of anesthetics on the vestibular system in canine vestibular disease patients. The methods for rapid and complete recovery, such as use of short-acting anesthetics and administration of low-dose dexmedetomidine to reduce general anesthetics' requirements, are suggested in only one reference [11].

Benzodiazepines and opioids are an acceptable choice for premedication in neurological patients to reduce induction and inhalation agent requirements with a minimal direct effect on CNS [12]. This case report is meaningful as it provides the reader with the required information about the possibility of sudden balance impairment occurrence on the administration of diazepam as a premedication for anesthesia in dogs with vestibular disease.

In conclusion, balance impairment, including leaning, falling, and rolling, can occur after diazepam premedication before and/or after general anesthesia in dogs with vestibular disease. The practitioners can consider antagonization of diazepam using flumazenil when such neurological signs, which are generally not expected, are observed.

Acknowledgments

This work was supported by the National Research Foundation of Korea (NRF) grant funded by the Korea government (Ministry of Science and ICT) (No. 2021R1G1A1013034).

ORCID

Hyunseok Kim, <https://orcid.org/0000-0003-4962-9830>

Won-gyun Son, <https://orcid.org/0000-0001-5431-3254>

Inhyung Lee, <https://orcid.org/0000-0002-0712-7165>

Min Jang, <https://orcid.org/0000-0002-2188-1906>

References

1. Thomas WB. Vestibular dysfunction. *Vet Clin North Am Small Anim Pract* 2000;30:227-249.
2. Rossmeisl JH Jr. Vestibular disease in dogs and cats. *Vet Clin North Am Small Anim Pract* 2010;40:81-100.
3. Rankin DC. Sedatives and Tranquilizers. In: Grimm KA, Lamont LA, Tranquilli WJ, Greene SA, Robertson SA, eds.

- Veterinary Anesthesia and Analgesia. 5th ed. pp. 196–206, Wiley-Blackwell, Ames, 2015.
- de Groot MH, van Campen JP, Moek MA, Tulner LR, Beijnen JH, Lamoth CJ. The effects of fall-risk-increasing drugs on postural control: a literature review. *Drugs Aging* 2013;30:901–920.
 - Jang M, Mann FA, Bukoski A, Dodam JR, Lee I. Effect of midazolam on vestibular signs in two geriatric dogs with vestibular disease. *J Am Anim Hosp Assoc* 2020;56:e56402.
 - Jang M, Shin CW, Choi S, Won S, Lee I. Anesthesia case of the month. *J Am Vet Med Assoc* 2018;253:279–282.
 - Cutson TM, Gray SL, Hughes MA, Carson SW, Hanlon JT. Effect of a single dose of diazepam on balance measures in older people. *J Am Geriatr Soc* 1997;45:435–440.
 - Padoan S, Korttila K, Magnusson M, Pyykkö I, Schalén L. Effect of intravenous diazepam and thiopental on voluntary saccades and pursuit eye movements. *Acta Otolaryngol* 1992;112:579–588.
 - Vouriot A, Gauchard GC, Chau N, Nadif R, Mur JM, Perrin PP. Chronic exposure to anesthetic gases affects balance control in operating room personnel. *Neurotoxicology* 2005;26:193–198.
 - Matsuura N. Muscle power during intravenous sedation. *Jpn Dent Sci Rev* 2017;53:125–133.
 - Leece EA. Neurological disease. In: Duke-Novakowski T, de Vries M, Seymour CJ, eds. *BSAVA Manual of Canine and Feline Anaesthesia and Analgesia*. 3rd ed. pp. 392–408, BSAVA, Gloucester, 2016.
 - Wendt-Hornickle E. Neurologic Disease. In: Snyder LBC, Johnson RA, eds. *Canine and Feline Anesthesia and Co-existing Disease*. 1st ed. pp. 71–81, Wiley-Blackwell, Ames, 2015.