

Anti-N-methyl-D-aspartate receptor encephalitis associated with ovarian teratoma in Korea: three case reports

Jisun Lee¹, Seongwoo Kang², Hye Jin Chang², Yong Hee Lee³, Joo-Hyuk Son⁴, Tae Wook Kong⁴, Suk-Joon Chang⁴, Kyung Joo Hwang², Miran Kim²

¹Department of Obstetrics and Gynecology, Kyungpook National University Hospital, School of Medicine, Kyungpook National University, Daegu, Korea

²Department of Obstetrics and Gynecology, Ajou University School of Medicine, Suwon, Korea

³Department of Pathology, Ajou University School of Medicine, Suwon, Korea

⁴Gynecologic Cancer Center and Department of Obstetrics and Gynecology, Ajou University School of Medicine, Suwon, Korea

Received: October 6, 2020

Revised: December 23, 2020

Accepted: December 29, 2020

Corresponding author:

Miran Kim, MD, PhD

Department of Obstetrics and Gynecology, Ajou University School of Medicine, 164 Worldcup-ro, Yeongtong-gu, Suwon 16499, Korea
Tel: +82-31-219-5250

Fax: +82-31-219-5245

E-mail: kmr5300@ajou.ac.kr

Anti-N-methyl-D-aspartate receptor (NMDAR) encephalitis is a severe autoimmune paraneoplastic syndrome associated with ovarian teratomas. Most patients develop neurologic symptoms, including psychosis, memory deficits, seizures, or abnormal movements, and experience abdominal pain related to ovarian neoplasm. We present a case report of three patients diagnosed with anti-NMDAR encephalitis accompanied by ovarian teratomas at Ajou University Hospital in Korea. The patients demonstrated a different clinical course of the disease. However, upon diagnosis, all patients underwent surgical removal of the ovarian teratoma followed by intensive immunotherapy. The symptoms progressively improved following treatment. This is a case report of a rare autoimmune anti-NMDAR encephalitis associated with ovarian neoplasms, including immature teratoma.

Keywords: Anti-N-methyl-D-aspartate receptor encephalitis; Immature ovarian teratoma; Mature ovarian teratoma

Introduction

Anti-N-methyl-D-aspartate receptor (NMDAR) encephalitis is a rare autoimmune disorder that predominantly affects young adults. The clinical course begins with prominent psychosis or memory deficits leading to seizures, movement abnormalities, or autonomic instability [1-5]. It is a paraneoplastic syndrome accompanied by ovarian neoplasms, mostly mature teratoma. Once this fatal encephalitis is clinically suspected, the ovarian tumor is removed and immunosuppressive therapy is initiated. The diagnosis is confirmed by the presence of antibodies in the cerebrospinal

fluid (CSF) or serum. This is a case report of anti-NMDAR encephalitis associated with ovarian neoplasms, including immature teratoma, in Korea.

Cases

1. Case 1

An 18-year-old woman presented with abdominal pain associated with a 6 cm left ovarian teratoma observed by an abdominal computed tomography (CT) scan (Fig. 1A). Surgical removal was planned. However, on the day of admission, she experienced se-

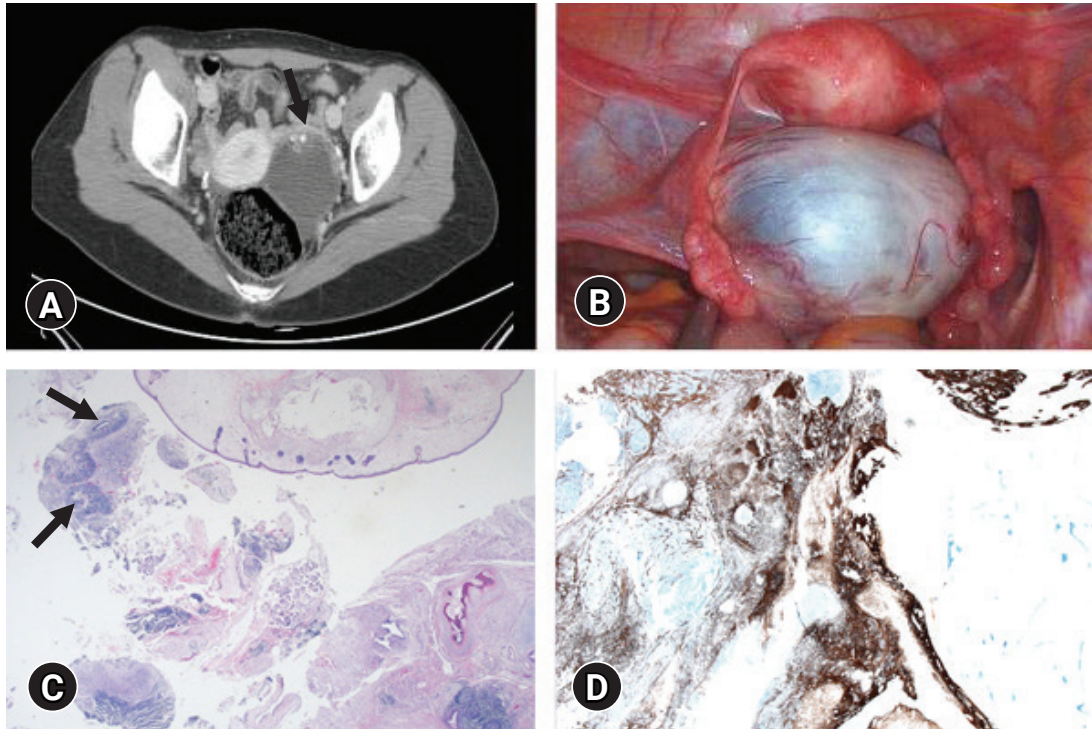


Fig. 1. Imaging and pathology findings for case 1. (A) Abdominal computed tomography findings. Unilocular 6.7-cm cyst (arrow) with solid and calcified portion. (B) Intraoperative image of a left ovarian cyst. (C) The immature teratoma reveals immature neuroepithelial tubules (arrows) in the background of mature teratoma containing skin adnexa, bone, and cartilage with choroid plexus (hematoxylin and eosin stain, $\times 100$). (D) Glial fibrillary acidic protein immunostaining reveals an abundance of mature and immature neural and brain tissues (immunohistochemical stain, $\times 100$).

vere insomnia, followed by global amnesia, aggressive behavior, and suicidal ideation. The patient had headaches and memory disturbance for 2 weeks before admission (Table 1). As a result, the planned operation was postponed. Electroencephalogram (EEG) and brain magnetic resonance imaging (MRI) were unremarkable. Intensive antipsychotic treatment did not improve the symptoms. Under the suspicion of anti-NMDAR encephalitis, removal of the ovarian teratoma was performed (Fig. 1B). Both serum and CSF samples were found to be positive for antibodies against NMDAR. The histopathological diagnosis of the ovarian tumor was an immature teratoma (Fig. 1C, 1D). Immunoglobulin treatment and four cycles of rituximab were administered. The symptoms progressively improved, and at the 9-month follow-up, whole-body positron emission tomography CT and transvaginal sonography were normal.

2. Case 2

A 41-year-old woman was admitted to the hospital with fever and headache. The serum and CSF examinations showed no signs of inflammation. The patient complained about episodes of self-talking and disorientation for the last few days before admission.

Brain MRI and EEG were normal. Despite intensive treatment, the clinical symptoms did not improve. Under the impression of anti-NMDAR encephalitis, an abdominal CT scan was performed (Fig. 2A). It showed a 4 cm ovarian teratoma that was immediately removed, and the patient received corticosteroids and immunoglobulin treatment (Fig. 2B). Anti-NMDAR antibodies were detected in serum and CSF samples. The pathologic diagnosis of the ovarian tumor was a mature teratoma (Fig. 2C, 2D). There was no evidence of recurrence at the 2-month follow-up.

3. Case 3

A 29-year-old woman experienced confusion, agitation, and auditory hallucinations. The serum blood test, CSF examination, and brain MRI showed no abnormalities. Only the EEG test revealed cerebral dysfunction. Empirical treatment with high-dose immunoglobulin, methylprednisolone, and plasma exchange was started; however, symptoms did not improve. Anti-NMDAR encephalitis was considered, and a 3 cm left ovarian teratoma was detected on an abdominal CT scan (Fig. 3A). The serum and CSF tested positive for anti-NMDAR antibodies. The tumor was removed surgically, and the patient received corticosteroids, plasmapheresis,

Table 1. Clinical characteristics of patients

Characteristic	Case		
	1	2	3
Sex/age (yr)	Female/18	Female/41	Female/29
Histology of ovarian tumor	Immature teratoma, grade III	Mature teratoma	Mature teratoma
Site/size of ovarian tumor (cm)	Left/6.4	Left/4.0	Left/3.0
Prodromal symptom	Headache, memory disturbance	Headache, fever	Headache, fever, myalgia
Clinical symptom	Night sweats, global amnesia, aggressive behavior, depression, suicidal ideation	Self-talking, disorientation	Emotional instability, disorientation, dyskinesia, confusion, agitation, auditory hallucinations
Brain MRI	Normal	Increased T2 signal	Normal
CSF examination	Increased glucose	Increased protein	Increased glucose
EEG examination	Normal	Normal	Diffuse cerebral dysfunction
Medical treatment	Corticosteroids, IVIG, rituximab	Corticosteroids, IVIG, aciclovir	Corticosteroids, IVIG, rituximab, plasma exchange
Interval (day)			
Between surgery and the onset of initial symptoms	5	12	23
Between surgery and clinical improvement	20	60	13
Follow-up (mon)	8	2	12

MRI, magnetic resonance imaging; CSF, cerebrospinal fluid; EEG, electroencephalogram; IVIG, intravenous immunoglobulin.

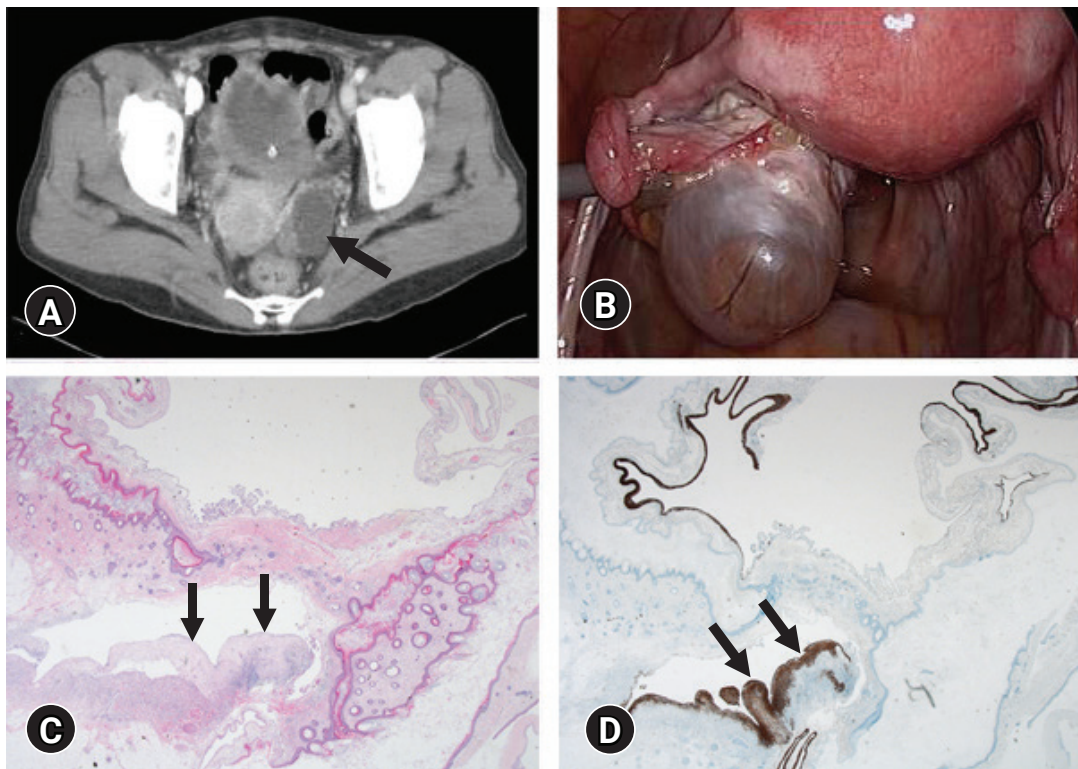


Fig. 2. Imaging and pathology findings for case 2. (A) Abdominal computed tomography findings. A 4-cm cystic mass with fat component (arrow) suggesting a teratodermoid tumor of the left ovary. (B) Intraoperative image of a left ovarian cyst. (C) Mature cystic teratoma shows a small amount of mature neuroglial tissue (arrows) with mature skin adnexal tissue, fat, and choroid plexus (hematoxylin and eosin stain, $\times 100$). (D) Glial fibrillary acidic protein immunostaining highlights mature neuroglial tissue (arrows) in the mature cystic teratoma (immunohistochemical stain, $\times 100$).

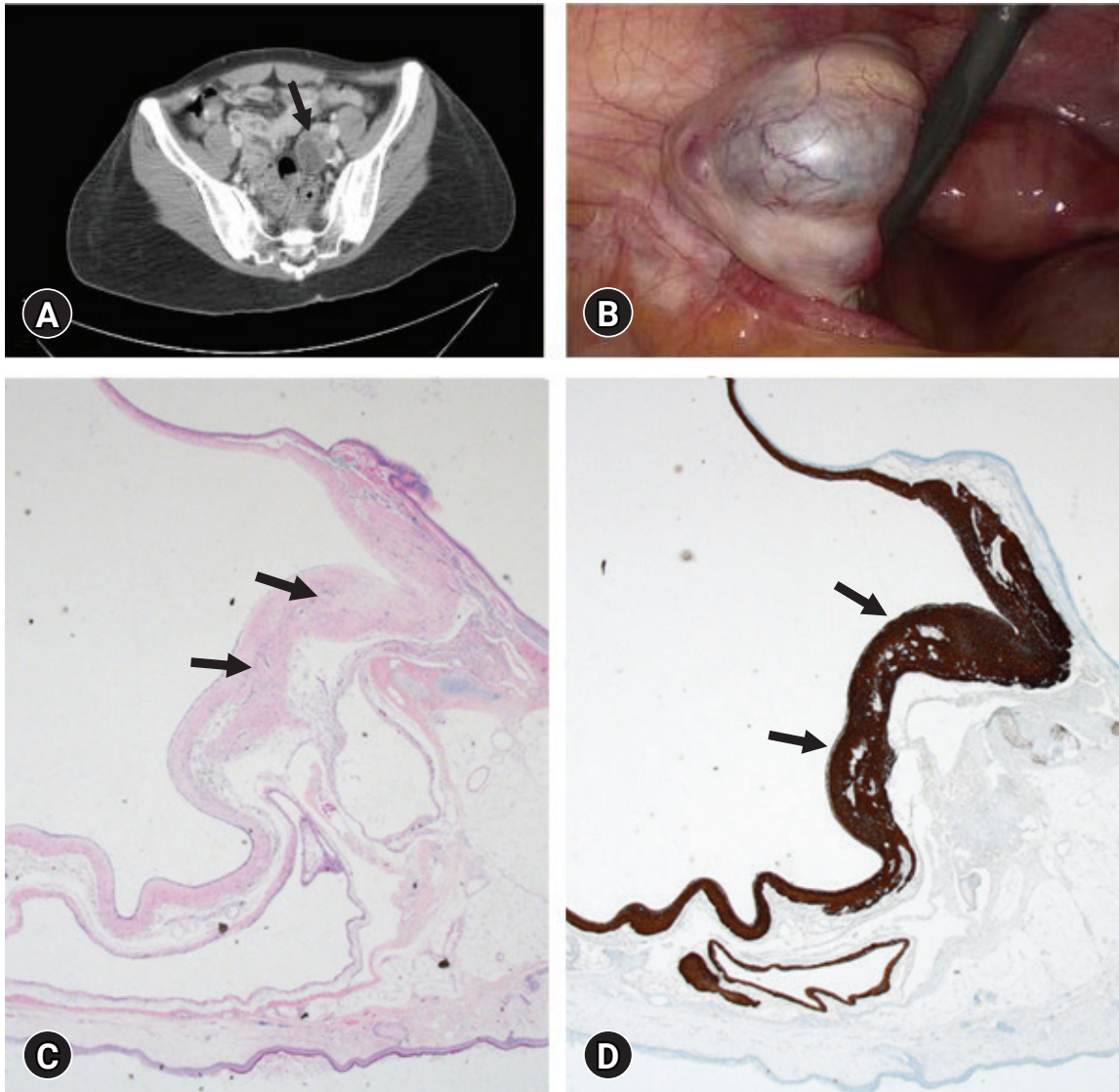


Fig. 3. Imaging and pathology findings for case 3. (A) Abdominal computed tomography findings. A 3-cm cystic mass with fat component (arrow) suggesting a teratodermoid tumor of the left ovary. (B) Intraoperative image of a left ovarian cyst. (C) The mature cystic teratoma containing skin adnexa, squamous epithelium, fat tissue, cartilage with respiratory epithelium, and mature neural tissue (arrows) (hematoxylin and eosin stain, $\times 100$). (D) Glial fibrillary acidic protein immunostaining demonstrates mature neuroglial tissue (arrows) (immunohistochemical stain, $\times 100$).

and rituximab thereafter (Fig 3B). The pathologic diagnosis of the ovarian tumor was a mature teratoma (Fig 3C, 3D). She completely recovered within 3 months.

Discussion

Anti-NMDAR encephalitis is an autoimmune encephalitis first reported by Dalmau et al. [4,5] in 2007. It typically begins with prodromal symptoms such as nonspecific fever, diarrhea, vomiting, headache, or upper-respiratory symptoms before the onset of psychiatric and neurological symptoms, which are often accompanied

by persistent amnesia. It is known that age, sex, and ethnicity are important factors related to the disease, as most patients are women, especially of Asian ethnicity [6,7]. NMDAR hypofunction is related to cognitive defects, whereas overstimulation causes excitotoxicity and subsequent neurodegeneration [8].

The clinical features that distinguish anti-NMDAR encephalitis from other neurological or psychiatric disorders are acute onset of mood and behavioral changes with no prior history of seizures or abnormal movements. The differential diagnoses include primary psychiatric disorder, drug abuse, neuroleptic malignant syndrome, migraine, antipsychotic medications, or infectious encephalitis.

Anti-NMDAR encephalitis should be considered once the above conditions are excluded [9]. The detection of immunoglobulin G antibodies in the serum or CSF confirms the diagnosis. In the advanced stages, the CSF antibodies usually remain elevated, while serum antibodies substantially decline with treatment [10]. There is limited evidence regarding the relationship between the size of the adnexal tumor and encephalitis. However, ovarian teratomas in anti-NMDAR encephalitis are usually not large, and an ovarian teratoma as small as 6 mm in diameter has been reported in association with anti-NMDAR encephalitis [11].

Treatment is focused on resection of the tumor followed by immunotherapy, including glucocorticoids, immunoglobulin, and plasma exchange, which collectively improves the symptoms within 4 weeks. For patients who do not respond to first-line immunotherapy, rituximab or cyclophosphamide may be used. Immunotherapy is applied to treat encephalitis regardless of the type of ovarian teratoma.

This is a case report of a rare autoimmune anti-NMDAR encephalitis associated with ovarian tumors, including immature teratoma, in Korea. Patients showed a wide spectrum of initial symptoms, and immediate surgical removal of the adnexa tumor was performed in all patients, followed by intensive immunotherapy. The course of the disease correlated with previous findings in that neurological symptoms progressively improved following the operation. Consciousness improved first, and then, autonomic function recovered. The frequency of epileptic seizures was reduced, and the social ability returned to the state before the onset of the disease.

Although we were not able to compare the clinical symptoms among anti-NMDAR encephalitis patients with or without ovarian teratoma, according to the study by Zhang et al. [12], there may be differences in laboratory and clinical findings between anti-NMDAR encephalitis with or without ovarian teratoma [12]. Anti-NMDAR encephalitis patients without ovarian teratoma experience more viral prodromal symptoms, whereas patients with teratoma present with milder neurological symptoms. In our study, two patients presented with fever and myalgia, mimicking viral infection, whereas one patient complained about memory disturbance. Moreover, the prevalence of immature teratomas, which generally comprise less than 1% of ovarian teratomas, is much higher among patients with anti-NMDAR encephalitis compared to the general population [13]. Therefore, it is important to inform patients about the possibility of malignancy in cases of anti-NMDAR encephalitis with ovarian teratoma.

In conclusion, anti-NMDAR encephalitis is a rare yet serious disorder that must be considered in patients with ovarian teratoma and neurological symptoms. Anti-NMDAR encephalitis may be

speculated in patients who present with psychotic symptoms that are not improved by typical antipsychotic treatments, and the presence of an ovarian tumor detected on imaging studies. A comprehensive evaluation, including blood tests, CSF examination, brain and abdomen imaging, and antibody screening, is required to exclude other causes before making the diagnosis.

Once the disease is suspected, a combination of surgical removal of adnexal tumors and immunotherapy should be applied. The disorder can be fatal without appropriate treatment. Therefore, it should be included in the differential diagnosis in patients with ovarian teratoma and neurological symptoms.

Notes

Ethical statements

This retrospective study was approved by the Institutional Review Board (IRB) of the Ajou University Hospital (IRB No: ME-DEXP-20-531), and the requirement for informed consent from the patient was waived by the IRB.

Conflicts of interest

No potential conflict of interest relevant to this article was reported.

Author contributions

Conceptualization, Resources: JL, SK, HJC, YHL, JHS, TWK, SJC, KJH, MK; Data curation: TWK; Investigation: JL; Validation: KJH; Formal analysis, Supervision: SJC, KJH; Writing-original draft: JL; Writing-review & editing: MK.

ORCID

Jisun Lee, <https://orcid.org/0000-0002-2870-3176>
 Seongwoo Kang, <https://orcid.org/0000-0002-1540-0934>
 Hye Jin Chang, <https://orcid.org/0000-0002-1122-1269>
 Joo-Hyuk Son, <https://orcid.org/0000-0002-3712-8409>
 Tae Wook Kong, <https://orcid.org/0000-0002-9007-565X>
 Suk-Joon Chang, <https://orcid.org/0000-0002-0558-0038>
 Kyung Joo Hwang, <https://orcid.org/0000-0001-7073-9124>
 Miran Kim, <https://orcid.org/0000-0001-5553-5334>

References

1. Braverman JA, Marcus C, Garg R. Anti-NMDA-receptor encephalitis: a neuropsychiatric syndrome associated with ovarian teratoma. *Gynecol Oncol Rep* 2015;14:1–3.
2. Dalmau J, Lancaster E, Martinez-Hernandez E, Rosenfeld MR, Balice-Gordon R. Clinical experience and laboratory investiga-

- tions in patients with anti-NMDAR encephalitis. *Lancet Neurol* 2011;10:63–74.
3. Irani SR, Bera K, Waters P, Zuliani L, Maxwell S, Zandi MS, et al. N-methyl-D-aspartate antibody encephalitis: temporal progression of clinical and paraclinical observations in a predominantly non-paraneoplastic disorder of both sexes. *Brain* 2010; 133:1655–67.
 4. Dalmau J, Gleichman AJ, Hughes EG, Rossi JE, Peng X, Lai M, et al. Anti-NMDA-receptor encephalitis: case series and analysis of the effects of antibodies. *Lancet Neurol* 2008;7:1091–8.
 5. Dalmau J, Tüzün E, Wu HY, Masjuan J, Rossi JE, Voloschin A, et al. Paraneoplastic anti-N-methyl-D-aspartate receptor encephalitis associated with ovarian teratoma. *Ann Neurol* 2007; 61:25–36.
 6. Yang YW, Tsai CH, Chang FC, Lu MK, Chiu PY. Reversible paraneoplastic limbic encephalitis caused by a benign ovarian teratoma: report of a case and review of literatures. *J Neurooncol* 2006;80:309–12.
 7. Kemp JA, McKernan RM. NMDA receptor pathways as drug targets. *Nat Neurosci* 2002;5(Suppl):1039–42.
 8. Vitaliani R, Mason W, Ances B, Zwerdling T, Jiang Z, Dalmau J. Paraneoplastic encephalitis, psychiatric symptoms, and hypoventilation in ovarian teratoma. *Ann Neurol* 2005;58:594–604.
 9. Florance NR, Davis RL, Lam C, Szperka C, Zhou L, Ahmad S, et al. Anti-N-methyl-D-aspartate receptor (NMDAR) encephalitis in children and adolescents. *Ann Neurol* 2009;66:11–8.
 10. Zakhour M, Axtell AE, Lentz SE. Anti-NMDA receptor encephalitis: consider the ovaries. *Gynecol Oncol* 2015;137(Suppl 1):105.
 11. Medepalli K, Lee CM, Benninger LA, Elwing JM. Psychosis: call a surgeon? A rare etiology of psychosis requiring resection. *SAGE Open Med Case Rep* 2016;4:2050313X16670084.
 12. Zhang L, Lu Y, Xu L, Liu L, Wu X, Zhang Y, et al. Anti-N-methyl-D-aspartate receptor encephalitis with accompanying ovarian teratoma in female patients from East China: clinical features, treatment, and prognostic outcomes. *Seizure* 2020;75: 55–62.
 13. Lee CH, Kim EJ, Lee MH, Yim GW, Kim KJ, Kim KK, et al. Anti-N-methyl-D-aspartate receptor encephalitis: a rare complication of ovarian teratoma. *J Korean Med Sci* 2020;35:e207.