



Case Report

## Delayed Diagnosis of a Tibial Stress Fracture Associated with Glucocorticoid and Methotrexate Therapy in a Patient with Rheumatoid Arthritis: A Case Report

Hye Jeong Shin<sup>1</sup>, Yi Gun Lim<sup>1</sup>, Gi Hyang Lee<sup>2</sup>, Hyun Seok Lee<sup>3</sup>, Beom Yong Song<sup>1</sup>, Yoo Min Choi<sup>1,\*</sup>

<sup>1</sup> Department of Acupuncture and Moxibustion Medicine, Korean Medicine Hospital of Woosuk University, Jeonju, Korea

<sup>2</sup> Department of Internal Medicine, College of Korean Medicine, Woosuk University, Jeonju, Korea

<sup>3</sup> Department of Acupuncture and Moxibustion Medicine, Bundang Jaseng Hospital of Korean Medicine, Bundang, Korea

### ABSTRACT

#### Article history:

Submitted: October 13, 2021

Revised: December 23, 2021

Accepted: December 29, 2021

#### Keywords:

glucocorticoid, methotrexate, rheumatoid arthritis, stress fracture

The risk of stress fractures is associated with rheumatoid arthritis (RA), which can aggravate bone loss. We report the case of a patient who was on long-term medication for RA presenting with lower extremity pain on the left and swelling without trauma. Magnetic resonance imaging and plain radiographs at the previous hospital showed no signs of fracture, but radiographs performed later, revealed a stress fracture of the left distal tibia. The stress fracture may have occurred due to multiple reasons such as long-term use of methotrexate and glucocorticoids, active RA, postmenopausal state, and immobility. Suspicion of a stress fracture should not be ruled out especially in RA patients with persistent pain, even if the radiographical findings are normal. Additional imaging and follow-ups are essential. The patient's pain was relieved with Korean medicine treatments, which suggests their potential application for stress fractures in RA patients.

<https://doi.org/10.13045/jar.2021.00248>  
PISSN 2586-288X eISSN 2586-2898

©2022 Korean Acupuncture & Moxibustion Medicine Society. This is an open access article under the CC BY-NC-ND license (<http://creativecommons.org/licenses/by-nc-nd/4.0/>).

### Introduction

Rheumatoid arthritis (RA) is an autoimmune disease that limits activities by causing inflammation, and periarticular pain [1]. RA patients have a higher risk of stress fractures of the pelvis, spine, and tibia than healthy people [2]. These fractures can occur when repeated force is applied to the bone with an abnormally low density [3].

Causes of stress fractures in patients with RA include inflammation, immobility, and the use of glucocorticoids (GC) or methotrexate (MTX) [4-6]. Inflammation due to RA, reduced physical activity, and GC cause bone loss near the affected joints and

other distant points [4,5]. A case-control study has linked MTX administration to fractures [6].

Pain due to stress fractures in RA patients is often misdiagnosed as a common symptom of inflammation [7]. This can lead to a delayed diagnosis of stress fractures. Increased awareness can reduce these diagnostic delays and prevent the fracture from progressing.

We herein report a distal tibia stress fracture in a patient with RA who was being treated long term with MTX and GC. Due to the diagnosis of the fracture being delayed by about a month, the patient's pain continued, and she was hospitalized for 3 weeks and received Korean medicine treatments.

\*Corresponding author. Yoo Min Choi

Department of Acupuncture and Moxibustion Medicine, Korean Medicine Hospital of Woosuk University, 46, Eoeun-ro, Wansan-gu, Jeonju 54987, Korea

E-mail: [choi@yoomin.net](mailto:choi@yoomin.net)

ORCID: Hye Jeong Shin <https://orcid.org/0000-0002-5434-7240>, Yi Gun Lim <https://orcid.org/0000-0002-7859-4078>,

Gi Hyang Lee <https://orcid.org/0000-0003-1151-0252>, Hyun Seok Lee <https://orcid.org/0000-0002-3767-2914>, Beom Yong Song <https://orcid.org/0000-0001-5050-5240>,

Yoo Min Choi <https://orcid.org/0000-0002-2895-2439>

©2022 Korean Acupuncture & Moxibustion Medicine Society. This is an open access article under the CC BY-NC-ND license (<http://creativecommons.org/licenses/by-nc-nd/4.0/>).

## Case Report

### Patient

OOO (F/63)

### Chief complaint

Pain, swelling, and morning stiffness in the distal 1/3 part of the left tibia and ankle joint, inability to walk.

### Onset

January 1<sup>st</sup>, 2021, after daily activities (there was no trauma history).

### Present illness

Six years ago the patient was prescribed long term medication for RA including 7.5 mg/week of MTX, 2.5 mg of prednisolone, 300 mg of hydroxychloroquine daily, 20 mg of leflunomide, and some analgesics [naproxen 275 mg, LAYLA tablet 405.4 mg, celecoxib 200 mg, tramadol tablet (acetaminophen 325 mg + tramadol 37.5 mg)]. She had intra-articular GC injections several times in the knee, and ankle which she received at a local pain clinic.

The patient was diagnosed as a muscular strain of the lower extremity and there was no sign of fracture on the magnetic resonance imaging (MRI) at a local University Hospital on February 3<sup>rd</sup> (Fig. 1), and radiographs revealed no sign of fracture on February 1<sup>st</sup> (Fig. 2).

She was treated with medication, but the pain continued. Tenderness and swelling were observed around the distal 1/3 part of the left tibia and ankle joint. The patient had full range of ankle movements but had weightbearing limitations, so could not walk without the assistance of a walker. Pain and stiffness were severe in the morning but improved slightly in the afternoon. The patient was admitted to the Woosuk University Korean Medicine Hospital for pain relief on February 10<sup>th</sup>. The MRI scan was repeated at the Woosuk University Korean Medicine hospital and it was confirmed that there was no sign of fracture on the MRI. However, about a week later, the radiographs revealed a cortical discontinuity of the left tibia even though there was no specific activity, and she was diagnosed with a stress fracture on February 16<sup>th</sup> (Fig. 3). Laboratory tests and a bone mineral density test were performed (Table 1).

During hospitalization (February 10<sup>th</sup> to March 2<sup>nd</sup>), the patient received Korean medicine treatments along with the medications previously prescribed for RA. In addition, it was recommended that the patient use a short leg splint and a walker to reduce the load on the lower extremity.

### Patient protection policy for use of patient information

Despite the best effort of the authors to obtain written informed consent, a hospital visit from the patient's remote residence in the current coronavirus-19 pandemic was not an option. Therefore, informed verbal consent was obtained. This study was a retrospective study based on medical records which were obtained from the Institutional Review Board of Korean Medicine Hospital of Woosuk University approved this study (IRB no.: H2107-01).

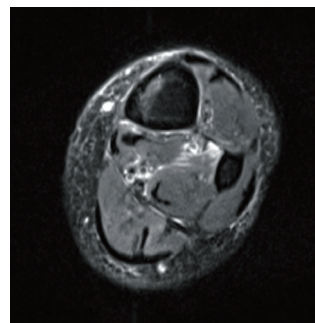


Fig. 1. Axial T2 turbo spin echo magnetic resonance imaging of the left lower extremity (Feb 3<sup>rd</sup>). There is no sign of fracture. It showed high signal changes within the anterior and posterior deep compartment of the muscle (muscle strain).

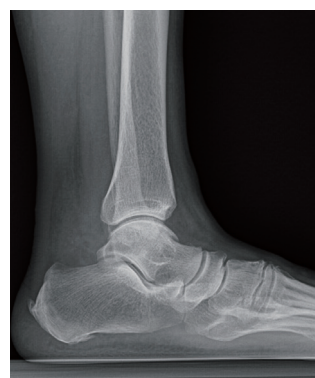

Fig. 2. The lateral radiograph of the left tibia had no sign of fracture (Feb 1<sup>st</sup>).

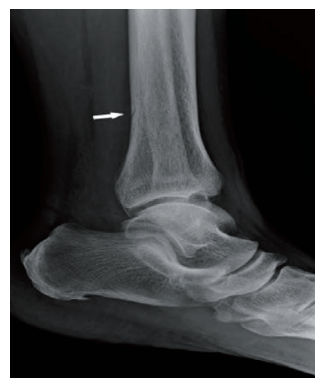

Fig. 3. The lateral radiograph of the left tibia. The scan showed a cortical discontinuity on the posterior margin of the distal metaphysis (white arrow) (Feb 16<sup>th</sup>).

## Treatment methods

### Acupuncture

Acupuncture was performed using sterile 0.25 × 30 mm stainless steel needles (Dongbang Acupuncture, Korea) once a day for 10 minutes, during the hospitalization period. SP6, GB39, BL60, ST36, GB34, SP9, KI3, GB40, BL40, LR3, and Ashi points were used to relieve the pain (Table 2).

Table 1. Examination, Radiology Findings.

Before hospitalization		
X-ray	Feb 1 <sup>st</sup>	Normal
MRI	Feb 3 <sup>rd</sup>	Muscular strain of the lower extremity. No sign of fracture.
During hospitalization		
CRP, ESR	Feb 10 <sup>th</sup> , 19 <sup>th</sup>	Feb 10 <sup>th</sup> - CRP: 0.7 mg/L, ESR: 1 mm/h Feb 19 <sup>th</sup> - CRP: 0.3 mg/L, ESR: 4 mm/h
X-ray	Feb 16 <sup>th</sup> , 24 <sup>th</sup>	Cortical discontinuity on the posterior margin of the tibia
BMD	March 2 <sup>nd</sup>	Osteopenia (femur wards T score: -1.7, L1 T score: -1.2)

BMD, bone mineral density; CRP, C-reactive protein; ESR, erythrocyte sedimentation rate; MRI, magnetic resonance imaging.

Table 2. Standard for Reporting Interventions in Clinical Trials of Acupuncture (STRICTA).

Item	Detail
1. Acupuncture rationale	1a) Style of acupuncture Traditional Korean acupuncture
	1b) Reasoning for treatment provided Literature and clinical experience of experts.
2. Details of needling	2a) Number of needle insertions per subject per session From 12 to 15
	2b) Name of points used SP6, GB39, BL60, ST36, GB34, SP9, KI3, GB40, BL40, LR3, and Ashi points
	2c) depth of insertion 20-25 mm
	2d) Response sought Acupuncture sensation 'De qi'
	2e) Needle stimulation Manual stimulation
	2f) Needle retention time 10 minutes
	2g) Needle type Sterile 0.25×30 mm stainless needles (Dongbang Acupuncture, Korea)
3. Treatment regimen	3a) Number of treatment sessions 21
	3b) Frequency and duration of treatment sessions once a day for 10 minutes (21 days)
4. Other components of treatment	4a) Details of other interventions administered to the acupuncture group (e.g., moxibustion, cupping, herbs, exercises, lifestyle advice) Electroacupuncture, Pharmacopuncture, Herbal medicine, cupping, Physiotherapy, Leg splint, Western medicine treatment
	4b) Setting and context of treatment, including instructions to practitioners, and information and explanations to patients Procedure of treatments
5. Practitioner background	5a) Description of participating acupuncturists (qualification of professional affiliation, years in acupuncture practice, other relevant experience) Korean medicine doctor of Acupuncture and Moxibustion department with more than 1 year of experience
6. Control or comparator interventions	6a) Rationale for the control or comparator in the context of the research question, with sources that justify this choice No control or comparator interventions
	6b) Precise description of the control or comparator. If sham acupuncture or any other type of acupuncture-like control is used, provide details as for items 1 to 3 above No control or comparator interventions

Electroacupuncture

Electroacupuncture (10 Hz) was performed at SP6-GB34 once a day for 10 minutes, during the hospitalization period.

Pharmacopuncture

No side effects were observed in the bee venom allergy test. Sweet bee venom (Kirin Korean medicine extramural herbal dispensary facility, Korea) pharmacopuncture (10%, 1 mL in total) was performed to relieve the pain using a 30G × 1.27 cm needle (Jungrim Medical, Korea), once a day (February 22<sup>nd</sup> to March 2<sup>nd</sup>). Pharmacopuncture was administered at SP6, GB34, GB39, GB40, and BL60 (0.2 mL per acupoint).

Herbal medicine

Whallaktang gamibang (February 10<sup>th</sup> to 16<sup>th</sup>), Ojeoksan (February 17<sup>th</sup> to 19<sup>th</sup>), and YoungsunjetongEum gamibang (February 20<sup>th</sup> to March 2<sup>nd</sup>) were prescribed 3 times per day, 100 mL at a time to relieve the pain (Table 3).

Cupping

Wet cupping therapy was performed twice a week at tender points of GB40, and SP6, the tender point.

Physiotherapy

Hot packs, magnetic and laser, inter current therapy, and infra-

Table 3. Composition of Herbal Medicine Prescribed to the Patient.

Whallaktang-gamibang 2021.02.10 – 2021.02.16		Ojeoksan 2021.02.17 – 2021.02.19		YoungsunjetongEum-gamibang 2021.02.20 – 2021.03.02	
Corydalis Tuber	8 g	Ephedrae Herba	8 g	Forsythiae Fructus	12 g
Chaenomelis Fructus	8 g	Atractylodis Rhizoma	8 g	Siegesbeckiae Herba	12 g
Chelidonii Herba	8 g	Citri Unshius Pericarpium	4 g	Lonicerae Flos	12 g
Clematidis Radix	6 g	Magnoliae Cortex	3 g	Taraxaci Herba	12 g
Zingiberis Rhizoma Recens	4 g	Zingiberis Rhizoma	3 g	Acanthopanax Cortex	7.5 g
Zizyphi Fructus	4 g	Platycodonis Radix	3 g	Sinomeni Caulis et Rhizoma	7.5 g
Crataegi Fructus	4 g	Aurantii Fructus Immaturus	3 g	Kalopanax Cortex	7.5 g
Massa Medicata Fermentata	4 g	Poria Sclerotium	3 g	Citri Unshius Pericarpium	7.5 g
Hordei Fructus Germinatus	4 g	Cnidii Rhizoma	3 g	Glycyrrhizae Radix et Rhizoma	7.5 g
Angelicae Gigantis Radix	3 g	Angelicae Gigantis Radix	3 g	Angelicae Gigantis Radix	6 g
Atractylodis Rhizoma	3 g	Angelicae Dahuricae Radix	3 g	Atractylodis Rhizoma	6 g
Paeoniae Radix	3 g	Paeoniae Radix	3 g	Scutellariae Radix	6 g
Araliae Continentalis Radix	3 g	Cinnamomi Cortex	3 g	Araliae Continentalis Radix	6 g
Citri Unshius Pericarpium	3 g	Glycyrrhizae Radix et Rhizoma	2 g	Schizonepetae Spica	6 g
Osterici seu Notopterygii Radix et Rhizoma	3 g	Pinelliae Tuber	2 g	Paeoniae Radix	4 g
Rehmanniae Radix	3 g			Puerariae Radix	4 g
Myrrha	3 g			Crataegi Fructus	4 g
Carthami Flos	3 g			Massa Medicata Fermentata	4 g
Glycyrrhizae Radix et Rhizoma	2 g			Hordei Fructus Germinatus	4 g
Amomi Fructus	2 g			Myrrha	3 g
				Bombicis Faeces	3 g
				Olibanum	3 g

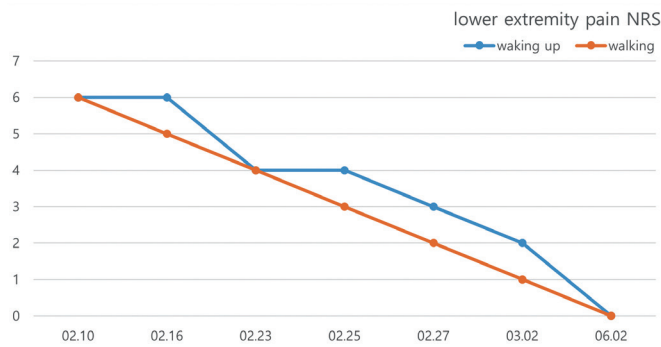


Fig. 4. Changes in the NRS score for subjective pain from admission to discharge and after 3 months of treatment (June 2<sup>nd</sup>). NRS, numerical rating scale.

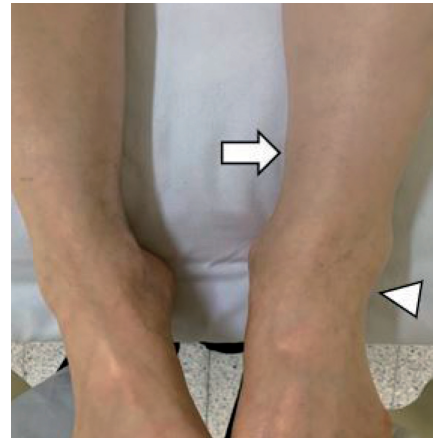


Fig. 5. Ankle and fracture swelling. Swelling in the painful area (white arrowhead) and fracture site (white arrow) on the day of discharge (March 2<sup>nd</sup>).

red were applied for 10 minutes to the left lower extremity daily (except for weekends).

#### Leg splint

The local orthopedic surgery hospital gave the patient a leg splint to protect the patient from a lower extremity injury, but she had not used it. We instructed her to use it. As the pain went away when she walked, the leg splint was removed.

#### Evaluation

##### Numerical rating scale

The numerical rating scale (NRS) was used to measure the severity of pain. A score of 0 indicated no pain and a score of 10 indicated the worst imaginable pain. The degree of pain in the distal 1/3 part of the lower left extremity when waking up in the morning and when walking was measured.

#### Results

The pain gradually improved from an NRS score of 6 to 3 (when waking up in the morning) and from 6 to 2 (when walking). Three months after discharge, the pain had disappeared and her NRS score was 0 for both waking and walking, and normal walking was possible (Fig. 4). The patient initially showed significant swelling of the left ankle joint, which improved and had almost disappeared by discharge (Fig. 5).

#### Discussion

Stress fractures in patients with RA are known to occur, but it is difficult to pinpoint the exact cause because there are many causes. Firstly, GC are often used to relieve the pain of RA by controlling inflammation. However, GC increases osteoclast formation and inhibits osteoblast growth thereby promoting bone loss [8]. Secondly, MTX is used to modify the inflammatory state of patients

with RA [9]. However, MTX can induce “MTX osteopathy” in 2 ways. The first is that MTX increases bone resorption by osteoclasts and the second is that MTX reduces bone formation, resulting in reduced bone density and thickness, which adversely affect osteoblasts [10]. Some RA patients with stress fractures have typically received MTX therapy long term [11,12]. Another study reported that the combined use of MTX and GC may have a greater effect on stress fractures than the individual use of each drug [13]. Thirdly, the chronic inflammation and changes in bone structure, including osteopenia, may lead to bone erosion that are associated with RA, causing stress on the bones and contributing to fractures [14]. Finally, the postmenopausal state is also related to bone loss [15]. Therefore, many factors could have been involved and resulted in the patient’s stress fracture.

Many clinicians have difficulty diagnosing fractures in RA patients. This is because stress fractures have symptoms like those of RA and can often be misdiagnosed as inflammatory symptoms of RA [6]. In addition, since the periosteal reaction, which is a sign of a fracture, can be discerned on plain radiographs after the cortex thickens [16], a newly developed fracture may appear normal. This can result in a delay up to 18 months in the diagnosis of fractures in RA patients [17]. Therefore, special attention is required when RA patients with sufficient risk factors for fracture, such as taking GC and MTX long term and receiving GC intra-articular injections, visit Korean medicine clinics like this patient. A delayed diagnosis of a fracture can result in unnecessary treatment and progressive bone loss. Follow up radiographs are advised every 10 to 14 days [18] or additional imaging may be required.

Periarticular bone density measurement is also used to identify fractures in RA patients [19]. MRI can be used to check for periosteal and bone marrow edema, and a bone scan can identify bone metabolism, making detection of fractures more sensitive than using radiographs [18,20].

Nevertheless, in this case, neither bone marrow edema or stress

fracture could be confirmed on MRI, and after 1 week, even though no special activity was added, a stress fracture was confirmed using plain radiographs at the site of enduring pain (about a month and a half). Judging from this case, it is very important not only to perform additional imaging such as MRI and a bone scan, but also periodically follow up with plain radiographs to prevent a potential delay in diagnosis of fractures if symptoms are refractory in patients with RA.

Most RA patients with stress fractures who received conservative treatment with a cast for 6 to 12 weeks and had a good prognosis [16], but there have not been any publications of Korean medicine treatments for these patients. In this case, it was confirmed that the symptoms were relieved by follow-up imaging and Korean medicine treatments during the hospitalization. After discharge, pain relief was maintained even after a reduction in GC prescription from the previous hospital. Whether Korean medicine treatments can play a role in the improvement of tibial stress fractures in RA patients needs further research.

There was no reduction of MTX dose in this patient during the observation period. This is probably because there is still debate about stopping or reducing the MTX dose in RA patients despite the development of MTX osteopathy. It has been reported that in some cases, after 3 months of stopping MTX, RA was activated and the patients started taking MTX again [9].

A limitation of this report is that more studies are needed to fully explain the exact cause of stress fractures in RA patients, and since this is only 1 case, further studies applying Korean medicine treatments for stress fractures in RA patients are needed. Of note, the patient was told that the fracture had completely improved when she had a plain radiograph at another hospital 3 months after discharge from Woosuk Korean Medicine hospital, but it is regrettable that the plain radiographs follow-up was not performed at this hospital at the same time due to patient choice.

### Conflicts of Interest

The authors have no conflicts of interest to declare.

### Ethical Statement

This research did not involve any human or animal experiment.

### References

- [1] A snapshot of arthritis in Australia 2010. Canberra (Australia): Australian Institute of Health and Welfare; 2010.
- [2] Staa TV, Geusens P, Bijlsma JW, Leufkens HG, Cooper C. Clinical assessment of the long-term risk of fracture in patients with rheumatoid arthritis. *Arthritis Rheum* 2006;54:3104-3112.
- [3] Devas M. *Stress Fractures*. London (England): Churchill Livingstone; 1975.
- [4] Sambrook PN, Eisman JA, Champion GD, Yeates MG, Pocock NA, Eberl S. Determinants of axial bone loss in rheumatoid arthritis. *Arthritis Rheum* 1987;30:721-728.
- [5] Reid DM, Kennedy NS, Smith MA, Tohill P, Nuki G. Total body calcium in rheumatoid arthritis: effects of disease activity and corticosteroids treatment. *Br Med J (Clin Res Ed)* 1982;285:330-332.
- [6] Yurtsever A, Fagerberg SK, Rasmussen C. Insufficiency fractures of the knee, ankle, and foot in rheumatoid arthritis: A case series and case-control study. *Eur J Rheumatol* 2020;7:124-129.
- [7] Elkayam O, Paran D, Flusser G, Wigler I, Yaron M, Caspi D. Insufficiency fractures in rheumatic patients: misdiagnosis and underlying characteristics. *Clin Exp Rheumatol* 2000;18:369-374.
- [8] Chung YS. Glucocorticoid-induced Osteoporosis: From Pathogenesis to Treatment. *J Korean Soc Osteoporos* 2009;7:145-151.
- [9] Meier L, van Tuyll van Serooskerken AM, Liberton E, Kleijn L, Westgeest T, Polak M et al. Fractures of the proximal tibia associated with longterm use of methotrexate: 3 case reports and a review of literature. *J Rheumatol* 2010;37:2434-2438.
- [10] Preston SJ, Diamond T, Scott A, Laurent MR. Methotrexate osteopathy in rheumatic disease. *Ann Rheum Dis* 1993;52:582-585.
- [11] Lingg GM, Soltész I, Kessler S, Dreher R. Insufficiency and stress fractures of the long bones occurring in patients with rheumatoid arthritis and other inflammatory diseases, with a contribution on the possibilities of computed tomography. *Eur J Radiol* 1997;26:54-63.
- [12] Spina A, Clemente A, Vancini C, Fejzo M, Campioni P. Spontaneous talar and calcaneal fracture in rheumatoid arthritis: A case report. *J Radiol Case Rep* 2011;5:15-23.
- [13] Buckley LM, Leib ES, Cartularo KS, Vacek PM, Cooper SM. Effects of low dose methotrexate on the bone mineral density of patients with rheumatoid arthritis. *J Rheumatol* 1997;24:1489-1494.
- [14] Trickey J, Barkham N. Foot and ankle insufficiency fracture in rheumatoid arthritis. *MOJ Orthop Rheumatol* 2015;3:00091.
- [15] Alswat KA. Gender disparities in osteoporosis. *J Clin Med Res* 2017;9:382-387.
- [16] Malkoc M, Korkmaz O, Ormeci T, Oltulu I, Isyar M, Mahirogullari M. An unusual stress fracture: Bilateral posterior longitudinal stress fracture of tibia. *Int J Surg Case Rep* 2014;5:500-504.
- [17] Defoort S, Mertens P. Multiple tibial insufficiency fractures in the same tibia: A case report. *Geriatr Orthop Surg Rehabil* 2011;2:69-72.
- [18] Berger FH, de Jonge MC, Maas M. Stress fractures in the lower extremity. The importance of increasing awareness amongst radiologists. *Eur J Radiol* 2007;62:16-26.
- [19] Alenfeld FE, Diessel E, Brezger M, Sieper J, Felsenberg D, Braun J. Detailed analyses of periarticular osteoporosis in rheumatoid arthritis. *Osteoporos Int* 2000;11:400-407.
- [20] Martin P. The appearance of bone scans following fractures, including immediate and long-term studies. *J Nucl Med* 1979;20:1227-1231.