



Case Report

## Effects of Complex Korean Medicine Treatment on a Patient with Knee Pain and Ankylosis Following a Distal Femur Osteotomy: A Case Report

Han Bin Park<sup>1,\*</sup>, Eun Sil Heo<sup>2</sup>, Dong Hwi Yoo<sup>1</sup>, Won Suk Jang<sup>1</sup>, Oh Bin Kwon<sup>1</sup>, Ki Won Choi<sup>3</sup>, Min Jin Kwon<sup>3</sup>, Tae Ju Kim<sup>3</sup>, Seon Woo Jang<sup>4</sup>, Oh Hoon Kwon<sup>5</sup>

<sup>1</sup> Department of Acupuncture and Moxibustion, Haeundae Jaseng Hospital of Korean Medicine, Busan, Korea

<sup>2</sup> Department of Acupuncture and Moxibustion, College of Korean Medicine, Daegu Haany University, Daegu, Korea

<sup>3</sup> Department of Internal Medicine of Korean Medicine, Haeundae Jaseng Hospital of Korean Medicine, Busan, Korea

<sup>4</sup> Department of Oriental Neuropsychiatry, Haeundae Jaseng Hospital of Korean Medicine, Busan, Korea

<sup>5</sup> Department of Acupuncture and Moxibustion, Changwon Jaseng Hospital of Korean Medicine, Changwon, Korea

### ABSTRACT

#### Article history:

Submitted: October 28, 2021

Revised: December 28, 2021

Accepted: February 21, 2022

#### Keywords:

femur, knee, Korean traditional medicine, osteotomy, pain, pharmacopuncture

Distal femur osteotomy (DFO) is a controlled surgical break of the femur performed to allow realignment of the limb. Redistribution of the load aims to correct the abnormal mechanical weight-bearing axes in patients with abnormal alignment of the lower extremities, and degenerative changes in the knee joint. This report describes a complex Korean medicine treatment for a patient complaining of knee pain and stiffness following a DFO. Post-operative care for the patient lasted 78 days with treatment including pharmacopuncture, acupuncture, herbal medicine, cupping therapy, and physiotherapy. The effectiveness of the treatments was evaluated using the numerical rating scale, range of motion of the knee, and by physical examination. After treatment, these evaluation indicators improved, suggesting that the complex Korean medicine treatment received by the patient was an appropriate treatment for knee pain and stiffness following a DFO.

<https://doi.org/10.13045/jar.2021.00276>  
pISSN 2586-288X eISSN 2586-2898

©2022 Korean Acupuncture & Moxibustion Medicine Society. This is an open access article under the CC BY-NC-ND license (<http://creativecommons.org/licenses/by-nc-nd/4.0/>).

### Introduction

Knee osteoarthritis is a major cause of mobility disorders in the elderly. Osteoarthritis is a cause of misalignment of the joint due to the deleterious effects it has upon the joint causing cartilage loss and joint deformation [1].

Patients with osteoarthritis present with limitation of movement to the extent that they cannot perform activities normally. Osteotomy for the knee joint is a surgical technique that disperses

the load applied to the lesion. This method corrects the abnormal mechanical axis in patients with abnormal alignment of the lower extremities and degenerative changes in the knee joint. However, unlike artificial joint replacement surgery, following osteotomy for the knee joint, the pain is reduced through surgical intervention, degenerative changes are delayed, and the knee joint is preserved extending the lifespan [2]. In particular, the main indication of distal femur osteotomy (DFO) is osteoarthritis which is accompanied by external deformation and the treatment involves an

#### \*Corresponding author. Han-Bin Park

Department of Acupuncture and Moxibustion, Haeundae Jaseng Hospital of Korean Medicine, Busan, Korea

E-mail: [phb0089@naver.com](mailto:phb0089@naver.com)

ORCID: Han Bin Park <https://orcid.org/0000-0003-2476-5422>, Eun Sil Heo <https://orcid.org/0000-0002-6616-2868>,

Dong Hwi Yoo <https://orcid.org/0000-0001-9384-6344>, Won Suk Jang <https://orcid.org/0000-0003-0147-3048>, Oh Bin Kwon <https://orcid.org/0000-0002-4574-6557>,

Ki Won Choi <https://orcid.org/0000-0001-9107-8361>, Min Jin Kwon <https://orcid.org/0000-0002-8504-9799>, Tae Ju Kim <https://orcid.org/0000-0003-0716-8597>,

Seon Woo Jang <https://orcid.org/0000-0002-1125-3412>, Oh Hoon Kwon <https://orcid.org/0000-0001-9059-0371>

©2022 Korean Acupuncture & Moxibustion Medicine Society. This is an open access article under the CC BY-NC-ND license (<http://creativecommons.org/licenses/by-nc-nd/4.0/>).

incision on the outer compartment of the knee joint [3].

Korean medicine treatment following a high tibial osteotomy (one of the osteotomies around the knee) has been reported [4], but no cases of DFO have been reported to date. This case study presents the effectiveness of Korean medicine treatment following a DFO.

## Case Report

### Patient

OOO(M/57)

### Chief complaint (onset)

Right knee pain and stiffness (February 2021).

### Past medical history (-) / social history (-)

Cerebral palsy ('65), HTN ('18), Stem Cells OP in Knee Osteoarthritis ('20), DFO ('20)/ 170 cm, 75 kg, Smoking (-), Drinking (-), Occupation: Onsite worker.

### Present illness

In early December 2020, the patient experienced right knee pain which was diagnosed at a local orthopedic center as “the right knee cartilage was worn out.” Subsequently, the patient underwent a DFO at a hospital in Seoul. However, the pain was barely relieved. In February 2021, the patient complained of severe right knee pain and stiffness, and was hospitalized for 2 weeks at a local Korean medicine hospital. Although there was slight relief of pain, symptoms of joint stiffness persisted. Therefore, the patient attended a consultation at the Changwon Jaseng Hospital of Korean Medicine on March 11, 2021, and was hospitalized on March 15, 2021,

### Treatment period

From March 15, 2021 to May 31, 2021 (78 days of hospitalization).

### Radiology

Refer to Fig. 1.

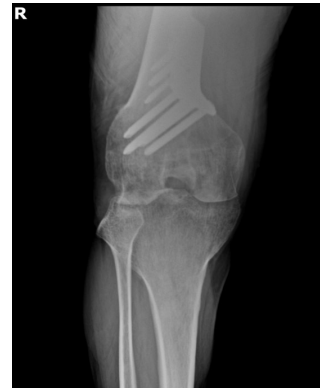

Fig. 1. X-ray of the right knee. The scan showed a state of distal femur osteotomy.

### Patient protection policy on patient information use

To protect patients' personal information, medical records were obtained following approval from the Institutional Review Board of the Haeundae Jaseng Korean Medicine Hospital (IRB File no.: 2021-10-007).

### Treatments

#### Pharmacopuncture

Shinbaro pharmacopuncture (Korea, Namyangju, Jaseng Wonoe Tangjunwon) was administered to the right side at ST35, Ex-LE4, BL38, lateral collateral ligament, and medial collateral ligament. Pharmacopuncture was injected 0.5–1 cc per section applying a 30 gauge × 25 mm needle with a 1 cc syringe (Korea, Gumi, Sinchangmedical) disposable, twice daily. The depth was approximately 1 cm to 2.5 cm.

#### Acupuncture

Electroacupuncture (3 Hz) was administered at the ST34, ST36, SP9, SP10, GB34, and Ashi points for 15 minutes, twice daily. The needle was size 0.25×40 mm, disposable, and made of standardized stainless steel (Korea, Boryung, The Eastern acupuncture equipment manufacturer).

#### Herbal medicine

Geoseubhwalhyeoljitong-Tang (120 mL/packet) and Yeongolbogang-Hwan (tablets) were stipulated. Table. 1 shows the

Table 1. The Ingredient of Herbal Medicines.

Herbal medicines	Herbal components
Geoseubhwalhyeoljitong-Tang	Cinnamomi Ramulus 3.75 g, Dianthi Herba 3.75 g, Lonicerae Flos 7.5 g, Angelicae Gigantis Radix 3.75 g, Persicae Semen 3.75 g, Akebiae Caulis 7.5 g, Saposhnikovia Radix 3.75 g, Angelicae Dahuricae Radix 3.75 g, Rehmanniae Radix 3.75 g, Sappan Lignum 1.875 g, Linderae Radix 3.75 g, Achyranthis Bidentatae Radix 3.75 g, Clematidis Radix 3.75 g, Coicis Semen 7.5g, Poria 3.75 g, Paeoniae Radix Rubra 3.75 g, Citri Pericarpium 3.75 g, Atractylodis Rhizoma 7.5 g, Cnidii Rhizoma 3.75 g, Gentianae Radix 3.75 g, Polygoni Avicularis Herba 3.75 g, Carthami Flos 1.875 g
Yeongolbogang-Hwan	Poria cocos Wolf. 0.6 g, Ginseng Radix 0.3 g, Achyranthes bidentata Blume 0.15 g, Asini Cornii Colla 0.01 g, Rehmanniae Radix Recens 0.6 g, Apis cerana 0.6 g, Drynariae Rhizoma 0.1 g

Table 2. Changes in Symptoms Documented During Physical Examinations, and the Capacity to Walk.

	Post admission						Discharge
	Day 1	Day 15	Day 30	Day 45	Day 60	Day 78	
Edema	+++*	++†	+‡	+/-	-§	-	
Flare	+++	++	+	+/-	-	-	
Pyrexia	+++	++	++	+	+/-	-	
Night pain	+++	+++	++	+	+/-	-	
Aid / walking time	W/C -	W/C -	W/C -	Walker 2 mins	Walker 5 mins	Walker 10 mins	

\* Severe.

† Moderate.

‡ Minor.

§ Intermittent.

|| Negative.

W/C, wheelchair.

ingredients of the herbal medicines administered to the patient 3 times daily during hospitalization.

### Cupping

Only fumigated disposable cupping was used to prevent infection. (Korea, Boryung, Eastern acupuncture equipment manufacturer). Dry and wet cupping were performed on the right side at ST32 and BL37 twice a day for 10 minutes.

### Physiotherapy

When the pain was relieved, the patient received manual treatment that focused on muscle relaxation and joint movement techniques around the knee joint. From the time the active ROM was measured, the patient was taught muscle strengthening exercises that focused on the quadriceps femoris muscles.

### Assessments

The patient data were recorded every 15 days starting from the date of admission.

### Numerical rating scale

The numerical rating scale (NRS) was used to assess the intensity of perceived pain on a scale from 1 to 10. A score of 1 is the complete absence of pain and a score of 10 is the worst pain thinkable [5].

### Range of Motion

The range of motion (ROM) regarding articulations are often documented in a patient's medical file because they are considered important data for the evaluation of disability [6]. The change in the angle of active flexion was used to evaluate the function of the knee joint (the normal operating range of this ROM test was set as 135°).

### Physical examination

The time taken whilst standing in place on both feet was recorded

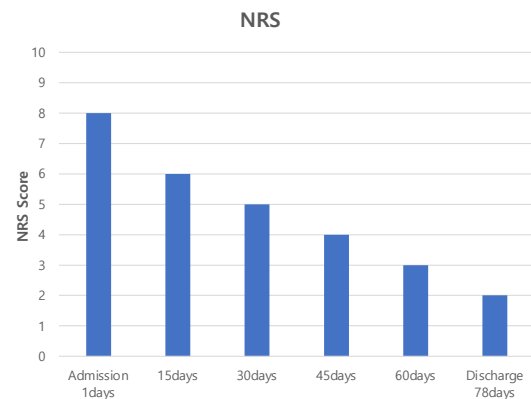


Fig. 2. Changes in numerical rating scale score for right knee pain. NRS, numerical rating scale.

to determine the extent of weight the knee joint could be loaded with. In addition, clinical signs of edema, flare, pyrexia, and pain at night at the DFO surgical site were measured. Changes in walking aid and time spent walking were also routinely observed.

### Treatment progress

On the day of admission, the right knee was stiff and could not be bent. He presented with severe pain, edema, pyrexia, flare, and night pain. Due to difficulty standing and walking, the patient used a wheelchair. One month post admission, joint stiffness, pain, edema, and flares were gradually relieved, and standing upright was possible for approximately 3 minutes, but a wheelchair was still used. From the 45th day post admission, there was a little edema, fewer flares, and joint stiffness, whilst pain, pyrexia, and night pain were relieved. The patient was able to stand upright for about 10 minutes and walked for about 2 minutes using a walker. From the 60th day post admission, joint stiffness had greatly reduced, and the patient was able to stand upright for about 20 minutes, and walked for about 5 minutes using a walker. When the patient was discharged from hospital on Day 78, it was possible for him to stand for 30 minutes and walk with a walker for up to 10 minutes. In addition, most indicators showed an improvement (Table 2; Figs. 2–4).

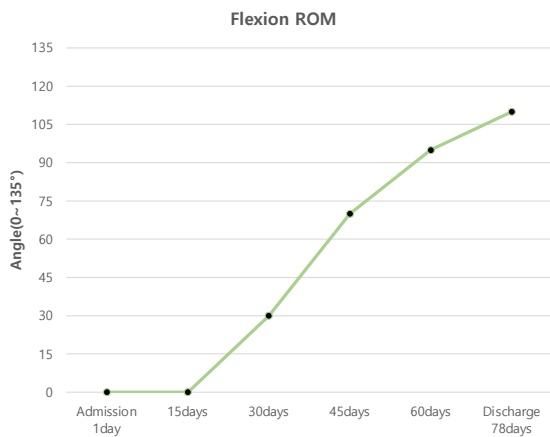


Fig. 3. Changes in range of motion of flexion in the right knee.

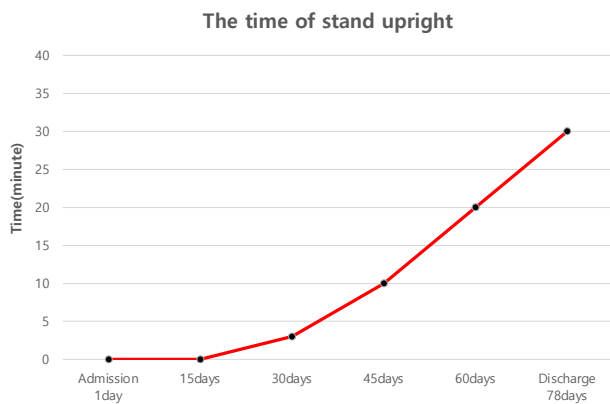


Fig. 4. Changes in the duration of upright standing time.

## Discussion

A surgical indication for a DFO is a patient under the age of 65 years with a normal inner compartment of the knee joint and femoral joint, and external degenerative arthritis with external deformation. DFO is an effective treatment because it can preserve the knee joint, removing the need for an artificial joint. However, since the rehabilitation period is long and pain may remain, studies are required to determine appropriate treatments following a DFO. An appropriate patient group must be selected for study which is based on the indications [7].

Generally, postoperative complications may arise due to surgical accuracy i.e., if the correction angle was excessive during surgery, degenerative arthritis may occur, or if the correction angle was insufficient, the symptoms of osteoarthritis may not improve (surgery failure) [8]. In this case study the patient presented with pain and stiffness which occurred in the affected area due to insufficient management after surgery. However, the discomfort

was greatly reduced by using complex Korean medicine treatment and the patient was discharged on Day 78 post-admission.

Looking at the Korean medicine treatment performed on the patient, Shinbaro pharmacopuncture (which contains components of GCSB-5) has been reported to exert anti-inflammatory activity which have been correlated with reduced nitric oxide synthase and inhibition of cyclooxygenase-2 [9]. These mechanisms were reported to result in reduced inflammation of the knee joint, and improved movement and reduced level of pain [9]. The effect of electroacupuncture performed around the knee to control pain (although it could not be differentiated from the pain-relieving effect of morphine) reportedly uses different opioid systems in the central nervous system which were activated according to the specific frequency used for electroacupuncture [10]. Cupping therapy is transmitted to the central nervous system through the reflective pathways of the skin and vascular receptors to balance excitement and suppression. In addition, cupping, increases the capacity for each body part to control and enhance metabolism in the tissues corresponding to the affected area [11]. Therefore, cupping may have been effective in lessening pain and stiffness by reducing edema, flares, and pyrexia around the surgical area. Through the use of manual therapy, where the muscle is relaxed, joint movement was improved, furthermore, with thigh muscle strengthening exercises the patient's time in an upright position, and aided walking time increased.

The patient in this case report underwent DFO, and failed to receive proper care. After surgery, the treatment received by the patient made the symptoms worse than before surgery. Adapting the complex Korean medicine treatment which a patient is receiving can have a significant effect on the symptoms of pain and stiffness around the knee. However, evidence supporting this treatment modality is weak, since this is only 1 patient in a case report. Randomized controlled clinical trials, and comprehensive studies on complex Korean medicine treatment for patients presenting with discomfort following a DFO is necessary for high-quality evidence.

## Conflict of Interest

The authors have no conflicts of interest to declare.

## Funding

None.

## Ethical Statement

This research did not involve any human or animal experiments.

## Data Availability

All relevant data are included in this manuscript.

## References

- [1] Felson DT, Engl N, Med J. Osteoarthritis of the Knee. *N Engl J Med* 2006;354:841-848

- [2] Lim SW, Ryu SM, Shon OJ. Osteotomy around the Knee: Indication and Preoperative Planning. *J Korean Orthop Assoc* 2018;53:283-292. [in Korean].
- [3] Chahla J, Mitchell JJ, Liechti DJ, Moatshe G, Menge TJ, Dean CS et al. Opening- and Closing-Wedge Distal Femoral Osteotomy: A Systematic Review of Outcomes for Isolated Lateral Compartment Osteoarthritis. *Orthop J Sports Med* 2016;4:2325967116649901.
- [4] Geum JH, Ha WB, Koh NY, Lee JH. A Rehabilitation Protocol for High Tibial Osteotomy in Korean Medicine: A Report of 3 Cases. *J Korean Med Rehabil* 2018;28:107-118. [in Korean].
- [5] Kim SH, Ahn J, Ock M, Shin S, Park J, Luo N et al. The EQ-5D-5L valuation study in Korea. *Qual Life Res* 2016;25:1845-1852.
- [6] Günel I, Köse N, Erdogan O, Göktürk E, Seber S. Normal Range of Motion of the Joints of the Upper Extremity in Male Subjects, with Special Reference to Side. *J Bone Joint Surg Am* 1996;78:1401-1404.
- [7] Seo YR, Nha KW, Ha SS. Surgical Technique for Distal Femur Varization Osteotomy. *J Korean Orthop Assoc* 2018;53:301-306. [in Korean].
- [8] Charles E Giangarra, Robert C. Manske. *Clinical orthopaedic rehabilitation*, 4th ed. Philadelphia (PA): Elsevier; 2018. p. 417-421.
- [9] Chung HJ, Lee HS, Shin JS, Lee SH, Park BM, Youn YS et al. Modulation of acute and chronic inflammatory processes by a traditional medicine preparation GCSB-5 both in vitro and in vivo animal models. *J Ethnopharmacol* 2010;130:450-459.
- [10] Han SY, Lee JY, Park SH, Yang KY, Lee JH, Kim JS et al. A Clinical Study on Effect of Electro-acupuncture Treatment for Whiplash Injury Patients Caused by Traffic Accident. *J Acupunct Res* 2011;28:107-115. [in Korean].
- [11] The Society of Korean Medicine Rehabilitation. *Korean Rehabilitation Medicine*, 4th ed. Paju (Korea): Koonja Publishing; 2015: p. 404-405, 413-416.