



Ultrasound-guided erector spinae plane block for pain management after gastrectomy: a randomized, single-blinded, controlled trial

Heejoon Jeong, Ji Won Choi, Woo Seog Sim, Duk Kyung Kim, Yu Jeong Bang, Soyeon Park, Hyeon Yeo, and Hara Kim

Department of Anesthesiology and Pain Medicine, Samsung Medical Center, Sungkyunkwan University School of Medicine, Seoul, Korea

Received November 29, 2021

Revised March 11, 2022

Accepted March 11, 2022

Handling Editor: Hojin Lee

Correspondence

Ji Won Choi

Department of Anesthesiology and Pain Medicine, Samsung Medical Center, Sungkyunkwan University School of Medicine, 81 Irwon-ro, Gangnam-gu, Seoul 06351, Korea

Tel: +82-2-3410-0730

Fax: +82-2-3410-6626

E-mail: jiwon0715.choi@samsung.com

Background: Open gastrectomy causes severe postoperative pain. Therefore, we investigated the opioid-sparing effect of the ultrasound-guided bilateral erector spinae plane block (ESPB) after open gastrectomy.

Methods: Adult patients undergoing open gastrectomy were randomly assigned to either the ESPB group (ESPB + fentanyl based intravenous patient-controlled analgesia [IV-PCA]) or a control group (fentanyl based IV-PCA only). The primary outcome was total fentanyl equivalent consumption during the first 24 hour postoperatively. Secondary outcomes were pain intensities using a numeric rating scale at the post-anesthesia care unit (PACU) and at 3, 6, 12, and 24 hour postoperatively, and the amount of fentanyl equivalent consumption during the PACU stay and at 3, 6, and 12 hour postoperatively, and the time to the first request for rescue analgesia.

Results: Fifty-eight patients were included in the analysis. There was no significant difference in total fentanyl equivalent consumption during the first 24 hour postoperatively between the two groups ($P = 0.471$). Pain intensities were not significantly different between the groups except during the PACU stay and 3 hour postoperatively ($P < 0.001$, for both). Time to the first rescue analgesia in the ward was longer in the ESPB group than the control group ($P = 0.045$).

Conclusions: Ultrasound-guided ESPB did not decrease total fentanyl equivalent consumption during the first 24 hour after open gastrectomy. It only reduced postoperative pain intensity until 3 hour postoperatively compared with the control group. Ultrasound-guided single-shot ESPB cannot provide an efficient opioid-sparing effect after open gastrectomy.

Key Words: Analgesia, Patient-Controlled; Analgesics, Opioid; Fentanyl; Gastrectomy; Nerve Block; Nociceptive Pain; Pain Management; Pain, Postoperative; Ultrasonography, Interventional.

INTRODUCTION

Gastric cancer is the fifth most frequently diagnosed cancer, with the third highest mortality rate among all malig-

nancies worldwide [1]. Surgical resection is the mainstay of treatment for gastric cancer [2]. Although a minimally invasive surgical approach has reduced surgical stress and facilitated postoperative recovery, open gastrectomy with

© This is an open-access article distributed under the terms of the Creative Commons Attribution Non-Commercial License (<http://creativecommons.org/licenses/by-nc/4.0/>), which permits unrestricted non-commercial use, distribution, and reproduction in any medium, provided the original work is properly cited.

© The Korean Pain Society, 2022

Author contributions: Heejoon Jeong: Writing/manuscript preparation; Ji Won Choi: Writing/manuscript preparation; Woo Seog Sim: Writing/manuscript preparation; Duk Kyung Kim: Methodology; Yu Jeong Bang: Writing/manuscript preparation; Soyeon Park: Investigation; Hyeon Yeo: Investigation; Hara Kim: Investigation.

regional lymphadenectomy remains a curative treatment for advanced gastric cancer [3]. However, open gastrectomy can cause severe postoperative pain due to large incisions, retraction through the abdominal wall, and direct manipulation of visceral organs. Postoperative pain can be associated with patient discomfort, delayed postoperative recovery, increased medical cost, and poor surgical outcomes [4,5].

To date, to improve postoperative recovery, multimodal opioid-sparing analgesia has been recommended to achieve optimal analgesia and minimize opioid-related side effects [6]. Thoracic epidural analgesia (TEA) had been used widely as the gold standard treatment for opioid sparing analgesia after major abdominal surgeries [7]. However, it has gradually lost its position in postoperative pain control due to its relatively common complications such as hypotension and urinary retention, as well as its low cost-effectiveness [8–10]. The risk of rare but serious complications has also made surgical patients reluctant to choose TEA [11]. Alternatively, the interfascial plane block has emerged as part of a multimodal opioid-sparing analgesia method in recent decades due to its relative ease of performance and low complication rate [12].

The ultrasound-guided erector spinae plane block (ESPB) is a novel interfascial plane block that was first introduced for thoracic pain management [13]. In this technique, local anesthetics are injected into the interfascial plane under the erector spinae muscle. The ESPB involves injection of local anesthetics into the thoracic paravertebral space. As it can block both the ventral rami of spinal nerves and the rami communicantes containing sympathetic nerve fibers, it can provide visceral as well as somatic sensory blockade, indicating it as a feasible analgesic modality for abdominal surgeries [14–16]. Also, compared to TEA, the ESPB has a lower risk of serious complications as well as hypotension, a common complication [17,18]. However, there have been no studies examining the effect of a single-shot ESPB on postoperative analgesia in patients undergoing open gastrectomy.

Therefore, in this prospective randomized controlled trial (RCT), we investigated the opioid-sparing effect of the ESPB in gastric cancer patients undergoing open gastrectomy. The primary endpoint was total fentanyl equivalent consumption during the first 24 hour postoperatively. We hypothesized that ultrasound-guided bilateral ESPB would reduce total fentanyl equivalent consumption during the 24 hour after open gastrectomy.

MATERIALS AND METHODS

1. Study design

This prospective, single-blinded, RCT was conducted at a tertiary academic hospital in Seoul, South Korea. The study protocol was approved by the Institutional Review Board of Samsung Medical Center (approval No. SMC 2019-01-131; approval date: February 13, 2019), and registered with the Korean Clinical Research Information Service (registration No. KCT0003752; principal investigator: Ji Won Choi; registration date: April 12, 2019; <http://cris.nih.go.kr>). This study was performed in accordance with the ethical principles of the 1964 Declaration of Helsinki and its later amendments. The trial was conducted following the original protocol and CONSORT (Consolidated Standards of Reporting Trials) guideline [19].

2. Study population

Patients between 20 and 70 years of age who were scheduled for elective open gastrectomy and with American Society of Anesthesiologists physical status I to III were included. Exclusion criteria included a history of chronic pain or analgesic medication for more than 3 months, psychological disorder, major depressive disorder, history of drug abuse, allergy to the local anesthetics, infection around the injection site, coagulation abnormality, renal dysfunction (serum creatinine > 2.0 mg/dL), bodyweight < 50 kg, and patient refusal. Patients who did not meet the predefined criteria for successful block after ESPB, to be mentioned later, were also excluded.

3. Randomization and blinding method

Randomization was conducted using computer-generated random numbers with a fixed block size of 4 and a 1:1 ratio. The patient assignments were sealed in opaque envelopes. A study group member (JWC) opened the sealed envelope in the pre-anesthesia room and performed an ESPB if the patient was allocated to the ESPB group. Because a sham block was not performed in the control group, neither the patient nor physician (JWC) was blinded to group allocation. However, the surgeons, attending anesthesiologists, outcome investigators, and data analysts were blinded to group assignment, and were not involved in the ESPB procedure.

4. Ultrasound-guided ESPB

ESPB was performed by an experienced anesthesiologist (JWC) in a separate pre-anesthesia room before induc-

tion of anesthesia. After standard monitoring, including 3-lead electrocardiography, non-invasive blood pressure measurements, and pulse oximetry, the patient lay in a prone position. Bilateral T7 transverse processes (TPs) were identified using ultrasonography (Sonosite EDGE; FUJIFILM Sonosite, Bothell, WA) with a 6–13 MHz linear transducer. After sterilization with 2% chlorohexidine and alcohol, an 89-mm, 22-gauge spinal needle (Hakko Co., Ltd., Osaka, Japan) was advanced to the T7 TP using an in-plane technique in the cranio-caudal direction [16]. After the needle contacted the T7 TP on ultrasound, 1 mL of normal saline was injected to confirm lifting of the erector spinae muscle off the bony shadow of the T7 TP. Next, 30 mL of 0.375% ropivacaine was injected into the interfascial plane [20]. ESPB was performed using the same protocol on the other side. To confirm block success, a decrease in pinprick sensation at the back and axillary line of the patient was assessed using a blunt needle at 15 minute after the procedure. After confirmation of a successful block, the patient was transferred to the operating room. If a patient reported little or no change in sensation after 15 minute, he or she was excluded from the study.

5. Intraoperative management

General anesthesia was standardized and identical for all patients. Following standard monitoring, general anesthesia was commenced with intravenous (IV) propofol (2–3 mg/kg) and rocuronium bromide (0.8 mg/kg), followed by tracheal intubation. If mean blood pressure increased by 20% from baseline during tracheal intubation, 25 µg of fentanyl IV was administered. Anesthesia was maintained with sevoflurane in a 1:1 mixture of oxygen and air. Sevoflurane concentration was titrated to achieve a bispectral index of 40–60. If blood pressure decreased by 20% from baseline or the heart rate fell to < 40/min, 5 mg of ephedrine or 2.5 mg of atropine IV was administered. If blood pressure increased by 20% from baseline, 25 µg of fentanyl IV was administered. During surgery, rocuronium bromide was infused continuously at a rate of 4–7 µg/kg/min to maintain a train-of-four (TOF) count of 0. Muscle relaxation was adjusted to TOF count ≥ 3 at the time of reversal. All patients received IV hydromorphone (0.01 mg/kg) 30 minute before the end of surgery. Neuromuscular blockade was reversed with IV pyridostigmine (0.2 mg/kg) and glycopyrrolate (0.008 mg/kg), and patients were extubated when they recovered adequate muscle strength. After extubation, patients were transferred to the post-anesthesia care unit (PACU).

6. Postoperative management

Postoperative analgesia during the study period was standardized. Pain intensity was measured using a numeric rating scale (NRS; 0 = no pain, 10 = worst pain). Assessment of pain intensity was started immediately after PACU arrival and was defined as the NRS pain score at the PACU. The pain severity score was evaluated every 10 min until discharge from the PACU, and rescue analgesics (IV hydromorphone 0.01 mg/kg) were allowed with an NRS score ≥ 5. Before transferring to the general ward, IV patient-controlled analgesia (PCA; 1,000 µg fentanyl diluted with 0.9% saline to 100 mL of total volume, basal infusion rate of 1 mL/h, bolus dose of 1 mL, and lockout time of 15 minute) was started. Postoperative nausea and vomiting (PONV) was treated with 0.3 mg IV ramosetron hydrochloride (Naseron Inj.; Boryung Co., Ltd., Seoul, Korea). Nurses who were blinded to patient allocation recorded all PACU data, including rescue opioids, PONV, and pain intensity using an NRS.

During recovery in the general ward, patients who presented with breakthrough pain (NRS ≥ 5) received IV meperidine 50 mg as rescue analgesia. PONV was treated with 0.3 mg IV ramosetron hydrochloride. Postoperative management, except analgesia, followed the surgeon's protocol.

7. Outcome measurement

The primary endpoint was total fentanyl equivalent consumption during the first 24 hour postoperatively. Secondary endpoints were time to the first request for rescue analgesia in the ward; pain intensities at rest using NRS scores immediately after PACU arrival and at 3, 6, 12, and 24 hour postoperatively; incidence of PONV; and the amount of fentanyl equivalent consumption during PACU stay and at 3, 6, and 12 hour postoperatively. Since rescue analgesics were expected to be administered to almost all patients in the PACU, rescue analgesia included only the administrations in the ward except in the PACU. Fentanyl equivalent consumption included both IV-PCA and all rescue analgesics. Rescue analgesics, hydromorphone (conversion ratio of 15:1), and meperidine (conversion ratio of 750:1) were converted to a fentanyl equivalent dose for comparison [21,22]. Complications related to the procedure such as nerve injury, pneumothorax, hematoma formation, and local anesthetic systemic toxicity were evaluated during the study period.

8. Statistical analysis

Our hypothesis was that the ESPB (ESPB + IV-PCA) would

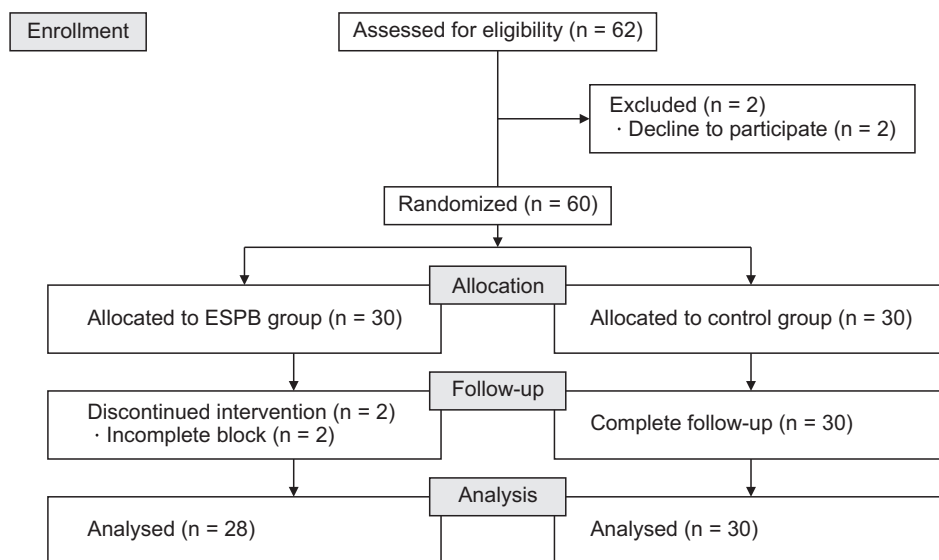


Fig. 1. CONSORT (Consolidated Standards of Reporting Trials) flow diagram of the study. ESPB: erector spinae plane block.

reduce the amount of fentanyl equivalent consumption during the first 24 hour postoperatively by 25% compared with the control (IV-PCA only), referring to a previous study [23]. With a two-tailed significance level of 0.05, a power of 80%, and an effect size of 0.81, 24 patients for each group were required to establish statistical difference between the groups. Considering a dropout rate of 20%, we included 60 patients in this study. All patients who were randomized and treated were included in the analysis based on the intention-to-treat principle.

Continuous variables were presented as mean \pm standard deviation or median (interquartile range [IQR]). Categorical variables were presented as count (%). The normal distribution of the data was verified using the Kolmogorov-Smirnov test. The differences in continuous variables between the ESPB and control groups were compared using an independent *t*-test or Mann-Whitney *U*-test, depending on the data distribution. The categorical variable was compared using the chi-square test. Corrected confidence intervals (CIs) and *P* values were calculated by Bonferroni's method for multiple testing of repeated measurement. The effect size is defined by the Hodges-Lehmann estimate for continuous variables and risk ratio for categorical variables. *P* values were two-sided, and *P* < 0.05 was considered statistically significant. We analyzed the data using SPSS (version 27.0; IBM Corp., Armonk, NY).

RESULTS

A flow diagram of the study is shown in Fig. 1. Enrollment ceased when the target sample size was obtained. Between September 2019 and December 2019, 62 patients scheduled for elective open gastrectomy were assessed for eligibil-

Table 1. Baseline characteristics of participants and operations

Characteristics	Control (n = 30)	ESPB (n = 28)
Age (yr)	55 \pm 9	52 \pm 8
Sex (M/F)	17/13	20/8
Weight (kg)	65 \pm 11	69 \pm 11
Height (cm)	165 \pm 9	167 \pm 6
Body mass index (kg/m ²)	23.8 \pm 3.0	24.5 \pm 4.0
ASA physical status (I/II/III)	16/11/3	15/13/0
Type of operation		
Total gastrectomy	6 (20.0)	9 (32.1)
Subtotal Billroth 1	17 (56.7)	11 (39.3)
Subtotal Billroth 2	7 (23.3)	8 (28.6)
Surgeon (1/2/3/4/5)	12/8/5/1/4	9/12/2/2/3
Duration of anesthesia (min)	179 \pm 41	187 \pm 42
Duration of surgery (min)	135 \pm 39	138 \pm 39
Amount of intraoperative fentanyl administration (μ g)	25 (0-25)	0 (0-25)
Duration of PACU stay (min)	67 \pm 11	68 \pm 14

Values are presented as mean \pm standard deviation, number only, number (%), or median (interquartile range).

ESPB: erector spinae plane block, ASA: American Society of Anesthesiologists, PACU: post-anesthesia care unit.

ity and contacted by the primary investigators to obtain written informed consent one day before surgery. Among 62 patients, two were excluded because of their refusal to participate. The remaining 60 patients were randomized into two groups (n = 30 each) and received their allocated treatment. Two patients in the ESPB group were excluded from follow-up because of an incomplete block. A total of 58 patients completed the study.

The baseline characteristics of the participants and operations are presented in Table 1. The amount of intraoperative fentanyl administration (median [IQR]) was 0 (0-25) μ g in the ESPB group and 25 (0-25) μ g in the control group

($P = 0.104$).

Total fentanyl equivalent consumption during the first 24 hour postoperatively was not significantly different between the ESPB and control groups ($901.0 \pm 291.5 \mu\text{g}$ vs. $956.9 \pm 294.6 \mu\text{g}$; mean difference: $-55.9 \mu\text{g}$; 95% CI, -210.2 to 98.4 ; $P = 0.471$). After Bonferroni's correction for multiple testing of repeated measurement, fentanyl equivalent consumption during PACU stay and at 3, 6, and 12 hour postoperatively was also not significantly different between the two groups. These data are shown in detail in **Table 2**. The time interval between completion of surgery and the first request for rescue analgesia in the ward was significantly longer in the ESPB group (11.2 ± 9.0 hour vs. 7.3 ± 5.1 hour; mean difference: 3.9 hour; 95% CI, 0.1 to 7.7 ; $P = 0.045$) (**Table 2**). In the ward, two patients in each group received non-steroidal anti-inflammatory drugs (NSAIDs) including ibuprofen 400 mg IV and ketorolac 30 mg IV at the attending physician's discretion. Despite use of NSAIDs, they were included in the analysis based on the

intention-to-treat principle.

Median NRS pain scores at rest were not significantly different between the ESPB and control groups except at PACU stay and 3 hour postoperatively (median [IQR], 3 [3–5] vs. 7 [6–8]; corrected $P < 0.001$, 3 [3–3] vs. 4 [3–6]; corrected $P < 0.001$; **Table 3**).

Clinical outcomes including incidence of PONV during the first 24 hour postoperatively ($P = 0.325$) and duration of hospital stay after surgery ($P = 0.948$) were not significantly different between the groups (**Table 3**). Complications related to the procedure such as nerve injury, pneumothorax, hematoma formation, and local anesthetic systemic toxicity were not reported during the study.

DISCUSSION

In this study, ultrasound-guided bilateral ESPB did not significantly reduce fentanyl equivalent consumption at

Table 2. Postoperative analgesic outcomes between the groups

Variable	Control (n = 30)	ESPB (n = 28)	Mean difference (95% or 99% ^a CI)	Corrected ^a P value
Fentanyl equivalent consumption 24 hr postoperatively (μg) ^b	956.9 \pm 294.6	901.0 \pm 291.5	-55.9 (-210.2 to 98.4)	0.471
During PACU stay ^a	49.8 \pm 16.6	39.7 \pm 14.3	-10.1 (-20.1 to 0.1) ^a	0.064 ^a
3 hr postoperatively ^a	153.3 \pm 38.1	137.3 \pm 41.3	-16.0 (-42.0 to 10.1) ^a	0.524 ^a
6 hr postoperatively ^a	272.9 \pm 85.3	252.9 \pm 83.4	-20.1 (-75.5 to 35.3) ^a	> 0.999 ^a
12 hr postoperatively ^a	497.6 \pm 173.8	471.4 \pm 153.6	-26.2 (-134.1 to 87.7) ^a	> 0.999 ^a
Time to first rescue analgesia in ward (hr) ^c	7.3 \pm 5.1	11.2 \pm 9.0	3.9 (0.1 to 7.7)	0.045

Values are presented as mean \pm standard deviation.

ESPB: erector spinae plane block, CI: confidence interval, PACU: post-anesthesia care unit.

^a99% CI and corrected P value were calculated by Bonferroni's correction for multiple testing of repeated measurement. ^bPrimary outcome: amount of fentanyl equivalent consumption includes both intravenous patient-controlled analgesia and all rescue opioids at PACU and ward. ^cThe time interval between the end of surgery and first request for rescue analgesics in the general ward.

Table 3. NRS pain scores at each time point and postoperative clinical outcomes between the groups

Variable	Control (n = 30)	ESPB (n = 28)	Effect size ^a (95% or 99% ^b CI)	Corrected ^b P value
NRS pain score				
At PACU ^{b,c}	7 (6–8)	3 (3–5)	-3 (-4 to -1) ^b	< 0.001 ^b
3 hr postoperatively ^b	4 (3–6)	3 (3–3)	-1 (-2 to 0) ^b	< 0.001 ^b
6 hr postoperatively ^b	5 (3–6)	3 (3–5)	0 (-2 to 0) ^b	0.375 ^b
12 hr postoperatively ^b	5 (3–7)	5 (3–6)	0 (-2 to 1) ^b	> 0.999 ^b
24 hr postoperatively ^b	6 (5–7)	6 (5–7)	0 (-1 to 1) ^b	> 0.999 ^b
PONV during 24 hr postoperatively	4 (13.3)	7 (25.0)	1.9 (0.6 to 5.7)	0.325
Duration of hospital stay after surgery (day)	8 (8–8)	8 (8–8)	0 (0 to 0)	0.948

Values are presented as median (interquartile range) or number (%).

NRS: numeric rating scale, ESPB: erector spinae plane block, CI: confidence interval, PACU: post-anesthesia care unit, PONV: postoperative nausea and vomiting.

^aEffect size is defined by Hodges–Lehmann estimate for NRS pain score and duration of hospital stay after surgery and risk ratio for PONV during 24 hour postoperatively. ^b99% CI and corrected P value were calculated by Bonferroni's correction for multiple testing of repeated measurement. ^cMeasured immediately after PACU arrival.

24 hour postoperatively in patients who underwent open gastrectomy. It only lowered postoperative pain intensity immediately after PACU arrival and at 3 hour postoperatively and prolonged the time to first request for rescue analgesia in the ward compared to those in the control group. These results suggest that ESPB cannot provide an efficient opioid-sparing effect for postoperative pain management after open gastrectomy.

To the best of the authors' knowledge, this is the first RCT to evaluate the opioid sparing and analgesic effects of bilateral ESPB after open gastrectomy. There have been two RCTs in which the ESPB was applied for perioperative analgesia in bariatric patients who underwent laparoscopic gastrectomy [24,25]. One study reported that ESPB in morbidly obese patients who underwent laparoscopic sleeve gastrectomy lowered postoperative pain scores and reduced perioperative opioid consumption compared with the transversus abdominis plane block and control groups [24]. The other study showed that the ESPB provided satisfactory postoperative analgesia with decreased analgesic consumption without a significant difference in postoperative pulmonary function compared with a sham block [25]. However, in our study, ESPB for postoperative pain control in open gastrectomy was not effective compared with previous laparoscopic abdominal surgeries [15,24,25]. Open gastrectomy usually requires a radical midline incision, which runs from the xiphoid process to the pubic symphysis and passes around the umbilicus, resulting in severe somatic pain. In addition, aggressive resection of the stomach and omentum leads to severe visceral damage. These aspects might explain the different results from previous studies [26].

Furthermore, although theoretically possible, the effectiveness of ESPB in visceral sensory blockage is controversial. Appropriate analgesia can be expected when local anesthetics injected under the erector spinae plane were diffused anteriorly through the connective tissues and resulted in blocking of ventral and dorsal rami of the spinal nerves and the rami communicantes that contain sympathetic nerve fibers [16,20,27,28]. However, recent cadaveric and radiologic studies have reported unpredictable spread of the anterior rami of spinal nerves after ESPB [29-31]. Inadequate blockade of anterior cutaneous branches and sympathetic components of the ESPB might have caused its insufficient analgesic effect in our study.

Considering a relatively longer duration of surgery and duration of effect of local anesthetics, the single-shot, one-level technique might also have contributed to the insufficient analgesic effects in our study. Indeed, in one study of laparoscopic bariatric surgery, the pain scores in the single-shot ESPB group were significantly lower up to 8 hour postoperatively, and the average time to the first morphine

request in the ESPB group was 7 hour [25]. Based on these results, the authors concluded that the main analgesic effect of ESPB lasts approximately 8 hour. In another study of cardiac surgery, all patients in the ESPB group reported only mild pain (NRS score ≤ 3) up to 8 hour post-extubation [32]. In our study, the ESPB lowered postoperative pain intensity up to 3 hour postoperatively compared to that in the control group. However, it did not significantly reduce total fentanyl equivalent consumption during the first 24 hour postoperatively.

Research on ESPB in open radical prostatectomy has shown similar results to our study [33]. In that study, patients received a bilateral ESPB with either local anesthetic (10 mL of 1% lidocaine + 10 mL of 0.5% bupivacaine in each side) or a placebo at the T11 level. Cumulative morphine consumption of IV-PCA during the first 24 hour postoperatively was comparable between the groups. Except for the first hour, there was no significant difference in NRS scores at rest between the groups at 3, 6, 12, 18, or 24 hour postoperatively. The authors suggested that the long duration of surgery, use of strong multimodal analgesic medication, unreliable spread of injectate to the paravertebral space and ventral rami, and insufficient visceral nerve block due to the anatomical characteristics of the lumbar erector spinae muscle as potential causes of ineffective pain control. The aforementioned factors other than the anatomical characteristics of the block site and multimodal analgesia might have affected the insignificant results of our study.

Despite the previous studies on ESPB [14,20,24], adequate volume and concentration of local anesthetics for laparotomy have not been identified. Although the concentration and volume of the local anesthetic in this study followed regimens in previous studies [14,16,20], a single-shot ESPB was ineffective in postoperative pain control after open gastrectomy. To overcome the relatively short duration of the single-shot ESPB, several recent reports have suggested that continuous ESPB prolonged analgesic duration or could be a promising alternative to epidural analgesia in pain management of cardiac or abdominal surgeries [34-37]. Therefore, further studies on spread level, optimal concentration, doses and types of local anesthetics, and efficacy of continuous infusion are needed.

This study had some limitations. First, the patient and physician performing ESPB were not blinded to the allocation because a sham block was not performed in the control group. Second, we did not confirm the exact distribution of the block area, although sensory loss was assessed 15 minute after the procedure. Because onset of the sensory block induced by 0.375% ropivacaine usually takes approximately 30 minute, it is difficult to confirm the exact blocked sensory level before induction of anesthesia.

Interfascial techniques have an inherent failure rate [38], which might have contributed to the observed results. Third, the NRS pain score measured in the PACU might not have accurately reflected pain intensity during the PACU stay because this score was evaluated immediately after PACU arrival. Fourth, we did not investigate pain during movement or patient satisfaction, limiting accurate evaluation. Finally, though it is common to prescribe non-opioid analgesics to reduce opioid consumption based on the multimodal analgesia concept, it was not performed in our protocol. If a strong multimodal analgesic regimen was used, there might not have been a difference in immediate postoperative pain intensity as well as total fentanyl equivalent consumption during the first 24 hour postoperatively between the groups.

In conclusion, we found that ultrasound-guided, single-shot ESPB did not decrease total fentanyl equivalent consumption during the first 24 hour after open gastrectomy. It only reduced immediate postoperative pain intensity compared with that of the control group. Our results suggest that single-shot ESPB is as ineffective in postoperative pain management as multimodal analgesia after open gastrectomy. Further prospective and comparative studies are required to verify this conclusion.

DATA AVAILABILITY

The datasets supporting the findings of this study are available from the corresponding author upon reasonable request.

CONFLICT OF INTEREST

No potential conflict of interest relevant to this article was reported.

FUNDING

No funding to declare.

ORCID

Heejoon Jeong, <https://orcid.org/0000-0001-5300-2550>

Ji Won Choi, <https://orcid.org/0000-0001-7403-2863>

Woo Seog Sim, <https://orcid.org/0000-0002-5346-6424>

Duk Kyung Kim, <https://orcid.org/0000-0002-6555-2100>

Yu Jeong Bang, <https://orcid.org/0000-0002-1108-1155>

Soyoon Park, <https://orcid.org/0000-0002-6221-9628>

Hyeon Yeo, <https://orcid.org/0000-0003-3187-3798>

Hara Kim, <https://orcid.org/0000-0001-6983-1572>

REFERENCES

1. Venerito M, Link A, Rokkas T, Malfertheiner P. Review: gastric cancer-Clinical aspects. *Helicobacter* 2019; 24 Suppl 1: e12643.
2. Tegels JJ, De Maat MF, Hulsewé KW, Hoofwijk AG, Stoot JH. Improving the outcomes in gastric cancer surgery. *World J Gastroenterol* 2014; 20: 13692-704.
3. Park YK, Yoon HM, Kim YW, Park JY, Ryu KW, Lee YJ, et al. Laparoscopy-assisted versus open D2 distal gastrectomy for advanced gastric cancer: results from a randomized phase II multicenter clinical trial (COACT 1001). *Ann Surg* 2018; 267: 638-45.
4. van Boekel RLM, Warlé MC, Nielen RGC, Vissers KCP, van der Sande R, Bronkhorst EM, et al. Relationship between postoperative pain and overall 30-day complications in a broad surgical population: an observational study. *Ann Surg* 2019; 269: 856-65.
5. Royse CF, Chung F, Newman S, Stygall J, Wilkinson DJ. Predictors of patient satisfaction with anaesthesia and surgery care: a cohort study using the Postoperative Quality of Recovery Scale. *Eur J Anaesthesiol* 2013; 30: 106-10.
6. Wick EC, Grant MC, Wu CL. Postoperative multimodal analgesia pain management with nonopioid analgesics and techniques: a review. *JAMA Surg* 2017; 152: 691-7.
7. Guay J, Nishimori M, Kopp S. Epidural local anaesthetics versus opioid-based analgesic regimens for postoperative gastrointestinal paralysis, vomiting and pain after abdominal surgery. *Cochrane Database Syst Rev* 2016; 7: CD001893.
8. Manion SC, Brennan TJ. Thoracic epidural analgesia and acute pain management. *Anesthesiology* 2011; 115: 181-8.
9. Wildsmith JA. Continuous thoracic epidural block for surgery: gold standard or debased currency? *Br J Anaesth* 2012; 109: 9-12.
10. Tilleul P, Aissou M, Bocquet F, Thiriat N, le Grelle O, Burke MJ, et al. Cost-effectiveness analysis comparing epidural, patient-controlled intravenous morphine, and continuous wound infiltration for postoperative pain management after open abdominal surgery. *Br J Anaesth* 2012; 108: 998-1005.
11. Rawal N. Epidural technique for postoperative pain: gold standard no more? *Reg Anesth Pain Med* 2012; 37: 310-7.
12. Machi A, Joshi GP. Interfascial plane blocks. *Best Pract Res Clin Anaesthesiol* 2019; 33: 303-15.
13. Forero M, Adhikary SD, Lopez H, Tsui C, Chin KJ. The erector spinae plane block: a novel analgesic technique in thoracic neuropathic pain. *Reg Anesth Pain Med* 2016; 41: 621-7.
14. Tulgar S, Kapakli MS, Senturk O, Selvi O, Serifsoy TE, Ozer Z. Evaluation of ultrasound-guided erector spinae plane block

- for postoperative analgesia in laparoscopic cholecystectomy: a prospective, randomized, controlled clinical trial. *J Clin Anesth* 2018; 49: 101-6.
15. Canitez A, Kozanhan B, Aksoy N, Yildiz M, Tutar MS. Effect of erector spinae plane block on the postoperative quality of recovery after laparoscopic cholecystectomy: a prospective double-blind study. *Br J Anaesth* 2021; 127: 629-35.
 16. Abu Elyazed MM, Mostafa SF, Abdelghany MS, Eid GM. Ultrasound-guided erector spinae plane block in patients undergoing open epigastric hernia repair: a prospective randomized controlled study. *Anesth Analg* 2019; 129: 235-40.
 17. Freise H, Van Aken HK. Risks and benefits of thoracic epidural anaesthesia. *Br J Anaesth* 2011; 107: 859-68.
 18. Onishi E, Toda N, Kameyama Y, Yamauchi M. Comparison of clinical efficacy and anatomical investigation between retrolaminar block and erector spinae plane block. *Biomed Res Int* 2019; 2019: 2578396.
 19. Schulz KF, Altman DG, Moher D. CONSORT 2010 Statement: updated guidelines for reporting parallel group randomised trials. *Trials* 2010; 11: 32.
 20. Kang R, Chin KJ, Gwak MS, Kim GS, Choi SJ, Kim JM, et al. Bilateral single-injection erector spinae plane block versus intrathecal morphine for postoperative analgesia in living donor laparoscopic hepatectomy: a randomized non-inferiority trial. *Reg Anesth Pain Med* 2019; 44: 1059-65.
 21. Patanwala AE, Duby J, Waters D, Erstad BL. Opioid conversions in acute care. *Ann Pharmacother* 2007; 41: 255-66. Erratum in: *Ann Pharmacother* 2007; 41: 531.
 22. Walls RM, Hockberger RS, Gausche-Hill M, Bakes K, Baren JM, Erickson TB, et al. *Rosen's emergency medicine: concepts and clinical practice*. 9th ed. Philadelphia, Elsevier. 2018, p 42.
 23. Wu Y, Liu F, Tang H, Wang Q, Chen L, Wu H, et al. The analgesic efficacy of subcostal transversus abdominis plane block compared with thoracic epidural analgesia and intravenous opioid analgesia after radical gastrectomy. *Anesth Analg* 2013; 117: 507-13.
 24. Abdelhamid BM, Khaled D, Mansour MA, Hassan MM. Comparison between the ultrasound-guided erector spinae block and the subcostal approach to the transversus abdominis plane block in obese patients undergoing sleeve gastrectomy: a randomized controlled trial. *Minerva Anesthesiol* 2020; 86: 816-26.
 25. Mostafa SF, Abdelghany MS, Abu Elyazed MM. Ultrasound-guided erector spinae plane block in patients undergoing laparoscopic bariatric surgery: a prospective randomized controlled trial. *Pain Pract* 2021; 21: 445-53.
 26. Kim MG, Kim BS, Kim TH, Kim KC, Yook JH, Kim BS. The effects of laparoscopic assisted total gastrectomy on surgical outcomes in the treatment of gastric cancer. *J Korean Surg Soc* 2011; 80: 245-50.
 27. Hong B, Bang S, Chung W, Yoo S, Chung J, Kim S. Multimodal analgesia with multiple intermittent doses of erector spinae plane block through a catheter after total mastectomy: a retrospective observational study. *Korean J Pain* 2019; 32: 206-14.
 28. Adhikary SD, Bernard S, Lopez H, Chin KJ. Erector spinae plane block versus retrolaminar block: a magnetic resonance imaging and anatomical study. *Reg Anesth Pain Med* 2018; 43: 756-62.
 29. Aponte A, Sala-Blanch X, Prats-Galino A, Masdeu J, Moreno LA, Sermeus LA. Anatomical evaluation of the extent of spread in the erector spinae plane block: a cadaveric study. *Can J Anaesth* 2019; 66: 886-93.
 30. Ivanusic J, Konishi Y, Barrington MJ. A cadaveric study investigating the mechanism of action of erector spinae blockade. *Reg Anesth Pain Med* 2018; 43: 567-71.
 31. Dautzenberg KHW, Zegers MJ, Bleeker CP, Tan ECTH, Vissers KCP, van Geffen GJ, et al. Unpredictable injectate spread of the erector spinae plane block in human cadavers. *Anesth Analg* 2019; 129: e163-6.
 32. Krishna SN, Chauhan S, Bhoi D, Kaushal B, Hasija S, Sangdup T, et al. Bilateral erector spinae plane block for acute post-surgical pain in adult cardiac surgical patients: a randomized controlled trial. *J Cardiothorac Vasc Anesth* 2019; 33: 368-75. Erratum in: *J Cardiothorac Vasc Anesth* 2022; 36: 627.
 33. Dost B, Kaya C, Ozdemir E, Ustun YB, Koksall E, Bilgin S, et al. Ultrasound-guided erector spinae plane block for postoperative analgesia in patients undergoing open radical prostatectomy: a randomized, placebo-controlled trial. *J Clin Anesth* 2021; 72: 110277.
 34. Nagaraja PS, Ragavendran S, Singh NG, Asai O, Bhavya G, Manjunath N, et al. Comparison of continuous thoracic epidural analgesia with bilateral erector spinae plane block for perioperative pain management in cardiac surgery. *Ann Card Anaesth* 2018; 21: 323-7.
 35. Bagaphou CT, Santonastaso DP, Rispoli M, Piraccini E, Fusco P, Gori F. Bilateral continuous erector spinae plane block: an alternative to epidural catheter for major open abdominal surgery. *Minerva Anesthesiol* 2020; 86: 993-4.
 36. Zullino V, Bonvicini D, Alfonsi L, Ferrarese B, Rinta-Nikkola M, Gambardella M. Bilateral continuous erector spinae plane block in open abdominal aortic aneurysm repair. *J Cardiothorac Vasc Anesth* 2020; 34: 1588-90.
 37. Leyva FM, Mendiola WE, Bonilla AJ, Cubillos J, Moreno DA, Chin KJ. Continuous erector spinae plane (ESP) block for postoperative analgesia after minimally invasive mitral valve surgery. *J Cardiothorac Vasc Anesth* 2018; 32: 2271-4.
 38. Tulgar S, Selvi O, Senturk O, Serifsoy TE, Thomas DT. Ultrasound-guided erector spinae plane block: indications, complications, and effects on acute and chronic pain based on a single-center experience. *Cureus* 2019; 11: e3815.