



A systematic review of treatment and outcomes in patients with mandibular coronoid process hyperplasia

Griet I.L. Parmentier, Margaux Nys, Laurence Verstraete, Constantinus Politis
Department of Oral and Maxillofacial Surgery, Leuven University Hospital, Leuven, Belgium

Abstract (J Korean Assoc Oral Maxillofac Surg 2022;48:133-148)

Treatment of mandibular coronoid process hyperplasia (MCPH) has been described and explored in the literature. This systematic review aims to provide a comprehensive overview of the surgical and non-surgical treatment options for MCPH in pediatric and adult populations. Three databases were searched for treatment of MCPH patients (MEDLINE, Embase, and Web of Science). Two reviewers selected case reports and case series based on titles and abstracts. Finally, 55 studies reporting a total of 127 cases were included for qualitative synthesis and data extraction. The mean age at symptom onset was 15.6 years, while the mean age at diagnosis was 23.5 years. Of the included cases, 83.7% were male, and the condition was bilateral in more than 81% of the cases. Coronoidectomy was performed in 82.7% of the included cases, while coronoidotomy was performed in 3.9% of the cases. In 85.0% of the surgically treated cases, the approach was intraoral. The mean maximal intraoperative mouth opening was 38.1 mm compared with 16.5 mm at diagnosis. The mean maximal postoperative mouth opening was 35.3 mm, and the mean follow-up period was 16.3 months. Maximum mouth opening was achieved intraoperatively, and non-surgical treatment after surgery aims to reduce the risk of relapse. Additional research with a higher level of evidence is necessary to confirm these findings.

Key words: Trismus, Physical therapy modalities, Hyperplasia, Surgical procedures

[paper submitted 2021. 9. 23 / revised 2021. 12. 15 / accepted 2022. 1. 25]

I. Introduction

The coronoid process is an anatomical part of the mandible that serves as the attachment for the temporalis muscle, buccinator muscle, and the anterior part of the masseter muscle. In classic anatomy, it is described as a sharp triangular-shaped structure in extension of the anterior border of the mandibular ramus. In reality, this structure shows great morphological variety, including hook-shaped type, triangular type, or rounded type. In the study of Lalitha and Sridevi¹, the majority (73.9%) of mandibles had the same type of coronoid process on both sides, while 26.1% of the cases showed different types on the two sides. Allometric variation can be established in

mandibular shape in humans, with taller individuals having superoinferiorly taller rami with more anteriorly-oriented and higher coronoid processes and a corresponding deeper sigmoid notch².

Mandibular coronoid process hyperplasia (MCPH) is an uncommon congenital or developmental condition that is characterized by a macroscopic increase in the size of the coronoid process with a normal histologic structure of the bone. MCPH can exist as a uni- or bilateral condition and causes a slow and progressive reduction of mouth opening. Restricted mouth opening results from impingement of the coronoid process on the medial surface of the zygomatic arch³⁻⁵. Unilateral MCPH can involve facial asymmetry with deviation toward the affected side⁵. Langenbeck was the first to report MCPH in 1853, and the first case of restricted mouth opening due to coronoid process enlargement was reported in 1899 by Jacob³. Jacob's disease refers to the condition where the coronoid process creates a new joint with the zygomatic process.

The pathogenesis of MCPH remains unclear. Several factors might be associated with development of MCPH^{6,7}. History of facial trauma and, in particular, zygomatic arch trauma is thought to be a contributing factor in some cases⁸⁻¹¹. Hall et

Griet I.L. Parmentier

Department of Oral and Maxillofacial Surgery, Leuven University Hospital, Herestraat 49, 3000 Leuven, Belgium

TEL: +32-(0)476272716

E-mail: grietparmentier@gmail.com

ORCID: <https://orcid.org/0000-0003-0510-9825>

© This is an open-access article distributed under the terms of the Creative Commons Attribution Non-Commercial License (<http://creativecommons.org/licenses/by-nc/4.0/>), which permits unrestricted non-commercial use, distribution, and reproduction in any medium, provided the original work is properly cited.

Copyright © 2022 The Korean Association of Oral and Maxillofacial Surgeons.

al.¹² hypothesized that MCPH results from a developmental bone defect in neoplastic or cartilaginous growth centers of the coronoid processes, causing continued growth and eventual hyperplasia. Endocrine stimulation also can play a role in the pathogenesis of MCPH. Chung et al.¹³ reported that two years of growth hormone therapy for children with short stature led to increase of posterior facial height and growth of the mandible. Only one case was reported on the relationship between growth hormone and growth of the coronoid process of the mandible¹⁴. However, hypotheses involving increased activity of the temporal muscles have received the most support. Temporomandibular joint (TMJ) disorders with limited mandibular movement due to disc displacement or TMJ ankylosis were considered to be related to MCPH due to compensatory hyperactivity of the temporal muscles¹⁵⁻¹⁹. Such findings also were reported in a study by Isberg et al.²⁰ with experimentally induced mandibular hypomobility in rhesus monkeys. Other findings supporting these theories are the shortened muscle tendon units, including fibrous and hypertrophic masticatory muscle tendons and hypertrophic or hypertonic temporalis muscles, in some syndromes⁵. The most common disorder associated with congenital bilateral MCPH is trismus pseudocamptodactyly syndrome (TPS)²¹. Genetic analysis of patients with TPS reveals a defective *MYH8* gene, which presumably interferes with myosin activity and, possibly, the binding of myosin to actin. This genetic defect leads to multiple muscle contractures and arthrogryposis. Other syndromes with a common finding of hypotonia can be associated with MCPH. Moebius syndrome is characterized by uni- or bilateral paralysis of the facial mimetic muscles and the lateral rectus muscle of the eye and has been associated with bilateral MCPH^{22,23}. Kabuki syndrome and Pena-Shokeir syndrome are also both associated with hypotonia of the mandibular depressors, and it was hypothesized that the absence of mandibular movements and deglutition can result in relative hyperactivity of the temporalis muscle, resulting in reactive enlargement of the coronoid process²⁴. Genetic inheritance is another factor that can contribute to the development of MCPH. An example is mucopolysaccharidoses, a lysosomal storage disease, where generalized skeletal changes in animal models are caused by the effects of glycosaminoglycan deposition with induced modification of morphology and function of osteoclasts. Possible craniofacial characteristics are macrocephaly, thickened calvarium, underdevelopment of the mandibular condyle, and MCPH²⁵.

Males are more commonly affected by MCPH than females, with a reported ratio of 5:1⁷. MCPH is alternatively

termed “coronoid impingement syndrome” (CIS)⁷. CIS is described in literature as an acquired condition after extended craniofacial and orthognathic surgery, where the coronoid process interferes with the zygomatic arch, and contraction of the temporal muscle can prevent the osteotomized mandible from further setback^{26,27}.

In addition to progressive mouth opening limitation, patients suspected of MCPH can have a hard end feel and pain in the zygomatic area with maximum mouth opening⁵. However, only a small percentage of these patients actually has symptoms. Pain or crepitation with mouth opening are present in 7% or 8% of patients, respectively²⁸. In the neonatal population, limited mouth opening can result in important sequelae, such as feeding difficulties, risk of malnutrition, and a compromised airway with apnea²².

If treated conservatively, no improvement of these symptoms can be expected, and further diagnostic modalities are indicated. Before diagnosis of this rare condition, patients might be misdiagnosed with another and more common temporomandibular disorder as listed in the Diagnostic Criteria for Temporomandibular Disorders (DC/TMD) by Schiffman et al.²⁹. The final diagnosis can be made by a thorough clinical (re)examination, combined with additional imaging. In the literature, panoramic radiograph (orthopantomogram [OPG]), cone-beam computed tomography (CBCT), computed tomography (CT), and bone scintigraphy have been used to diagnose MCPH¹⁵.

Treatment of MCPH has been described and explored substantially in the literature. Common treatment modalities for patients with MCPH include both surgical and non-surgical procedures^{4,7,8,28,30,31}. The aim of this study is to perform a systematic review on treatment modalities and outcomes for patients in pediatric and adult populations with MCPH.

II. Methods

1. Protocol design

This protocol was drafted according to the Cochrane Guidelines for review protocols (<http://training.cochrane.org/>) and was submitted in Prospero, international prospective register of systematic reviews (<http://www.crd.york.ac.uk/PROSPERO>), registration number CRD42021267132. This systematic review aims to comply with the PRISMA (Preferred Reporting Items for Systematic reviews and Meta-Analyses) statement.

2. Selection of studies

1) Criteria for considering studies for this review (PICOS)

(1) Types of participants (P)

Study populations including living infants, adolescents, and adults were considered. No restrictions were made based on race or sex. Studies on animals or study models were excluded.

(2) Types of interventions (I)

Studies describing treatment of unilateral or bilateral MCPH were included.

We did not include treatment of osteochondroma, osteoma, trauma, or oncological treatment of the coronoid process. We also did not include treatment of zygomatic malformation, hypoplasia of the masticatory muscle tendon aponeurosis, and trismus of an unknown cause.

(3) Types of controls (C)

The control for treatment of MCPH and its postoperative maximal mouth opening is preoperative maximal mouth opening.

(4) Types of outcome measures (O)

The included studies were required to provide outcome measures of postoperative mouth opening, surgical approach,

and any alternative or additional treatment.

(5) Types of studies (S)

Case reports, case series, cross-sectional observational studies, and cohort observational studies were included. No restrictions were made based on the country or date of publication. Studies in English and French were included. Review articles were excluded.

3. Search methods

According to the inclusion and exclusion criteria, studies were identified in searches in MEDLINE (via the PubMed interface), Embase (via the Embase.com interface), and Web of Science (via the Web of Science interface). The specific search string for each database is displayed in Table 1.

4. Review and selection of studies

Two authors (G.I.L.P. and M.N.) independently screened the titles and abstracts of the obtained search results. References were managed using Covidence software (Covidence systematic review software; Veritas Health Innovation, Melbourne, Australia; <https://www.covidence.org/>) for study selection and

Table 1. Database-specific search strings for MEDLINE, Embase, and Web of Science

Database	Database-specific search string				
MEDLINE	((("coronoid"[tiab] OR "coronoid process"[tiab])	AND	("therapy"[tiab] OR "therapeutics"[MeSH Terms] "surgery"[tiab] OR "surgical procedures, operative"[MeSH Terms] OR "general surgery"[MeSH Terms] "physiotherapy"[tiab] OR "physical therapy modalities"[MeSH Terms] "coronoidectomy"[tiab] OR "coronoidotomy"[tiab]))	AND	("trismus"[MeSH Terms] OR "coronoid hyperplasia"[tiab] OR "hyperplasia"[MeSH Terms] OR "enlargement"[tiab] OR "elongation"[tiab] OR "limited mouth opening"[tiab]))
Embase	'coronoid'/exp OR 'coronoid':ti,ab,kw OR 'coronoid process'/exp OR 'coronoid process':ti,ab,kw OR 'mandible'/exp OR 'mandible':ti,ab,kw	AND	'trismus'/exp OR 'trismus':ti,ab,kw OR 'coronoid hyperplasia'/exp OR 'coronoid hyperplasia':ti,ab,kw OR 'hyperplasia'/exp OR 'hyperplasia':ti,ab,kw OR 'elongation'/exp OR 'elongation':ti,ab,kw	AND	'therapy'/exp OR 'therapy':ti,ab,kw OR 'surgery'/exp OR 'surgery':ti,ab,kw OR 'physiotherapy'/exp OR 'physiotherapy':ti,ab,kw OR 'coronoidectomy'/exp OR 'coronoidectomy':ti,ab,kw OR 'surgical technique'/exp OR 'surgical technique':ti,ab,kw OR 'general surgery'/exp OR 'general surgery':ti,ab,kw
Web of Science	TS=("coronoid" OR "coronoid process")	AND	TS=("trismus" OR "coronoid hyperplasia" OR "hyperplasia" OR "elongation" OR "enlargement" OR "limited mouth opening")	AND	TS=("therapy" OR "coronoidectomy" OR "surgery" OR "physiotherapy" OR "surgical technique" OR "general surgery" OR "coronoidotomy")

deduplication, and Zotero software was used for deduplication of search results. After a first selection of articles, the authors considered and compared their selections to achieve consensus. Of the retained abstracts, the full text paper was assessed independently for eligibility. Discrepancies between reviewers were identified and resolved by discussion to reach consensus. The reasons for excluding studies at each step (either title and abstract or full text) are shown as follows.

- 1) Wrong patient population (P)
- 2) Wrong intervention (I)
- 3) Wrong outcome measures (O)
- 4) Wrong study design (S): review
- 5) Full text not available
- 6) Wrong route of administration
- 7) Wrong language

5. Data extraction and management

Study characteristics and outcome data were extracted by one reviewer (G.I.L.P.). The data extraction table summarizes data on study population characteristics such as age of symptom onset, age of administration, age of diagnosis, diagnostic tools, preoperative maximal mouth opening, treatment, treatment results, and follow-up period.

6. Quality assessment of studies

The quality of the selected articles was assessed by the reviewer using the items and questions in Table 2. The used tool was based on the Quality Assessment Tool for Case Series Studies by NHLBI (National Heart, Lung, and Blood Institute; <https://www.nhlbi.nih.gov/health-topics/study-quality-assessment-tools>).

7. Statistical analysis for study characteristics

Data were collected using Microsoft Excel 2010 (Micro-

soft, Redmond, WA, USA) and analyzed using IBM SPSS Statistics for Windows (ver. 26; IBM, Armonk, NY, USA). Descriptive statistics were calculated.

III. Results

1. Selection of studies

The database search rendered 270 records: 23 records in MEDLINE, 156 records in Embase, and 91 records in Web of Science. After deduplication, 179 records were screened based on title and abstract by two reviewers. After achieving consensus regarding selection of articles, 107 full text papers were evaluated independently for eligibility. Finally, 55 studies reporting 127 cases were included for qualitative synthesis and data extraction.(Fig. 1)

2. Quality and characteristics of the included studies

1) Quality assessment of the included studies

A quality assessment was performed for each included study. As shown in Table 3^{3,6-10,14-17,22-25,30-70}, all case reports or case series were verified and assessed for the provided information regarding the study objective. All studies were checked and scored if a case or several cases were fully described or defined with sufficient details to allow the practitioner to make inferences related to their own practice. The description of the treatment of MCPH, the outcome measures, and the follow-up were verified and scored for every case. In general, all studies had a clear objective, although the case definition was not mentioned in 3 studies, and the intervention was not clearly described in 9 studies. Four studies lacked follow-up reports, 10 studies did not describe the cases with sufficient details, and the outcome measures were not sufficiently reported in 11 studies. No studies were excluded due to quality issues. All case reports and case series were included to provide as much information as possible

Table 2. Quality assessment tool for case studies

Question	+	?	-
1. Was the study question or objective clearly stated?			
2. Was the study case clearly and fully described, including a case definition?			
3. Was the intervention clearly described?			
4. Was follow-up long enough for outcomes to occur?			
5. Is the case(s) described with sufficient details to allow other investigators to make inferences related to their own practice?			
6. Were the outcome measures clearly defined, valid, and reliable?			

(+: yes, ?: unclear, -: no)

Griet I.L. Parmentier et al: A systematic review of treatment and outcomes in patients with mandibular coronoid process hyperplasia. J Korean Assoc Oral Maxillofac Surg 2022

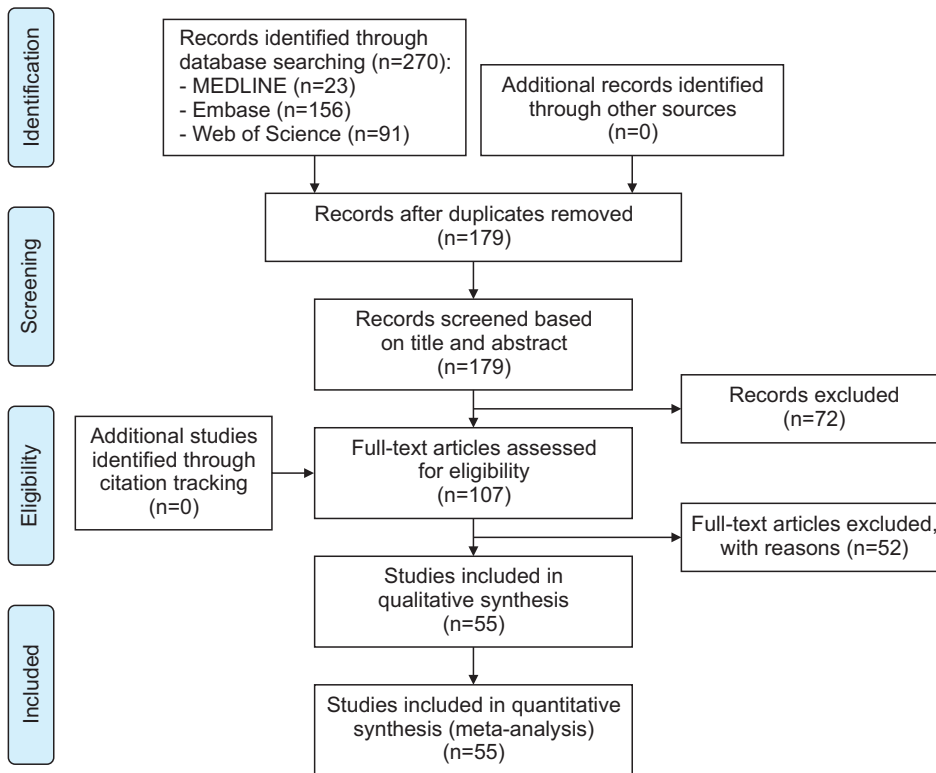


Fig. 1. PRISMA (Preferred Reporting Items for Systematic reviews and Meta-Analyses) flowchart of the literature search and study selection process. Griet I.L. Parmentier et al: A systematic review of treatment and outcomes in patients with mandibular coronoid process hyperplasia. *J Korean Assoc Oral Maxillofac Surg* 2022

concerning this condition and its treatment.

2) Study characteristics

Results on case reports and case series are displayed alphabetically in Table 4^{3,6-10,14-17,22-25,30-70}.

Case populations were considered and described. The age of onset (when the first symptoms were noticed), age at diagnosis, and sex were collected. In addition, the used imaging techniques, maximal mouth opening at diagnosis, possible causes, and the side of coronoid hyperplasia were recorded. The mean and standard deviation age of onset was 15.6 ± 10.3 years, while the mean age at diagnosis was 23.5 ± 14.0 years. In 33.86% of the cases, the age of onset for restricted mouth opening was not clearly specified, while the age at diagnosis was not mentioned in 4 cases. Approximately 81.1% of the patients with MCPH were male, while 15.7% were female; in four cases, the sex was not mentioned. The mean maximal mouth opening was 16.5 ± 7.16 mm at diagnosis. In 10 cases, the maximal mouth opening at diagnosis was not reported. MCPH was bilateral in 81.1% of the cases and unilateral in 18.9% of the cases.

The type of surgical procedure and the surgical approach were recorded, as was maximal intraoperative mouth opening. Coronoidectomy was performed in 82.7% ($n=105$), coronoidotomy in 3.9% ($n=5$) and no surgery was performed

in 9.4% ($n=12$) of the cases. In five cases (3.9%), the surgical intervention was not described. In the cases where surgical intervention was executed and reported, surgery was performed by an intraoral approach in 82.7% ($n=72$), extraoral approach in 9.2% ($n=8$), and combined intraoral and extraoral approach in 8% ($n=7$) of the cases. The mean maximal intraoperative mouth opening was 38.1 ± 9.24 mm compared with 16.5 ± 7.16 mm at diagnosis.

The type of postoperative supportive intervention and follow-up period were recorded, and postoperative mouth opening and maximum mouth opening were reported. Postoperative supportive physiotherapy was applied in 91.8% ($n=101$) of the cases.

In 16 cases (12.5%), the type of postoperative supportive therapy was not described. The Therabite appliance (TheraBite Jaw Motion Rehabilitation System; Atos Medical AB, Hörby, Sweden) was used in 23.4% ($n=26$) of the cases that reported postoperative physiotherapy. Although Therabite was preferred in a substantial amount of cases to maintain and improve the postoperative result, no study could confirm the superiority of one specific type of postoperative physiotherapy⁴. The mean maximal postoperative mouth opening was 35.0 ± 9.6 mm after postoperative supportive therapy. The mean postoperative follow-up period was 16.1 months, with a range between 1.0 and 72.0 months.

Table 3. Quality assessment for every included case report or case series

No.	Study	1	2	3	4	5	6
1	Acharya et al. ⁷ (2017)	+	?	+	+	+	+
2	Akan and Mehreliyeva ³² (2006)	+	?	+	?	?	+
3	Baraldi et al. ³³ (2010)	+	+	+	+	+	+
4	Bayar et al. ⁹ (2012)	+	+	+	?	?	-
5	Bronstein and Osborne ³⁴ (1984)	+	+	-	+	?	+
6	Capote et al. ³⁵ (2005)	+	+	+	+	-	-
7	Choi et al. ³⁶ (2013)	+	+	?	+	?	+
8	Colquhoun et al. ³⁷ (2002)	+	-	?	?	-	-
9	Costa et al. ¹⁶ (2012)	+	+	+	+	+	+
10	de la Torre et al. ³⁸ (2001)	+	?	+	?	?	-
11	Duffy ³⁹ (1980)	+	?	+	+	-	-
12	Fernández Ferro et al. ³⁰ (2008)	+	?	+	+	+	+
13	Fitzpatrick ⁴⁰ (1970)	+	?	+	+	+	+
14	Galiè et al. ⁴¹ (2010)	+	?	+	+	+	+
15	Gerbino et al. ⁴² (1997)	+	?	+	+	+	+
16	Ghazizadeh et al. ⁶ (2017)	+	?	+	+	-	-
17	Giacomuzzi et al. ⁴³ (1986)	+	+	+	+	+	+
18	Gibbons et al. ⁶⁶ (2001)	+	?	+	?	?	?
19	Gibbons and Abulhou ³¹ (2007)	+	?	+	+	+	?
20	Hayter and Robertson ⁴⁴ (1989)	+	+	+	+	-	+
21	Huang et al. ⁴⁵ (2020)	+	?	-	+	-	+
22	Inoue et al. ⁴⁶ (2020)	+	?	+	+	?	+
23	Khadembaschi et al. ²⁵ (2020)	?	+	+	+	+	+
24	Kim et al. ¹⁵ (2014)	?	+	-	+	v	+
25	Kraut ⁴⁷ (1985)	+	+	+	+	+	+
26	Kreutz and Sanders ⁴⁸ (1985)	+	?	+	+	+	+
27	Lee and Chung ¹⁴ (2012)	+	+	-	+	-	+
28	Leovic et al. ⁴⁹ (2006)	+	+	?	?	?	?
29	Loh et al. ⁵⁰ (1997)	+	?	+	?	?	+
30	Lucaya et al. ⁵¹ (1982)	+	?	-	?	?	?
31	Mano et al. ⁵² (2005)	+	+	+	+	+	+
32	McLoughlin et al. ⁸ (1995)	+	?	+	?	?	-
33	Monevska et al. ⁵³ (2016)	+	+	+	?	?	+
34	Monks ⁵⁴ (1978)	+	+	+	+	+	+
35	Puche et al. ²⁴ (2012)	+	+	+	+	?	+
36	Ramalho-Ferreira et al. ⁵⁵ (2011)	+	+	+	+	+	+
37	Romano et al. ⁵⁶ (2017)	?	-	+	+	-	-
38	Rowe ⁵⁷ (1963)	?	+	+	-	+	-
39	Satoh et al. ⁵⁸ (2006)	?	+	+	+	+	+
40	Schneble et al. ⁵⁹ (2019)	+	+	-	+	?	+
41	Shurman ⁶⁷ (1975)	+	+	-	-	?	?
42	Smyth and Wake ¹⁰ (1994)	?	+	+	+	+	+
43	Starch-Jensen and Kjellerup ³ (2017)	+	+	+	+	+	+
44	Tavassol et al. ⁶⁰ (2012)	+	+	-	-	?	?
45	Tieghi et al. ⁷⁰ (2005)	+	+	+	+	+	+
46	Totsuka and Fukuda ⁶⁸ (1991)	+	+	+	+	+	+
47	Tucker et al. ⁶¹ (1984)	?	+	+	+	+	+
48	Turk et al. ²³ (1999)	+	-	-	?	-	+
49	Utsman et al. ⁶⁹ (2013)	+	+	?	?	?	-
50	Wallender et al. ²² (2015)	+	+	+	-	+	+
51	Wenghoefer et al. ⁶² (2008)	+	+	+	?	-	-
52	Yamaguchi et al. ⁶³ (1998)	+	+	+	+	+	+
53	Yoshida et al. ⁶⁴ (2008)	?	+	+	+	?	+
54	Yura et al. ⁶⁵ (2009)	+	+	+	+	+	+
55	Zhong et al. ¹⁷ (2009)	?	+	+	+	+	+

Refer to Table 2 for the content of questions 1 to 6.

Griet I.L. Parmentier et al: A systematic review of treatment and outcomes in patients with mandibular coronoid process hyperplasia. J Korean Assoc Oral Maxillofac Surg 2022

IV. Discussion

Progressive limitation of maximal mouth opening is the hallmark of MCPH. Restricted mouth opening, a hard end feel when opening the mouth, pain or slight asymmetry in the

zygomatic area, and no improvement of symptoms despite repeated conservative treatment are clinical signs suspicious for MCPH¹⁵. Patients with mouth opening limitation who have no symptoms related to a temporomandibular or masticatory muscle disorder after initial clinical and radiographic exami-

Table 4. Overview of included case reports and case series

Study	Possible cause	Age of onset (yr)	Age at diagnosis (yr)	Sex	Diagnostic imaging	Mouth opening diagnosis (mm)	Coronoid hyperplasia	Surgical intervention	Surgical approach	Intraoperative mouth opening (mm)	Supportive postoperative intervention	Postoperative mouth opening (mm)	Follop-up (mo)
Acharya et al. ⁷ (2017)	NA	13	16	M	OPG, MRI, CT	15	Bilateral	Coronoidectomy	Intraoral	NA	Therabite	27	3
Akan and Mehreliyeva ³² (2006)	NA	20	24	M	MRI, CT	15	Bilateral	Coronoidectomy	Intraoral	NA	Physiotherapy	30	NA
Baraldi et al. ³³ (2010)	Fetal trauma (twin)	Since adolescence	21	F	MRI, CT	12	Right	Coronoidectomy	Intraoral	30	Physiotherapy	35	7
Bayar et al. ⁹ (2012)	Trauma 19 yr	19	21	M	OPG, CT	23	Right	Coronoidectomy	Extraoral (preauricular)+ intraoral	NA	Physiotherapy	38	NA
Bronstein and Osborne ³⁴ (1984)	Trauma 2 yr	NA	20	M	OPG, tomo, fluoro	20	Bilateral	Coronoidectomy	NA	30	Physiotherapy, ultrasound, pulsed galvanic stimulation	39	3
Capote et al. ³⁵ (2005)	Trauma 2 yr	17	23	F	OPG, CT	30	Unilateral	Coronoidectomy+ arthroscopy	Intraoral	NA	Physiotherapy	NA	12
Choi et al. ³⁶ (2013)	No history	12	13	M	CT, MRI	15	Bilateral	Coronoidectomy	Intraoral	45	NA	40	4
Choi et al. ³⁶ (2013)	NA	13	13	M	OPG, MRI, CT	20	Bilateral	Coronoidectomy	Intraoral	50	NA	45	6
Choi et al. ³⁶ (2013)	NA	16	16	M	OPG	15	Bilateral	Redo coronoidectomy	Intraoral	45	NA	42	12
Colquhoun et al. ³⁷ (2002)	Trauma 29 yr	29	32	M	OPG, CT	21	Bilateral	Right coronoidectomy	Intraoral	NA	NA	NA	18
Colquhoun et al. ³⁷ (2002)	NA	23	26	M	OPG, CT	22	Bilateral	Coronoidectomy	Intraoral	35	NA	22	30
Costa et al. ¹⁶ (2012)	No history	NA	18	M	OPG, CBCT, MRI	20	Bilateral	Coronoidectomy	Intraoral	NA	Physiotherapy	50	5
de la Torre et al. ³⁸ (2001)	NA	17	19	M	Tomo, RX	7	Left	Coronoidectomy	Intraoral	NA	Physiotherapy	NA	NA
de la Torre et al. ³⁸ (2001)	NA	14	16	NA	OPG, CT	14	Bilateral	Coronoidectomy	Intraoral	55	NA	22	4
de la Torre et al. ³⁸ (2001)	NA	16	16	NA	Unknown	25	Bilateral	Coronoidectomy+ debridement and stretching	Intraoral	52	Physiotherapy	49	12
Duffy ³⁹ (1980)	NA	NA	15	M	Unknown	8	Bilateral	Coronoidectomy	Intraoral	30	Physiotherapy	NA	30
Fernández Ferro et al. ³⁰ (2008)	NA	NA	28	M	OPG, CT	13	Bilateral	Coronoidectomy	Intraoral	NA	Therabite	40	12
Fitzpatrick ⁴⁰ (1970)	NA	18	27	M	Tomo	5	Bilateral	Coronoidectomy	Intraoral	22	Physiotherapy	40	24
Galiè et al. ⁴¹ (2010)	NA	A few months old	3	F	CT	5	Unilateral left	Coronoidectomy+ fasciotomy and myotomy	Extraoral (coronal)	NA	Physiotherapy	30	18
Gerbino et al. ⁴² (1997)	NA	14	15	M	OPG, Water's view, CT	15	Unilateral right	Right coronoidotomy	Intraoral	46	Physiotherapy	41	12

Table 4. Continued

Study	Possible cause	Age of onset (yr)	Age at diagnosis (yr)	Sex	Diagnostic imaging	Mouth opening diagnosis (mm)	Coronoid hyperplasia	Surgical intervention	Surgical approach	Intraoperative mouth opening (mm)	Supportive postoperative intervention	Postoperative mouth opening (mm)	Follop-up (mo)
Gerbino et al. ⁴² (1997)	NA	15	32	M	OPG, Water's view, CT	20	Bilateral	Coronoidotomy	Intraoral	42	Physiotherapy	38	60
Gerbino et al. ⁴² (1997)	NA	12	14	M	OPG, Water's view, CT	12	Unilateral right	Right coronoidotomy	Intraoral	46	Physiotherapy	48	60
Gerbino et al. ⁴² (1997)	NA	10	13	M	OPG, Water's view, CT	18	Bilateral	Coronoidotomy	Intraoral	40	Physiotherapy	38	15
Gerbino et al. ⁴² (1997)	NA	14	16	M	OPG, Water's view, CT	20	Bilateral	Coronoidotomy	Intraoral	38	Physiotherapy	45	60
Ghazizadeh et al. ⁶ (2017)	NA	Childhood	30	M	OPG, CT	21	Bilateral	Coronoidectomy	Intraoral	NA	Physiotherapy	NA	3
Giacomuzzi ⁴³ (1986)	No history	11	19	M	OPG, tomo	11	Bilateral	No surgery (refused by patient)	No surgery	No surgery	NA	No surgery	No surgery
Gibbons et al. ⁶⁶ (2001)	NA	16	28	M	OPG, CT	15	Bilateral	Coronoidectomy	Right extraoral, left intraoral	30	Interdental screw appliance	40	NA
Gibbons and Abulhoul ³¹ (2007)	NA	16	36	M	OPG, CT	20	Bilateral	Coronoidectomy	Intraoral	30	Therabite	38	12
Hayter and Robertson ⁴⁴ (1989)	No history	15	16	M	RX	22	Bilateral	Coronoidectomy	Bicoronal	NA	Physiotherapy	NA	1
Huang et al. ⁴⁵ (2020)	NA	When she was young	59	F	OPG, CT, MRI	25	Bilateral	Coronoidectomy	NA	41	NA	30	15
Inoue et al. ⁴⁶ (2020)	NA	Junior high school	In his 50s	M	OPG, CT	18	Bilateral	Coronoidectomy	Intraoral	NA	Physiotherapy	30	6
Khadembaschi et al. ²⁵ (2020)	Mucopolysaccharidosis	12	14	M	CT	8	Bilateral	Coronoidectomy, removal of zygomatic arch exostoses	Intraoral+ bicoronal	40	Therabite	45	18
Kim et al. ¹⁵ (2014)	NA	13	43	M	OPG, MRI, CT	25	Bilateral	No surgery (refused by patient)	No surgery	No surgery	NA	No surgery	No surgery
Kim et al. ¹⁵ (2014)	NA	NA	21	M	MRI, CT	28	Right	Coronoidectomy	NA	43	Physiotherapy	63	15
Kim et al. ¹⁵ (2014)	NA	15	19	M	MRI, CT	32	Bilateral	Coronoidectomy	NA	35	Physiotherapy	65	18
Kim et al. ¹⁵ (2014)	NA	18	18	M	CT	12	Right	Coronoidectomy	NA	NA	Physiotherapy	54	15
Kraut ⁴⁷ (1985)	NA	NA	38	F	OPG	14	Bilateral	Coronoidectomy	Intraoral	43	Physiotherapy	27	11
Kraut ⁴⁷ (1985)	NA	17	17	M	OPG, CT	19	Bilateral	Coronoidectomy	Intraoral	40	Physiotherapy	40	2
Kreutz and Sanders ⁴⁸ (1985)	NA	44	54	F	OPG, Water's view	16	Bilateral	Coronoidectomy	Submandibular	50	Physiotherapy	45	24
Lee and Chung ¹⁴ (2012)	Somatropin	12	17	M	OPG, CBCT	10	Bilateral	Coronoidectomy	left submandibular, right intraoral	53	NA	40	1
Leovic et al. ⁴⁹ (2006)	NA	17	35	M	CT	15	Bilateral	Coronoidectomy	NA	NA	Physiotherapy	35	NA

Table 4. Continued

Study	Possible cause	Age of onset (yr)	Age at diagnosis (yr)	Sex	Diagnostic imaging	Mouth opening diagnosis (mm)	Coronoid hyperplasia	Surgical intervention	Surgical approach	Intraoperative mouth opening (mm)	Supportive postoperative intervention	Postoperative mouth opening (mm)	Follop-up (mo)
Loh et al. ⁵⁰ (1997)	NA	12	14	M	RX	13	Bilateral	Coronoidectomy	Intraoral	22	Physiotherapy	37	3
Loh et al. ⁵⁰ (1997)	NA	NA	41	M	NA	15	Bilateral	Coronoidectomy	Intraoral	25	Physiotherapy	25	NA
Loh et al. ⁵⁰ (1997)	NA	18	22	M	NA	5	Bilateral	Coronoidectomy	Extraoral	NA	Physiotherapy	20	NA
Loh et al. ⁵⁰ (1997)	NA	NA	25	F	NA	16	Bilateral	Coronoidectomy	Intraoral	NA	Physiotherapy	30	NA
Lucaya et al. ⁵¹ (1982)	NA	9	9	F	RX	22	Right	Coronoidectomy	NA	NA	NA	Normal	NA
Mano et al. ⁵² (2005)	No history	5	6	M	OPG, tomo, CT	17	Bilateral	Coronoidectomy	Intraoral	NA	Physiotherapy	40	72
McLoughlin et al. ⁸ (1995)	NA	1	7	M	NA	12	Bilateral	Coronoidectomy	Intraoral	NA	Physiotherapy	17	NA
McLoughlin et al. ⁸ (1995)	NA	7	8	F	NA	15	Bilateral	Coronoidectomy	Intraoral	NA	Physiotherapy	39	NA
McLoughlin et al. ⁸ (1995)	NA	12	13	M	NA	22	Bilateral	No surgery	No surgery	NA	Physiotherapy	NA	NA
McLoughlin et al. ⁸ (1995)	NA	8	13	M	NA	NA	Bilateral	Coronoidectomy	Intraoral	NA	Physiotherapy	NA	NA
McLoughlin et al. ⁸ (1995)	NA	11	13	M	NA	14	Bilateral	Coronoidectomy	Intraoral	NA	Physiotherapy	29	NA
McLoughlin et al. ⁸ (1995)	NA	17	17	M	NA	13	Bilateral	Coronoidectomy	Intraoral	NA	Physiotherapy	38	NA
McLoughlin et al. ⁸ (1995)	NA	NA	18	M	NA	NA	Bilateral	Coronoidectomy	Intraoral	NA	Physiotherapy	NA	NA
McLoughlin et al. ⁸ (1995)	NA	13	18	M	NA	19	Bilateral	Coronoidectomy	Intraoral	NA	Physiotherapy	35	NA
McLoughlin et al. ⁸ (1995)	NA	13	18	M	NA	21	Bilateral	Coronoidectomy	Intraoral	NA	Physiotherapy	33	NA
McLoughlin et al. ⁸ (1995)	NA	14	19	M	NA	NA	Bilateral	No surgery	No surgery	NA	Physiotherapy	NA	NA
McLoughlin et al. ⁸ (1995)	NA	1	21	M	NA	10	Bilateral	Coronoidectomy	Intraoral	NA	Physiotherapy	21	NA
McLoughlin et al. ⁸ (1995)	NA	21	25	M	NA	NA	Bilateral	Coronoidectomy	Intraoral	NA	Physiotherapy	NA	NA
McLoughlin et al. ⁸ (1995)	NA	31	31	M	NA	29	Bilateral	No surgery	No surgery	NA	Physiotherapy	NA	NA
McLoughlin et al. ⁸ (1995)	NA	24	34	M	NA	22	Bilateral	Coronoidectomy	Intraoral	NA	Physiotherapy	29	NA
McLoughlin et al. ⁸ (1995)	NA	22	33	F	NA	4	Bilateral	Coronoidectomy	Intraoral	NA	Physiotherapy	35	NA
McLoughlin et al. ⁸ (1995)	NA	NA	33	M	NA	17	Bilateral	No surgery	No surgery	NA	Physiotherapy	NA	NA
McLoughlin et al. ⁸ (1995)	NA	34	34	M	NA	22	Bilateral	No surgery	No surgery	NA	Physiotherapy	40	NA
McLoughlin et al. ⁸ (1995)	NA	26	36	M	NA	13	Bilateral	Coronoidectomy	Intraoral	NA	Physiotherapy	28	NA
McLoughlin et al. ⁸ (1995)	NA	16	36	M	NA	48	Bilateral	No surgery	No surgery	NA	Physiotherapy	NA	NA
McLoughlin et al. ⁸ (1995)	NA	23	43	M	NA	18	Bilateral	Coronoidectomy	Intraoral	NA	Physiotherapy	NA	NA

Table 4. Continued

Study	Possible cause	Age of onset (yr)	Age at diagnosis (yr)	Sex	Diagnostic imaging	Mouth opening diagnosis (mm)	Coronoid hyperplasia	Surgical intervention	Surgical approach	Intraoperative mouth opening (mm)	Supportive postoperative intervention	Postoperative mouth opening (mm)	Follo-up (mo)
McLoughlin et al. ⁸ (1995)	NA	36	44	M	NA	NA	Bilateral	NA	NA	NA	Physiotherapy	NA	NA
McLoughlin et al. ⁸ (1995)	NA	NA	47	F	NA	21	Bilateral	No surgery	No surgery	NA	Physiotherapy	NA	NA
McLoughlin et al. ⁸ (1995)	NA	58	78	M	NA	13	Bilateral	Coronoidectomy	Intraoral	NA	Physiotherapy	29	NA
McLoughlin et al. ⁸ (1995)	NA	2	3	M	NA	13	Unilateral	Coronoidectomy	Intraoral	NA	Physiotherapy	14	NA
McLoughlin et al. ⁸ (1995)	NA	13	15	M	NA	22	Unilateral	Coronoidectomy	Intraoral	NA	Physiotherapy	40	NA
McLoughlin et al. ⁸ (1995)	NA	14	18	M	NA	20	Unilateral	Coronoidectomy	Intraoral	NA	Physiotherapy	25	NA
McLoughlin et al. ⁸ (1995)	NA	7	19	M	NA	19	Unilateral	Coronoidectomy	Extraoral	NA	Physiotherapy	24	NA
McLoughlin et al. ⁸ (1995)	NA	NA	29	M	NA	NA	Unilateral	NA	NA	NA	Physiotherapy	NA	NA
McLoughlin et al. ⁸ (1995)	NA	16	31	M	NA	25	Unilateral	Coronoidectomy	Intraoral	NA	Physiotherapy	38	NA
McLoughlin et al. ⁸ (1995)	NA	20	32	M	NA	17	Unilateral	Coronoidectomy	Intraoral	NA	Physiotherapy	25	NA
McLoughlin et al. ⁸ (1995)	NA	40	42	F	NA	18	Unilateral	Coronoidectomy	Intraoral	NA	Physiotherapy	NA	NA
Monevska et al. ⁵³ (2016)	NA	NA	3	F	OPG, CT	2	Bilateral	Coronoidectomy	Intraoral	30	Therabite	25	NA
Monks ⁵⁴ (1978)	Difficult extraction	11	50	M	RX	8	Bilateral	Coronoidectomy	Intraoral right, extraoral left	20	Physiotherapy	20	24
Puche et al. ²⁴ (2012)	Kabuki syndrome	Congenital	0.67	M	CT	9	Bilateral	Coronoidectomy	Intraoral	22	Physiotherapy	24	27
Puche et al. ²⁴ (2012)	Pena-Shokeir syndrome	Congenital	0.83	M	CT	11	Bilateral	Coronoidectomy	Intraoral	24	Physiotherapy	24	25
Ramalho-Ferreira et al. ⁵⁵ (2011)	No history	23	26	M	OPG, CT	19	Bilateral	Coronoidectomy	Intraoral	29	Physiotherapy	31	30
Romano et al. ⁵⁶ (2017)	NA	NA	37	M	OPG, MRI, CT	16	Bilateral	Coronoidectomy	Intraoral	39	Physiotherapy+ Therabite	39	12
Romano et al. ⁵⁶ (2017)	NA	NA	25	M	OPG, MRI, CT	20	Bilateral	Coronoidectomy	Intraoral	38	Physiotherapy+ Therabite	40	12
Romano et al. ⁵⁶ (2017)	NA	NA	43	M	OPG, MRI, CT	13	Bilateral	Coronoidectomy	Intraoral	41	Physiotherapy+ Therabite	39	12
Romano et al. ⁵⁶ (2017)	NA	NA	27	M	OPG, MRI, CT	19	Bilateral	Coronoidectomy	Extraoral	47	Physiotherapy+ Therabite	45	12
Romano et al. ⁵⁶ (2017)	NA	NA	29	M	OPG, MRI, CT	13	Bilateral	Coronoidectomy	Extraoral (preauricular)	38	Physiotherapy+ Therabite	43	12
Romano et al. ⁵⁶ (2017)	NA	NA	23	M	OPG, MRI, CT	17	Bilateral	Coronoidectomy	Extraoral (preauricular)	39	Physiotherapy+ Therabite	40	12
Rowe et al. ⁵⁷ (1963)	No history	12	15	M	RX	15	Bilateral	Coronoidectomy	Intraoral	NA	Mechanical exerciser	35	14

Table 4. Continued

Study	Possible cause	Age of onset (yr)	Age at diagnosis (yr)	Sex	Diagnostic imaging	Mouth opening diagnosis (mm)		Surgical intervention	Surgical approach	Intraoperative mouth opening (mm)	Supportive postoperative intervention	Postoperative mouth opening (mm)	Follop-up (mo)
						Opening	Diagnosis						
Rowe et al. ⁵⁷ (1963)	No history	13	15	M	RX	10	Bilateral	No surgery (refused by patient)	No surgery	No surgery	NA	No surgery	36
Sato et al. ⁵⁸ (2006)	No history	12	13	M	OPG, CBCT	27	Bilateral	Coronoidectomy	Intraoral	40	Physiotherapy	45	8
Schneble et al. ⁵⁹ (2019)	No history	0	4	M	CT	15	Bilateral	Coronoidectomy	NA	25	None	15	60
Shurman ⁶⁷ (1975)	Facial injury 2 yr prior	42	44	M	RX	22	Bilateral	Coronoidectomy	NA	22	Physiotherapy	40-50	Next few weeks
Smyth and Wake ¹⁰ (1994)	Adenoidectomy	8	15	M	RX, CT	4	Bilateral	Coronoidectomy	Intraoral+bicoronal	50	Physiotherapy	23	12
Smyth and Wake ¹⁰ (1994)	Adenoidectomy	8	23	M	OPG, CT	11	Bilateral	Redo coronoidectomy	Intraoral+bicoronal	40	Physiotherapy	50	12
Starch-Jensen and Kjellerup ³ (2017)	No history	NA	18	M	OPG, CBCT	22	Bilateral	Coronoidectomy	Intraoral	42	Physiotherapy+ Therabite (not motivated)	32	3
Tavassol et al. ⁶⁰ (2012)	NA	11	13	M	CT, MRI	10	Bilateral	Coronoidectomy	Intraoral	48	NA	Still normal	NA
Tieghi et al. ⁷⁰ (2005)	Trauma, age 4 yr	13	15	M	CT	25	Bilateral	Coronoidectomy	Intraoral	40	Bite block, physiotherapy (butterfly jaw exerciser)	46	6
Tieghi et al. ⁷⁰ (2005)	No history	NA	17	F	OPG, CT	25	Bilateral	Coronoidectomy	Intraoral	40	Bite block, physiotherapy (butterfly jaw exerciser)	40	20
Totsuka and Fukuda ⁶⁸ (1991)	No history	14	17	M	RX, OPG, CT	17	Bilateral	Coronoidectomy	Intraoral	45	Physiotherapy+ mechanical extenser	52	10
Totsuka and Fukuda ⁶⁸ (1991)	No history	10	13	M	RX, CT	29	Bilateral	Coronoidectomy	Intraoral	48	Physiotherapy	45	3
Tucker et al. ⁶¹ (1984)	No history	14	16	M	OPG, tomo, CT	22	Unilateral right	Coronoidectomy	Intraoral	40	Physiotherapy	44	3
Turk et al. ²³ (1999)	Moebius syndrome	At birth	1.5	M	CT	8	Bilateral	Coronoidectomy	Intraoral	NA	NA	25	4
Turk et al. ²³ (1999)	Moebius syndrome	At birth	NA	NA	CT	10	Bilateral	Coronoidectomy	Intraoral	30	NA	40	NA
Utsman et al. ⁶⁹ (2013)	NA	9	12	M	CBCT	15	Bilateral (right>left)	NA	NA	NA	Daily exercises	NA	2
Wallender et al. ²² (2015)	Prematurity, duplication of chromosome 7P21.1	0	0.16	M	CT	4	Bilateral	Coronoidectomy	Intraoral	25	Jaw physiotherapy	25	1 wk
Wenghoefer et al. ⁶² (2008)	NA	NA	2	F	NA	10	Bilateral	Coronoidectomy	NA	NA	Physiotherapy+ Therabite	25	NA
Wenghoefer et al. ⁶² (2008)	AS	NA	45	M	NA	10	Bilateral	Coronoidectomy	NA	NA	Physiotherapy+ Therabite	31	NA
Wenghoefer et al. ⁶² (2008)	NA	NA	16	M	NA	14	Bilateral	Coronoidectomy	NA	NA	Physiotherapy+ Therabite	40	NA

Table 4. Continued

Study	Possible cause	Age of onset (yr)	Age at diagnosis (yr)	Sex	Diagnostic imaging	Mouth opening diagnosis (mm)	Coronoid hyperplasia	Surgical intervention	Surgical approach	Intraoperative mouth opening (mm)	Supportive postoperative intervention	Postoperative mouth opening (mm)	Follop-up (mo)
Wenghoefer et al. ⁶² (2008)	NA	NA	18	M	NA	16	Bilateral	Coronoidectomy	NA	NA	Physiotherapy+ Therabite	>30	NA
Wenghoefer et al. ⁶² (2008)	NA	NA	24	M	NA	18	Bilateral	Coronoidectomy	NA	NA	Physiotherapy+ Therabite	40	NA
Wenghoefer et al. ⁶² (2008)	NA	NA	5	F	NA	4	Bilateral	Coronoidectomy	NA	NA	Physiotherapy+ Therabite	32	NA
Wenghoefer et al. ⁶² (2008)	CNS disorder, hypertonic muscles	NA	35	M	NA	5	Bilateral	Coronoidectomy	NA	NA	Physiotherapy+ Therabite	31	NA
Wenghoefer et al. ⁶² (2008)	NA	NA	23	M	NA	10	Bilateral	Coronoidectomy	NA	NA	Physiotherapy+ Therabite	23	NA
Wenghoefer et al. ⁶² (2008)	AS	NA	38	M	NA	7	Right	Coronoidectomy	NA	NA	Physiotherapy+ Therabite	35	NA
Wenghoefer et al. ⁶² (2008)	NA	NA	53	F	NA	NA	Left	Coronoidectomy	NA	NA	Physiotherapy+ Therabite	>30	NA
Wenghoefer et al. ⁶² (2008)	NA	NA	4	M	NA	NA	Bilateral	Coronoidectomy	NA	NA	Physiotherapy+ Therabite	>30	NA
Wenghoefer et al. ⁶² (2008)	NA	NA	14	M	NA	15	Bilateral	Coronoidectomy	NA	NA	Physiotherapy+ Therabite	33	NA
Wenghoefer et al. ⁶² (2008)	CNS disorder, hypertonic muscles	NA	28	M	NA	NA	Bilateral	Coronoidectomy	NA	NA	Physiotherapy+ Therabite	>30	NA
Wenghoefer et al. ⁶² (2008)	NA	NA	18	F	NA	NA	Left	Coronoidectomy	NA	NA	Physiotherapy+ Therabite	>30	NA
Wenghoefer et al. ⁶² (2008)	AS	NA	52	M	NA	22	Left	NA	NA	NA	NA	NA	NA
Wenghoefer et al. ⁶² (2008)	AS	NA	56	M	NA	25	Bilateral	NA	NA	NA	NA	NA	NA
Yamaguchi et al. ⁶³ (1998)	NA	17	25	M	CT	24	Left	Coronoidectomy	Intraoral	NA	Physiotherapy	43	8
Yoshida et al. ⁶⁴ (2008)	Bilateral hypertrophy of masseter muscles	28	34	F	RX, CT, MRI	18	Bilateral	Redo coronoidectomy	Intraoral	44	NA	38	6
Yura et al. ⁶⁵ (2009)	No history	15	28	M	OPG, CT	30	Left	Coronoidectomy	Intraoral	50	Physiotherapy+ mouth opening exerciser	43	15
Zhong et al. ¹⁷ (2009)	No history	26	39	F	OPG, CT	8	Bilateral	Coronoidectomy	Intraoral	40	Physiotherapy	31	9

(NA: not available or not correctly reported, M: male, F: female, OPG: orthopantomography, MRI: magnetic resonance imaging, CT: computed tomography, tomo: tomography, fluoro: fluoroscopy, CBCT: cone-beam computed tomography, RX: X-ray, AS: ankylosing spondylitis, CNS: central nerve system)
 Griet LL, Parmentier et al.: A systematic review of treatment and outcomes in patients with mandibular coronoid process hyperplasia. J Korean Assoc Oral Maxillofac Surg 2022

nations should undergo CT for a more accurate diagnosis.

A considerable difference between the age of onset of the first symptoms and the age of diagnosis is noted in the literature^{4,5}. We confirm these findings with a mean difference of 7.92 years in our study. As a rare condition with often painless progressive restricted mouth opening, MCPH is prone to underreporting, misdiagnosis, and delayed diagnosis⁵⁹. In patients with limited mouth opening, temporomandibular disorders typically are considered first³².

In 1963, Rowe⁵⁷ was the first to classify MCPH as uni- or bilateral. Izumi et al.⁷¹ classified MCPH into three categories (high, middle, low) by radiologically evaluating the tip of the coronoid process in relation to the zygomatic arch.

A coronoid/condyle ratio of <1.0 has been proposed as the definition of normal anatomy⁶⁰. A CT scan can provide detailed imaging of the coronoid process and its anatomical relation with the zygomatic bone. A scan performed in the maximal mouth opening position can be useful to locate the exact location of interference and can provide added value in surgical planning^{32,58}.

Evaluation of the coronoid process is commonly performed based on CT images. Due to development in radiographic imaging, lower-dose CBCT is more frequently performed and can also be used for this assessment⁶⁰.

Osteochondromas or osteomas can cause unilateral coronoid hyperplasia and might present with similar symptoms, but their radiological and histological characteristics reveal difference from true MCPH. These neoplasms of the coronoid process should not be termed unilateral coronoid hyperplasia since there are no histological features of neoplasia in MCPH, but they show histologically normal bone with abnormal bony elongation^{4,28,72}. In most patients diagnosed with unilateral MCPH, some abnormality was also detected on the contralateral coronoid process⁸.

The aim of treatment of MCPH is restoration of mouth opening and maintenance of a long-term and stable result³⁰. Ineffective long-term conservative treatment from misdiagnosis of MCPH can lead to unsatisfied patients and patient discomfort with loss of quality of life but also to important health risks¹⁵. Therefore, an early diagnosis of this entity is important. A point of interest is that TMD and MCPH can co-exist in the same patient and lead to undiagnosed MCPH¹⁷. The treatment of coronoid process hyperplasia is primarily surgical, since the problem is mechanical due to interference by the zygomatic arch^{16,56}.

Coronoidectomy was the treatment of choice in 95.6% of the included surgically treated cases in this study. This proce-

dures involves removal of the osteotomized coronoid process and stripping of the insertion of the temporalis muscle. Some authors preferred coronoidotomy with the osteotomized coronoid segment remaining *in situ*. This technique shows a good outcome, but a limited number of cases have been reported. Coronoidotomy requires less tissue manipulation, reducing tissue damage and scarring and is considered less invasive^{4,65}. To avoid reattachment of the osteotomized coronoid process, Chen et al.⁷³ modified their surgical technique by performing a gap coronoidotomy.

The intraoral surgical approach is preferred in most cases. It has the advantages of providing sufficient access in most cases without producing an extraoral scar and reduces the risk of damage to the branches of the facial nerve. The complications are postoperative hematoma formation and postoperative fibrosis^{8,15}. An endoscopically-assisted approach can reduce the complications associated with the intraoral approach⁷⁴.

The extraoral coronal approach allows the ability to resect the inferior muscle belly of the temporalis muscle more thoroughly, since aberrant activity of the temporalis muscle can contribute to development of MCPH⁴¹.

It can be difficult to determine the best timing of surgery for MCPH in infants or children. If surgery is performed at an early age, clinical improvement of trismus will be achieved, although postoperative recurrence and dysgnathia are possible⁵². However, most authors agree that, except in patients with very severe limitation of mouth opening, it is best to perform the operation once growth has finished to avoid recurrence, deformity, or restricted mobility of the mandible^{75,76}. Thus, in mild cases, surgical intervention should be delayed until skeletal maturity⁶⁹. Relapse can be induced by persistent underlying causes of coronoid hypertrophy, postoperative fibrosis, or an inadequate physiotherapy program⁵⁹. Change in muscular activity due to detachment of the temporalis muscle and postoperative fibrosis can lead to displacement of the mandible, malocclusion, and an anterior open bite^{42,62,65}.

After surgical intervention, continuous and active postoperative physiotherapy is key for successful treatment with a long-term result^{15,59}. Obtaining a satisfactory outcome depends largely on proper postoperative rehabilitation. Regular and long-term follow-up is important to assure patient compliance and postoperative physiotherapy. Regrowth of the previously resected coronoid process, hematoma formation, or fibrosis can lead to an unsatisfactory prognosis^{15,34,41}. It is recommended to start physiotherapy between three days and seven days postoperatively^{56,77}. Active physiotherapy should

be continued for at least 6 months for satisfactory results. Postoperative cases with limited mouth opening caused by fibrosis secondary to incorrect reorganization of a hematoma at the site of operation and even recurrence in the growth of the coronoid process have been described. Regrowth of a hyperplastic coronoid process can be explained by fibrosis of a postoperative hematoma showing pathological calcification^{10,75}. Poor compliance for postoperative physiotherapy is associated with increased risk of relapse. Compliance for physiotherapy has a bimodal distribution; patients younger than 2 years old and older than 16 years had better postoperative results²². Lefavre and Aitchison⁷⁸ noted that long-term physiotherapy might be the most important variable in long-term postoperative results and advised postponing intervention in children until optimal cooperation is possible.

Therabite and other appliances have been used to improve limited mouth opening and also to stretch fibrotic tissue around the jaws and prevent further trismus³¹. Importantly, the use of a Therabite in treatment of uni- or bilateral MCPH is only useful as a supportive treatment after surgical intervention, since the responsible mechanical obstruction needs to be removed to obtain acceptable maximal mouth opening. Postoperatively, patients must be educated about the importance of physiotherapy and the use of the Therabite device since postoperative tissue scarring can compromise the obtained maximal mouth opening^{5,30,66}.

In the literature, the results after coronoidectomy were generally disappointing²⁸. However, one must consider the definition of a disappointing result. The DC/TMD protocol considers an unassisted maximal mouth opening of 35 mm or greater or an assisted maximal mouth opening of 40 mm or greater to be a normal interincisal distance²⁹. Others considered a mouth opening of 30 mm or greater to be a successful result. However, the postoperative result in studies varies in a range of 30-35 mm and is not consistent to calculate an overall success rate. More important is the clinical result and subjective patient satisfaction and quality of life, which are not always proportionate to the objective findings. Notably, in most studies, it is not mentioned if the reported maximal mouth opening is assisted or unassisted. A more uniform system to report these measures would be helpful to investigate these findings more thoroughly.

In this review, we included only case reports and case studies, which might contribute to reporting bias. Additional research including more cases with a higher level of evidence is necessary to confirm these findings.

ORCID

Griet I.L. Parmentier, <https://orcid.org/0000-0003-0510-9825>
Margaux Nys, <https://orcid.org/0000-0002-2510-8777>
Laurence Verstraete, <https://orcid.org/0000-0001-5912-0320>
Constantinus Politis, <https://orcid.org/0000-0003-4772-9897>

Authors' Contributions

G.I.L.P. and C.P. participated in data collection and G.I.L.P. wrote the manuscript. G.I.L.P. and L.V. participated in the study design and performed the statistical analysis. G.I.L.P. and M.N. participated in the study design and coordination and helped to draft the manuscript. All authors read and approved the final manuscript.

Conflict of Interest

No potential conflict of interest relevant to this article was reported.

References

1. Lalitha B, Sridevi NS. Variations in the shape of coronoid process of Indian adult dry human mandibles. *Int J Sci Stud* 2016;4:22-5.
2. Nicholson E, Harvati K. Quantitative analysis of human mandibular shape using three-dimensional geometric morphometrics. *Am J Phys Anthropol* 2006;131:368-83. <https://doi.org/10.1002/ajpa.20425>
3. Starch-Jensen T, Kjellerup AD. Bilateral elongated mandibular coronoid process and restricted mouth opening: a case report. *Open Dent J* 2017;11:670-8. <https://doi.org/10.2174/1874210601711010670>
4. Goh YC, Tan CC, Lim D. Coronoid hyperplasia: a review. *J Stomatol Oral Maxillofac Surg* 2020;121:397-403. <https://doi.org/10.1016/j.jormas.2019.12.019>
5. Mulder CH, Kalaykova SI, Gortzak RA. Coronoid process hyperplasia: a systematic review of the literature from 1995. *Int J Oral Maxillofac Surg* 2012;41:1483-9. <https://doi.org/10.1016/j.ijom.2012.03.029>
6. Ghazizadeh M, Sheikhi M, Salehi MM, Khaleghi A. Bilateral coronoid hyperplasia causing painless limitation of mandibular movement. *Radiol Case Rep* 2017;13:112-7. <https://doi.org/10.1016/j.radcr.2017.11.001>
7. Acharya P, Stewart A, Naini FB. Coronoid impingement syndrome: literature review and clinical management. *Maxillofac Plast Reconstr Surg* 2017;39:11. <https://doi.org/10.1186/s40902-017-0111-7>
8. McLoughlin PM, Hopper C, Bowley NB. Hyperplasia of the mandibular coronoid process: an analysis of 31 cases and a review of the literature. *J Oral Maxillofac Surg* 1995;53:250-5. [https://doi.org/10.1016/0278-2391\(95\)90219-8](https://doi.org/10.1016/0278-2391(95)90219-8)
9. Bayar GR, Akcam T, Gulses A, Sencimen M, Gunhan O. An excessive coronoid hyperplasia with suspected traumatic etiology resulting in mandibular hypomobility. *Cranio* 2012;30:144-9. <https://doi.org/10.1179/crn.2012.021>
10. Smyth AG, Wake MJ. Recurrent bilateral coronoid hyperplasia: an unusual case. *Br J Oral Maxillofac Surg* 1994;32:100-4. [https://doi.org/10.1016/0266-4356\(94\)90138-4](https://doi.org/10.1016/0266-4356(94)90138-4)

11. Praal FR. Limitation of mandibular movement due to bilateral mandibular coronoid process enlargement. *J Oral Maxillofac Surg* 1984;42:534-6. [https://doi.org/10.1016/0278-2391\(84\)90013-2](https://doi.org/10.1016/0278-2391(84)90013-2)
12. Hall RE, Orbach S, Landesberg R. Bilateral hyperplasia of the mandibular coronoid processes: a report of two cases. *Oral Surg Oral Med Oral Pathol* 1989;67:141-5. [https://doi.org/10.1016/0030-4220\(89\)90318-6](https://doi.org/10.1016/0030-4220(89)90318-6)
13. Chung SH, Kim JW, Park YH, Hwang CJ, Lee HK. The effect of growth hormone treatment on craniofacial growth in short stature children. *Korean J Orthod* 2010;40:227-38. <https://doi.org/10.4041/kjod.2010.40.4.227>
14. Lee ST, Chung IK. Severe trismus due to bilateral coronoid process hyperplasia in growth hormone therapy patient: a case report. *J Korean Assoc Oral Maxillofac Surg* 2012;38:249-54. <https://doi.org/10.5125/jkaoms.2012.38.4.249>
15. Kim SM, Lee JH, Kim HJ, Huh JK. Mouth opening limitation caused by coronoid hyperplasia: a report of four cases. *J Korean Assoc Oral Maxillofac Surg* 2014;40:301-7. <https://doi.org/10.5125/jkaoms.2014.40.6.301>
16. Costa YM, Porporatti AL, Stuginski-Barbosa J, Cassano DS, Bonjardim LR, Conti PC. Coronoid process hyperplasia: an unusual cause of mandibular hypomobility. *Braz Dent J* 2012;23:252-5. <https://doi.org/10.1590/s0103-64402012000300012>
17. Zhong SC, Xu ZJ, Zhang ZG, Zheng YH, Li TX, Su K. Bilateral coronoid hyperplasia (Jacob disease on right and elongation on left): report of a case and literature review. *Oral Surg Oral Med Oral Pathol Oral Radiol Endod* 2009;107:e64-7. <https://doi.org/10.1016/j.tripleo.2008.10.017>
18. Farrar WB, McCarty WL Jr. Inferior joint space arthrography and characteristics of condylar paths in internal derangements of the TMJ. *J Prosthet Dent* 1979;41:548-55. [https://doi.org/10.1016/0022-3913\(79\)90092-1](https://doi.org/10.1016/0022-3913(79)90092-1)
19. Isberg A, Eliasson S. A cephalometric analysis of patients with coronoid process enlargement and locking. *Am J Orthod Dentofacial Orthop* 1990;97:35-40. [https://doi.org/10.1016/S0889-5406\(05\)81706-8](https://doi.org/10.1016/S0889-5406(05)81706-8)
20. Isberg AM, McNamara JA Jr, Carlson DS, Isacson G. Coronoid process elongation in rhesus monkeys (*Macaca mulatta*) after experimentally induced mandibular hypomobility. A cephalometric and histologic study. *Oral Surg Oral Med Oral Pathol* 1990;70:704-10. [https://doi.org/10.1016/0030-4220\(90\)90004-c](https://doi.org/10.1016/0030-4220(90)90004-c)
21. Jaskolka MS, Eppley BL, van Aalst JA. Mandibular coronoid hyperplasia in pediatric patients. *J Craniofac Surg* 2007;18:849-54. <https://doi.org/10.1097/scs.0b013e3180a772ba>
22. Wallender A, Ahson I, Steinberg B. Neonatal coronoid hyperplasia: a report of a case and concepts to promote early diagnosis and treatment. *J Oral Maxillofac Surg* 2015;73:1615.e1-7. <https://doi.org/10.1016/j.joms.2015.03.014>
23. Turk AE, McCarthy JG, Nichter LS, Thorne CH. Moebius syndrome: the new finding of hypertrophy of the coronoid process. *J Craniofac Surg* 1999;10:93-6.
24. Puche M, Guijarro-Martínez R, Pérez-Herrezuelo G, Miragall L, Iglesias ME, Martínez-Costa C. The hypothetical role of congenital hypotonia in the development of early coronoid hyperplasia. *J Craniofac Surg* 2012;40:e155-8. <https://doi.org/10.1016/j.jcms.2011.08.005>
25. Khadembaschi D, Arvier J, Beech N, Dolan D, McGill J. Successful management of severe coronoid process hyperplasia in a patient with mucopolysaccharidosis VI: a case report. *J Surg Case Rep* 2020;2020:rjz388. <https://doi.org/10.1093/jscr/rjz388>
26. Greives MR, Figueroa AA, Reid RR. Successful treatment of post-operative mouth opening limitation following le fort III distraction with bilateral coronoidectomies. *J Maxillofac Oral Surg* 2016;15:127-30. <https://doi.org/10.1007/s12663-015-0798-x>
27. Hwang K, Kim DH. Oblique osteotomy and coronoidectomy in extreme prognathism of Apert syndrome. *J Craniofac Surg* 2010;21:555-6. <https://doi.org/10.1097/SCS.0b013e3181d02558>
28. Wenghoefer M, Martini M, Anwander T, Götz W, Reich R, Bergé SJ. [Hyperplasia of the coronoid process: diagnosis and treatment]. *Mund Kiefer Gesichtschir* 2006;10:409-14. German. <https://doi.org/10.1007/s10006-006-0028-2>
29. Schiffman E, Ohrbach R, Truelove E, Look J, Anderson G, Goulet JP, et al. Diagnostic criteria for temporomandibular disorders (DC/TMD) for clinical and research applications: recommendations of the International RDC/TMD Consortium Network and Orofacial Pain Special Interest Group. *J Oral Facial Pain Headache* 2014;28:6-27. <https://doi.org/10.11607/jop.1151>
30. Fernández Ferro M, Fernández Sanromán J, Sandoval Gutierrez J, Costas López A, López de Sánchez A, Etayo Pérez A. Treatment of bilateral hyperplasia of the coronoid process of the mandible. Presentation of a case and review of the literature. *Med Oral Patol Oral Cir Bucal* 2008;13:E595-8.
31. Gibbons AJ, Abulhoul S. Use of a Therabite appliance in the management of bilateral mandibular coronoid hyperplasia. *Br J Oral Maxillofac Surg* 2007;45:505-6. <https://doi.org/10.1016/j.bjoms.2006.05.005>
32. Akan H, Mehreliyeva N. The value of three-dimensional computed tomography in diagnosis and management of Jacob's disease. *Dentomaxillofac Radiol* 2006;35:55-9. <https://doi.org/10.1259/dmfr/52275596>
33. Baraldi CE, Martins GL, Puricelli E. Pseudoankylosis of the temporomandibular joint caused by zygomatic malformation. *Int J Oral Maxillofac Surg* 2010;39:729-32. <https://doi.org/10.1016/j.ijom.2010.02.013>
34. Bronstein SL, Osborne JJ. Mandibular limitation due to bilateral coronoid enlargement: management by surgery and physical therapy. *Cranio* 1984;3:58-62. <https://doi.org/10.1080/08869634.1984.11678086>
35. Capote A, Rodríguez FJ, Blasco A, Muñoz MF. Jacob's disease associated with temporomandibular joint dysfunction: a case report. *Med. Oral Patol Oral Cir Bucal* 2005;10:210-4.
36. Choi JG, Kim SY, Perez-Atayde AR, Padwa BL. Bilateral coronoid process hyperplasia with pseudocartilaginous joint formation: Jacob disease. *J Oral Maxillofac Surg* 2013;71:316-21. <https://doi.org/10.1016/j.joms.2012.05.029>
37. Colquhoun A, Cathro I, Kumara R, Ferguson MM, Doyle TC. Bilateral coronoid hyperplasia in two brothers. *Dentomaxillofac Radiol* 2002;31:142-6. <https://doi.org/10.1038/sj.dmfr.4600672>
38. de la Torre OE i, Vert Klok e, Roig AM i, Mommaerts MY, Ayats JP i. Jacob's disease: report of two cases and review of the literature. *J Craniofac Surg* 2001;29:372-6. <https://doi.org/10.1054/jcms.2001.0247>
39. Duffy BL. Case report--bilateral mandibular coronoid process hyperplasia. *Anaesth Intensive Care* 1980;8:484-6. <https://doi.org/10.1177/0310057X8000800418>
40. Fitzpatrick BN. Bilateral hyperplasia of the mandibular coronoid process. *Oral Surg Oral Med Oral Pathol* 1970;29:184-90. [https://doi.org/10.1016/0030-4220\(70\)90079-4](https://doi.org/10.1016/0030-4220(70)90079-4)
41. Galiè M, Consorti G, Tieghi R, Denes SA, Fainardi E, Schmid JL, et al. Early surgical treatment in unilateral coronoid hyperplasia and facial asymmetry. *J Craniofac Surg* 2010;21:129-33. <https://doi.org/10.1097/SCS.0b013e3181c46a30>
42. Gerbino G, Bianchi SD, Bernardi M, Berrone S. Hyperplasia of the mandibular coronoid process: long-term follow-up after coronoidotomy. *J Craniofac Surg* 1997;25:169-73. [https://doi.org/10.1016/s1010-5182\(97\)80010-8](https://doi.org/10.1016/s1010-5182(97)80010-8)
43. Giacomuzzi D. Bilateral enlargement of the mandibular coronoid processes: review of the literature and report of case. *J Oral Maxillofac Surg* 1986;44:728-31.
44. Hayter JP, Robertson JM. Surgical access to bilateral coronoid hyperplasia using the bicoronal flap. *Br J Oral Maxillofac Surg* 1989;27:487-93. [https://doi.org/10.1016/s0266-4356\(89\)80007-5](https://doi.org/10.1016/s0266-4356(89)80007-5)
45. Huang W, Akashi M, Nishio T, Negi N, Kimoto A, Hasegawa T. Can four-dimensional computed tomography support diagnosis and treatment planning?: a case report before and after coronoidectomy.

- Oral Maxillofac Surg 2020;24:515-20. <https://doi.org/10.1007/s10006-020-00876-1>
46. Inoue K, Nakano H, Yonenaga T, Ogura A, Omori M, Yamamoto N, et al. A case of coronoidectomy simulated using threedimensional models and surgical guide for severe trismus caused by bilateral coronoid hyperplasia. *J Oral Maxillofac Surg Med Pathol* 2020;32:450-3. <https://doi.org/10.1016/j.ajoms.2020.06.002>
 47. Kraut RA. Bilateral coronoid hyperplasia: report of two cases. *J Oral Maxillofac Surg* 1985;43:612-4. [https://doi.org/10.1016/0278-2391\(85\)90130-2](https://doi.org/10.1016/0278-2391(85)90130-2)
 48. Kreutz RW, Sanders B. Bilateral coronoid hyperplasia resulting in severe limitation of mandibular movement. Report of a case. *Oral Surg Oral Med Oral Pathol* 1985;60:482-4. [https://doi.org/10.1016/0030-4220\(85\)90233-6](https://doi.org/10.1016/0030-4220(85)90233-6)
 49. Leovic D, Djanic D, Zubcic V. Mandibular locking due to bilateral coronoid process hyperplasia. *Wien Klin Wochenschr* 2006;118:594. <https://doi.org/10.1007/s00508-006-0663-5>
 50. Loh HS, Ling SY, Lian CB, Shanmuhasuntharam P. Bilateral coronoid hyperplasia--a report with a view on its management. *J Oral Rehabil* 1997;24:782-7. <https://doi.org/10.1046/j.1365-2842.1997.00561.x>
 51. Lucaya J, Herrera M, Vera J. Unilateral hyperplasia of the coronoid process in a child: a cause of restricted opening of the mouth. *Radiology* 1982;144:528. <https://doi.org/10.1148/radiology.144.3.7100466>
 52. Mano T, Ueyama Y, Koyama T, Nishiyama A, Matsumura T. Trismus due to bilateral coronoid hyperplasia in a child: case report. *J Oral Maxillofac Surg* 2005;63:399-401. <https://doi.org/10.1016/j.joms.2004.07.018>
 53. Monevska DP, Benedetti A, Popovski V, Naumovski S, Grcev A, Bozovic S, et al. Mandibular movement restoration in a child with bilateral coronoid hyperplasia: a case report. *Open Access Maced J Med Sci* 2016;4:293-5. <https://doi.org/10.3889/oamjms.2016.049>
 54. Monks FT. Bilateral hyperplasia of the mandibular coronoid processes: a case report. *Br J Oral Surg* 1978;16:31-7. [https://doi.org/10.1016/s0007-117x\(78\)80053-5](https://doi.org/10.1016/s0007-117x(78)80053-5)
 55. Ramalho-Ferreira G, Faverani LP, Fabris AL, Pastori CM, Magro-Filho O, Ponzoni D, et al. Mandibular movement restoration through bilateral coronoidectomy by intraoral approach. *J Craniofac Surg* 2011;22:988-91. <https://doi.org/10.1097/SCS.0b013e3182101674>
 56. Romano M, Porcellini G, Rossi D, Bolzoni A, Gianni AB, Silvestre FJ, et al. Bilateral coronoid hyperplasia: a report of six cases. *J Biol Regul Homeost Agents* 2017;31(2 Suppl 1):139-45.
 57. Rowe NL. Bilateral developmental hyperplasia of the mandibular coronoid process. A report of two cases. *Br J Oral Surg* 1963;1:90-104. [https://doi.org/10.1016/s0007-117x\(63\)80056-6](https://doi.org/10.1016/s0007-117x(63)80056-6)
 58. Satoh K, Ohno S, Aizawa T, Imamura M, Mizutani H. Bilateral coronoid hyperplasia in an adolescent: report of a case and review of the literature. *J Oral Maxillofac Surg* 2006;64:334-8. <https://doi.org/10.1016/j.joms.2005.10.032>
 59. Schneble EJ, Moore RD, Pettersson DR, Pollock JM, Barajas RF Jr. Coronoid process hyperplasia: a rare disorder masquerading as temporomandibular joint disease. *Clin Neuroradiol* 2019;29:787-9. <https://doi.org/10.1007/s00062-019-00778-0>
 60. Tavassol F, Spalthoff S, Essig H, Bredt M, Gellrich NC, Kokemüller H. Elongated coronoid process: CT-based quantitative analysis of the coronoid process and review of literature. *Int J Oral Maxillofac Surg* 2012;41:331-8. <https://doi.org/10.1016/j.ijom.2011.10.033>
 61. Tucker MR, Guilford WB, Howard CW. Coronoid process hyperplasia causing restricted opening and facial asymmetry. *Oral Surg Oral Med Oral Pathol* 1984;58:130-2. [https://doi.org/10.1016/0030-4220\(84\)90124-5](https://doi.org/10.1016/0030-4220(84)90124-5)
 62. Wenghoefer M, Martini M, Allam JP, Novak N, Reich R, Bergé SJ. Hyperplasia of the coronoid process in patients with ankylosing spondylitis (Bechterew disease). *J Craniofac Surg* 2008;19:1114-8. <https://doi.org/10.1097/SCS.0b013e318176ac3b>
 63. Yamaguchi T, Komatsu K, Yura S, Totsuka Y, Nagao Y, Inoue N. Electromyographic activity of the jaw-closing muscles before and after unilateral coronoidectomy performed on a patient with coronoid hyperplasia: a case study. *Cranio* 1998;16:275-82. <https://doi.org/10.1080/08869634.1998.11746068>
 64. Yoshida H, Sako J, Tsuji K, Nakagawa A, Inoue A, Yamada K, et al. Securing the coronoid process during a coronoidotomy. *Int J Oral Maxillofac Surg* 2008;37:181-2. <https://doi.org/10.1016/j.ijom.2007.07.021>
 65. Yura S, Ohga N, Ooi K, Izumiyama Y. Mandibular coronoid hyperplasia: a case report. *Cranio* 2009;27:275-9. <https://doi.org/10.1179/crn.2009.039>
 66. Gibbons AJ, Byrne AJ, Key SJ. Trismus due to bilateral mandibular coronoid hyperplasia. *J R Army Med Corps* 2001;147:311-3. <https://doi.org/10.1136/jramc-147-03-11>
 67. Shurman J. Bilateral hypertrophy of the coronoid processes. *Anesthesiology* 1975;42:491-2. <https://doi.org/10.1097/0000542-197504000-00022>
 68. Totsuka Y, Fukuda H. Bilateral coronoid hyperplasia. Report of two cases and review of the literature. *J Craniofac Surg* 1991;19:172-7. [https://doi.org/10.1016/s1010-5182\(05\)80308-7](https://doi.org/10.1016/s1010-5182(05)80308-7)
 69. Utsman RA, Klasser GD, Padilla M. Coronoid hyperplasia in a pediatric patient: case report and review of the literature. *J Calif Dent Assoc* 2013;41:766-70.
 70. Tieghi R, Galiè M, Piersanti L, Clauser L. Bilateral hyperplasia of the coronoid processes: clinical report. *J Craniofac Surg* 2005;16:723-6. <https://doi.org/10.1097/01.scs.0000157202.81438.ea>
 71. Izumi M, Isobe M, Toyama M, Arijii Y, Gotoh M, Naitoh M, et al. Computed tomographic features of bilateral coronoid process hyperplasia with special emphasis on patients without interference between the process and the zygomatic bone. *Oral Surg Oral Med Oral Pathol Oral Radiol Endod* 2005;99:93-100. <https://doi.org/10.1016/j.tripleo.2004.04.013>
 72. Kubota Y, Takenoshita Y, Takamori K, Kanamoto M, Shirasuna K. Levandoski panoramic analysis in the diagnosis of hyperplasia of the coronoid process. *Br J Oral Maxillofac Surg* 1999;37:409-11. <https://doi.org/10.1054/bjom.1999.0159>
 73. Chen CM, Chen CM, Ho CM, Huang IY. Gap coronoidotomy for management of coronoid process hyperplasia of the mandible. *Oral Surg Oral Med Oral Pathol Oral Radiol Endod* 2011;112:e1-4. <https://doi.org/10.1016/j.tripleo.2011.03.040>
 74. Robiony M, Casadei M, Costa F. Minimally invasive surgery for coronoid hyperplasia: endoscopically assisted intraoral coronoidectomy. *J Craniofac Surg* 2012;23:1838-40. <https://doi.org/10.1097/SCS.0b013e3182645ebf>
 75. Newaskar V, Idrees F, Patel P. Unilateral coronoid hyperplasia treated by coronoidectomy using a transzygomatic approach. *Natl J Maxillofac Surg* 2012;3:195-8. <https://doi.org/10.4103/0975-5950.111380>
 76. Rivas PH. Reduction of mouth opening due to mandibular coronoid process enlargement. Report of a case. *Oral Surg Oral Med Oral Pathol* 1979;47:131-4. [https://doi.org/10.1016/0030-4220\(79\)90166-x](https://doi.org/10.1016/0030-4220(79)90166-x)
 77. van Hoof RF, Besling WF. Coronoid process enlargement. *Br J Oral Surg* 1973;10:339-48. [https://doi.org/10.1016/s0007-117x\(72\)80065-9](https://doi.org/10.1016/s0007-117x(72)80065-9)
 78. Lefaiivre JF, Aitchison MJ. Surgical correction of trismus in a child with Hecht syndrome. *Ann Plast Surg* 2003;50:310-4. <https://doi.org/10.1097/01.sap.0000046787.17899.83>

How to cite this article: Parmentier GIL, Nys M, Verstraete L, Politis C. A systematic review of treatment and outcomes in patients with mandibular coronoid process hyperplasia. *J Korean Assoc Oral Maxillofac Surg* 2022;48:133-148. <https://doi.org/10.5125/jkaoms.2022.48.3.133>