

Case Report

pISSN 2466-1384 · eISSN 2466-1392
Korean J Vet Res 2022;62(2):e12
<https://doi.org/10.14405/kjvr.20210051>

*Corresponding author:

Seong Mok Jeong
Department of Veterinary Surgery, College of Veterinary Medicine, Chungnam National University, 99 Daehak-ro, Yuseong-gu, Daejeon 34134, Korea
Tel: +82-42-821-6763
Fax: +82-42-821-6703
E-mail: jsmok@cnu.ac.kr

ORCID:

<https://orcid.org/0000-0001-8653-5927>

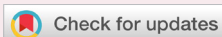Conflict of interest:

The authors declare no conflict of interest.

Received: Dec 7, 2021

Revised: Apr 14, 2022

Accepted: Apr 15, 2022



© 2022 The Korean Society of Veterinary Science.

© This is an open-access article distributed under the terms of the Creative Commons Attribution Non-Commercial license (<http://creativecommons.org/licenses/by-nc/4.0/>), which permits unrestricted non-commercial use, distribution, and reproduction in any medium, provided the original work is properly cited.

Pseudohyperkalemia after total splenectomy in a dog: a case report

Chang-Hwan Moon¹, Je Hun Lee¹, You-Jeong Jeong¹, Young-Sam Kwon², Haebeom Lee¹, Dae-Hyun Kim¹, Seong Mok Jeong^{1,*}

¹Department of Veterinary Surgery, College of Veterinary Medicine, Chungnam National University, Daejeon 34134, Korea

²Department of Veterinary Surgery, College of Veterinary Medicine, Kyungpook National University, Daegu 41566, Korea

Abstract

A 16-year-old, 7.4 kg, castrated male Cocker Spaniel presenting anorexia and weight loss was referred due to a splenic mass, and total splenectomy was performed to resolve clinical signs. Following surgery, the dog developed mild hyperkalemia (6.27 mmol/L) without any clinical symptoms. Further investigations were conducted to determine the cause of hyperkalemia. The serum-plasma potassium difference was measured (1.05 mmol/L), and pseudohyperkalemia was diagnosed. The cause of pseudohyperkalemia was considered as thrombocytosis after splenectomy. The dog did not receive any specific treatment to lower blood potassium. To our knowledge, we report the first case of post-splenectomy pseudohyperkalemia in a dog.

Keywords: dogs; hyperkalemia; pseudohyperkalemia; splenectomy; thrombocytosis

Hyperkalemia is characterized by elevated levels of potassium in the blood. Normal potassium levels are between 2.7 and 5.0 mmol/L in dogs, and levels above 5.5 mmol/L are defined as hyperkalemia [1]. The causes of hyperkalemia in dogs are renal injury, severe vomiting, trauma, hypoadrenocorticism, dehydration, diabetic ketoacidosis, potassium intake, and drugs (e.g., angiotensin converting enzyme inhibitors, beta blockers, or potassium supplements) [2]. Dogs with hyperkalemia may present with clinical symptoms such as depression, weakness (> 6 mmol/L), lethargy, cardiac arrhythmias, electrocardiography abnormalities, and even asystole (> 8 mmol/L) in severe cases [3]. Immediate treatment is required if the potassium concentration in the blood is > 6 mmol/L [2].

Pseudohyperkalemia is a falsely elevated potassium concentration, in which potassium levels are normal *in vivo* but elevated *in vitro* [4]. It should be distinguished from spurious hyperkalemia caused by technical problems including inappropriate blood collection, inadequate sample transportation, and device errors [5]. In patients with non-clinical hyperkalemia, pseudohyperkalemia should be considered if the potassium gap between serum and plasma is higher than 0.4 mmol/L [5].

There are some case reports of pseudohyperkalemia after total splenectomy even in human medicine [6–8]. Since pseudohyperkalemia was first reported in human medicine in the 1950s [9], it was often misdiagnosed as true hyperkalemia [4]. Grech [7] reported that pseudohyperkalemia is still widely recognized in hu-

man medicine, and unnecessary treatment can be a threat to the patient.

This report presents a case of pseudohyperkalemia in a dog. To the best of our knowledge, this is the first case report of pseudohyperkalemia after total splenectomy in a dog.

A 16-year-old castrated male Cocker Spaniel dog weighing 7.4 kg was referred for a cranial abdominal mass. The patient presented with anorexia and weight loss for one month. Abdominal masses were confirmed by radiography at a local veterinary hospital.

Except for anorexia, there were no clinical symptoms related to the abdominal mass, such as abdominal distention, pain, or superficial lymph node (submandibular, prescapular, axillary, inguinal, and popliteal) enlargement, found upon physical examination. Blood analysis for complete blood cell (ProCyte Dx Hematology Analyzer; IDEXX Laboratories Inc., USA) and chemistry (Catalyst One Chemistry Analyzer; IDEXX Laboratories Inc.) did not show any specific findings except for non-regenerative mild anemia (hematocrit, 30.3%; range, 37.1% to 57%; reticulocyte index, 0.82) and mild thrombocytosis (platelet count, $582 \times 10^9/L$; range, 143.3 to $400 \times 10^9/L$). On radiography, a 48×45 mm, soft tissue density mass was identified in the left cranial abdomen. Abdominal ultrasonography revealed a heterogeneous mass in the body of the spleen. The mass contained anechoic cavity lesions with minimal blood flow. Computed tomography revealed no metastatic lesions (Fig. 1A) and a total splenectomy was performed to remove the splenic mass, and resolve the clinical signs.

Preanesthetic medications included cefazolin sodium (22 mg/kg, IV, Cefazolin; Jonggeundang Pharm., Korea) and midazolam (0.2 mg/kg, IV, Midazolam; Bukwang Pharmaceutical Co., Korea). This was followed by induction with propofol (5 mg/kg, IV, Anepol; Hana Pharm., Korea) and maintained with isoflurane via an endotracheal intubation. Remifentanyl (0.1 to 0.3

$\mu\text{g}/\text{kg}/\text{min}$, continuous rate infusion, Remiva; Hana Pharm.) was used for analgesia. After midline laparotomy, the spleen was exposed from the abdominal cavity (Fig. 1B), and total splenectomy was performed using a vessel-sealing device (Ligasure Exact Dissector; Covidien, USA) (Fig. 1C).

The splenic mass was diagnosed as lymphoma with low-grade spindle cell sarcoma on histopathological examination. The splenic mass contained 2 expanded cell populations, one of which was an expanded lymphoid population that was strongly suspected to represent lymphoma, low grade and small to intermediate cell size (Fig. 2). Based on these features, indolent-type lymphoma was considered the most likely cause. Polymer chain reaction for antigen receptor rearrangement was recommended to confirm the suspected lymphoma, but the owner of the dog refused further examinations due to high costs.

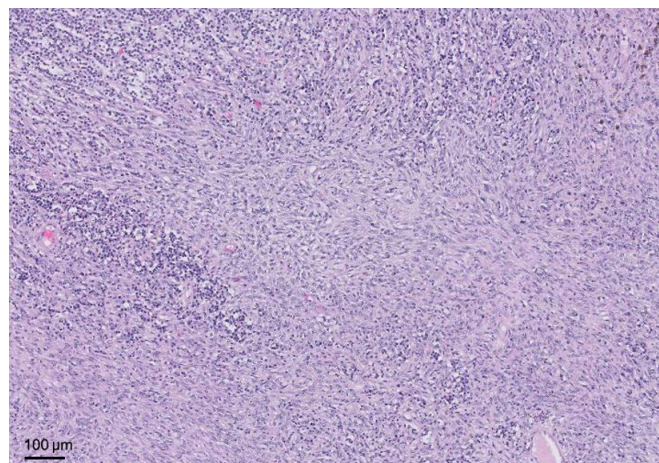


Fig. 2. Low magnification histopathologic image of the splenic tumor visualized with hematoxylin-eosin staining. The splenic tumor was suspected as nodular lymphoma with low-grade spindle cell sarcoma; nodule with expanded lymphoid population and with expanded spindle cell proliferation. Scale bar: 100 μm .

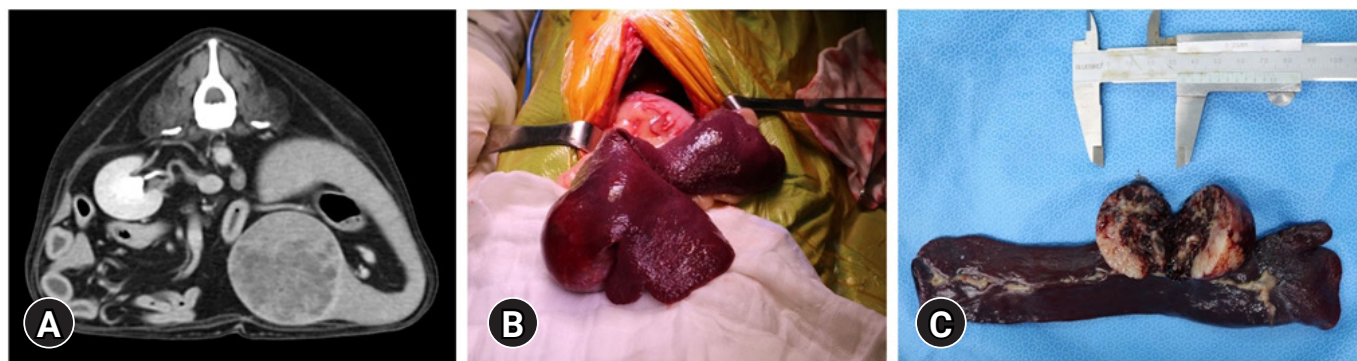

Fig. 1. (A) Splenic mass in preoperative computed tomography. (B) Intraoperative finding of splenic mass. (C) Gross appearance of the resected splenic mass.

Anorexia resolved after splenectomy, and elevated serum potassium (6.2 mmol/L; range, 2.70 to 5.00 mmol/L) and thrombocytosis ($994 \times 10^9/L$; range, 143.3 to $400 \times 10^9/L$) were found in blood analysis 5 days after surgery. Repeated blood sampling was performed to rule out technical errors, but the patient's serum potassium level was still elevated. The potassium level of other normal patients was measured to check the possibility of equipment error, but all results were within the normal range. Additional blood analyses were conducted for several days, but hyperkalemia was continuously observed (postoperative day [POD]-5, 6.27 mmol/L; POD-7, 6.84 mmol/L; POD-9, 6.73 mmol/L).

There was no clinical sign associated with hyperkalemia (e.g., polydipsia, polyuria, anorexia, lethargy, depression, weakness, vomiting, etc.). The patient's vital signs, electrocardiography, kidney panel, and urine output were normal. There was no urinary obstruction, which could have caused hyperkalemia. In addition, none of the prescribed medications were likely to cause hyperkalemia. Therefore, pseudohyperkalemia was strongly suspected. Lymphoma could be one of cause of pseudohyperkalemia, but pseudohyperkalemia due to lymphoma was ruled out, because total splenectomy was already performed and there was no specific finding in splenic lymph node on histopathology. For a definitive diagnosis of pseudohyperkalemia, both serum and plasma potassium concentrations were compared; the potassium concentrations were measured using serum clot and heparin tubes, respectively. In general, the electrolyte was measured using serum, but blood coagulation was prevented through a heparin tube and the electrolyte was measured by separating plasma. The difference between the 2 measurements was 1.05 mmol/L. Since the difference was more than 0.4, and there were no clinical signs related to hyperkalemia, pseudohyperkalemia caused by thrombocytosis after splenectomy was diagnosed. To diagnose pseudohyperkalemia, technical errors should be first excluded, and the difference in potassium concentration in serum and plasma should be found to be more than 0.4 mmol/L. The patient did not receive any specific treatment to lower the blood potassium level and was discharged.

Postoperative serum and plasma potassium levels and platelet counts were checked regularly (Table 1). Pseudohyperkalemia and thrombocytosis were maintained even one year after surgery, but there were no clinical symptoms related to hyperkalemia in the patient.

Most common cause of hyperkalemia in dogs is decreased potassium excretion by urine [1,2]. However, there was no evidence of kidney disease or urinary obstruction in this case. Of

course, there is a possibility that the kidney function may be degraded because the patient is old, but no abnormalities were found in kidney panel and urinalysis. There was no potassium intake, no potassium contained fluid, no dehydration, no burn injury, and no medications were prescribed to increase blood potassium concentration. There were no clinical symptoms related to hyperkalemia, and no clear cause was found, pseudohyperkalemia was suspected.

Pseudohyperkalemia falsely increases serum potassium concentration, not as a true elevation of potassium ions *in vivo* circulation [10]. Pseudohyperkalemia is caused by the release of intracellular potassium ions from blood cells including erythrocytes, leukocytes, and thrombocytes, during the coagulation process for serum formation. Unnecessary treatment for pseudohyperkalemia can be harmful to patients, leading to iatrogenic hypokalemia, cardiac arrhythmias, and even death [6,7].

High-potassium erythrocytes have been reported in Asian breeds, such as Akitas, Shibas, Jindos, and Chinese Shar Peis [11]. In these dogs, hyperkalemia may appear on blood analysis. In human medicine, falsely elevated blood potassium concentration is a well-known occurrence in patients with hematological disorders such as extreme leukocytosis or thrombocytosis [12].

In dogs with thrombocytosis, serum potassium concentration may be higher than that in the plasma. This is caused by the release of intracellular potassium ions in platelets into the extracellular space when platelets are activated during the coagulation process for serum formation [4]. Therefore, the more platelets, the more intracellular potassium ions may be released into the extracellular space and the resulting serum-plasma potassium difference could be greater. Reimann et al. [13] report-

Table 1. Postoperative serum and plasma potassium concentration, and platelet count

POD	Serum K ⁺ (mmol/L)	Plasma K ⁺ (mmol/L)	Serum-plasma difference (mmol/L)	Platelet count ($10^9/L$)
Preoperative day	4.20			525
POD 3	4.38			768
POD 5	6.27			832
POD 7	6.84	5.79	1.05	884
POD 9	6.73	5.68	1.05	825
POD 21	5.59	4.86	0.73	570
POD 30	5.46	4.90	0.56	774
POD 60	6.04	5.15	0.89	776
POD 90	5.11	4.53	0.58	724
POD 180	5.62	4.68	0.94	766
POD 360	5.45	4.65	0.80	791

POD, postoperative day.

ed that serum-plasma potassium difference was significantly different in dogs between the thrombocytopenic, normal, and thrombocytotic groups. It has been reported that thrombocytosis occurs in 75% to 82% of patients who undergo splenectomy in human medicine, and the platelets may remain elevated for weeks to years [14].

Thrombocytosis can occur through several mechanisms after splenectomy, including reactive thrombocytosis, loss of blood storage function of the spleen, and increased life span of platelets [6,8]. Splenectomy results in reactive thrombocytosis [14]. Unlike myeloproliferative disorders, more platelets are produced in the bone marrow in response to hemorrhage, inflammation, and tumors. Moreover, loss of the ability to store blood and destroy platelets in the spleen leads to thrombocytosis [3]. Similar to humans, the life span of thrombocytes was increased by 47% in dogs undergoing splenectomy [15]. Therefore, similar to humans, pseudohyperkalemia may occur in dogs with thrombocytosis after splenectomy.

In conclusion, thrombocytosis after total splenectomy in dogs may induce pseudohyperkalemia. Pseudohyperkalemia should be considered as a differential diagnosis when asymptomatic hyperkalemia is identified after splenectomy in dogs. In dogs with pseudohyperkalemia, treatment to correct the potassium concentration is unnecessary and can be harmful.

Acknowledgments

This research was supported by the Basic Science Research Program through the National Research Foundation of Korea (NRF), funded by the Ministry of Education, Science and Technology (2017R1D1A1B03035022).

ORCID

Chang-Hwan Moon, <https://orcid.org/0000-0003-3530-9860>

Je Hun Lee, <https://orcid.org/0000-0001-5583-0923>

You-Jeong Jeong, <https://orcid.org/0000-0002-8551-7900>

Young-Sam Kwon, <https://orcid.org/0000-0002-6489-0327>

Haebeom Lee, <https://orcid.org/0000-0002-1594-6670>

Dae-Hyun Kim, <https://orcid.org/0000-0002-3525-3812>

Seong Mok Jeong, <https://orcid.org/0000-0001-8653-5927>

References

1. Palmer N, Jensen ML, Raine H. Tumors of Joint. In: Jubb

KVF, Kennedy PC, Burke E, eds. Pathology of Domestic Animals. 2nd ed. pp. 140–144, Academic Press, San Diego, 1993.

2. Davis H, Jensen T, Johnson A, Knowles P, Meyer R, Rucinsky R, Shafford H; American Association of Feline Practitioners; American Animal Hospital Association. 2013 AAHA/AAFP fluid therapy guidelines for dogs and cats. *J Am Anim Hosp Assoc* 2013;49:149–159.
3. Richardson EF, Brown NO. Hematological and biochemical changes and results of aerobic bacteriological culturing in dogs undergoing splenectomy. *J Am Anim Hosp Assoc* 1996; 32:199–210.
4. Sevastos N, Theodossiades G, Archimandritis AJ. Pseudohyperkalemia in serum: a new insight into an old phenomenon. *Clin Med Res* 2008;6:30–32.
5. Lábadí Á, Nagy Á, Szomor Á, Miseta A, Kovács GL. Factitious hyperkalemia in hematologic disorders. *Scand J Clin Lab Invest* 2017;77:66–72.
6. Ahmed R, Isaac AM. Postsplenectomy thrombocytosis and pseudohyperkalemia in trauma: a case report and review of literature. *J Trauma* 2009;67:E17–E19.
7. Grech M. A case of undiagnosed pseudohyperkalaemia following a splenectomy. *Age Ageing* 2018;47:758–759.
8. Johnson CM, Hughes KM. Pseudohyperkalemia secondary to postsplenectomy thrombocytosis. *Am Surg* 2001;67:168–170.
9. Hartmann RC. The relationship of platelets to the serum potassium concentration. *J Clin Invest* 1955;34:938.
10. Lutomski DM, Bower RH. The effect of thrombocytosis on serum potassium and phosphorus concentrations. *Am J Med Sci* 1994;307:255–258.
11. Battison A. Apparent pseudohyperkalemia in a Chinese Shar Pei dog. *Vet Clin Pathol* 2007;36:89–93.
12. Colussi G, Cipriani D. Pseudohyperkalemia in extreme leukocytosis. *Am J Nephrol* 1995;15:450–452.
13. Reimann KA, Knowlen GG, Tvedten HW. Factitious hyperkalemia in dogs with thrombocytosis. The effect of platelets on serum potassium concentration. *J Vet Intern Med* 1989;3:47–52.
14. Khan PN, Nair RJ, Olivares J, Tingle LE, Li Z. Postsplenectomy reactive thrombocytosis. *Proc (Bayl Univ Med Cent)* 2009; 22:9–12.
15. Dale GL, Wolf RF, Hynes LA, Friese P, Burstein SA. Quantitation of platelet life span in splenectomized dogs. *Exp Hematol* 1996;24:518–523.