

Case Report

pISSN 2466-1384 · eISSN 2466-1392
Korean J Vet Res 2022;62(2):e11
<https://doi.org/10.14405/kjvr.20220007>

*Corresponding author:

Hany Lee
Conservation and Health Center, Seoul Zoo,
102 Daegongwongwangjang-ro, Gwacheon
13829, Korea
Tel: +82-2-500-7773
Fax: +82-2-500-7997
E-mail: hany0806@naver.com

ORCID:

<https://orcid.org/0000-0002-1848-9452>

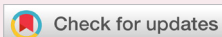Conflict of interest:

The authors declare no conflict of interest.

Received: Feb 23, 2022

Revised: Apr 9, 2022

Accepted: Apr 15, 2022



© 2022 The Korean Society of Veterinary Science.

© This is an open-access article distributed under the terms of the Creative Commons Attribution Non-Commercial license (<http://creativecommons.org/licenses/by-nc/4.0/>), which permits unrestricted non-commercial use, distribution, and reproduction in any medium, provided the original work is properly cited.

Uterine leiomyosarcoma in a captive female capybara (*Hydrochoerus hydrochaeris*): a case report

Hany Lee^{1*}, Soo-Hyeon Kim², Min-Kyung Bae²

¹Conservation and Health Center, Seoul Zoo, Gwacheon 13829, Korea

²Department of Veterinary Pathology, College of Veterinary Medicine, Konkuk University, Seoul 05029, Korea

Abstract

A captive female capybara (*Hydrochoerus hydrochaeris*) of unknown age discharged a bloody mass from the vaginal region. A histopathology examination revealed the mass to be a reproductive leiomyosarcoma, and an ovariectomy was performed. The histopathology examination confirmed that the excised tissue was a uterine leiomyosarcoma. The purpose of this report is to describe clinical history and histopathological diagnosis of leiomyosarcoma in capybaras. This report is novel because it describes the first diagnosis of uterine leiomyosarcoma in a capybara. Since clinical data about capybaras are rare, this case report will help to diagnosis and treat reproductive diseases of this species.

Keywords: rodentia; neoplasms; genitalia; uterus; leiomyosarcoma

The capybara (*Hydrochoerus hydrochaeris*) is the largest rodent that is native to South America [1]. Many capybaras are kept in zoos, aquariums, and breeding farms worldwide. On the other hand, there are few reports of diseases in capybaras [2,3]. A capybara in Seoul Zoo showed vaginal discharge and a bloody mass. The mass was diagnosed as a uterine leiomyosarcoma after a histopathology exam. Leiomyosarcomas are malignant tumors originating from the smooth muscle [4]. With unknown cause, uterine leiomyosarcomas are often taken place spontaneously [5]. Leiomyosarcomas usually affect the urogenital [6], gastrointestinal tract [7]. Leiomyosarcomas account for 0.4% of canine tumors and 0.2% to 1.5% of feline tumors [8].

Although the clinical signs of uterine tumors are irregular estrus cycles and vaginal discharge, the clinical signs can be non-specific, including anorexia, stranguria, constipation, abdominal distension, and vomiting [9]. In the case of rodents, a case of leiomyosarcoma in a greater cane rat (*Thryonomys swinderianus*) was reported [10]. In the case of rabbits, uterine leiomyosarcomas accounting for only 0.02% in rabbit uterus disease [11]. On the other hand, there are no reports of leiomyosarcoma in capybaras (Fig. 1). Since wild animals like capybara tend to conceal their abnormal condition such as pain, it is hard to observe their health statuses. Furthermore, there were a few studies about capybaras so that it is hard to find diagnostic and treatment options of the species. Therefore, this paper is significant because this case provides specific diagnosis procedures of reproductive disease of female capybaras. Therefore, the main objective of this paper to describes the clinical signs and histopathology findings of uterine leiomyosarcoma



Fig. 1. Female capybara (*Hydrochoerus hydrochaeris*).

in a capybara for diagnosis and treats reproductive diseases of capybaras.

A female, 25 kg, capybara of unknown age, was introduced to Seoul Zoo in 2018. One day, the animal had a bloody discharge at the vaginal region; a 5 cm × 3 cm sized mass was discharged. The weight of the mass was 10.5 g. Prior to the vaginal discharge, the animal did not show any clinical signs. Because the mass was soft bloody in color, it was initially considered to be coagulated blood. The mass was collected in a 10% formalin solution and referred to a veterinary diagnostic laboratory (Popanilab, Korea) for a histopathological examination. Since wild animals such as capybaras are hard to collect their blood without anesthesia because of their aggressive manner, a blood examination was not able to perform. The capybara was suspected for a uterine infection such as pyometra and endometritis only based on its clinical sign like vaginal bleeding. Therefore, antibiotics (tulathromycin, 1.92 mg/kg, intramuscular [IM], Draxxin; Zoetis, Spain) and a non-steroidal inflammatory drug (tolfenamic acid, 2.3 mg/kg, IM, Tolfedine; Vetoquinol, France) were injected. The laboratory examination showed that the mass was a reproductive leiomyosarcoma, which consisted of neoplastic proliferous elongated spindle cells. The center of mass was well vascularized. In addition, the neoplastic spindle cells produced a medium density of multi-oriented bundles, and eosinophilic cytoplasm was observed in the neoplastic cells. The tumor cells showed oval-shaped nuclei with anisokaryosis and coarse, dense chromatin. In addition, the ratio of the nucleus to the cytoplasm of the tumor cells was increased. In 400× magnification, zero to one mitotic figure in the tumor cells and

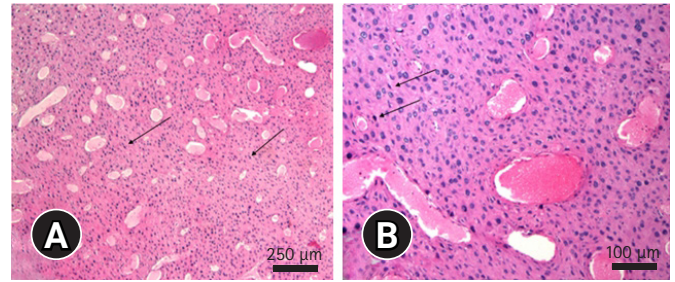


Fig. 2. Histopathological features of the discharged mass from the capybara vaginal region. (A) Spindle-shaped neoplastic cells with a medium density (arrows) were well vascularized and consisted of multi-oriented bundles. H&E, scale bar: 250 μ m. (B) The nuclei of neoplastic cells were oval-shaped with anisokaryosis and coarse, dense chromatin (arrows). The neoplastic cells showed a higher ratio of nucleus to cytoplasm. Zero to one mitotic figure was observed in the nucleus of these tumor cells. H&E, scale bar: 100 μ m.

some hemorrhagic, necrotic lesions were observed in the center of the mass (Fig. 2).

To remove the mass of uterine leiomyosarcoma, an ovario-hysterectomy in the capybara was performed. To anesthetize the capybara, intramuscular injection of 5 μ g/kg medetomidine (Sedastart; Produlab Pharma B.V., The Netherlands), 0.05 mg/kg butorphanol tartrate (Butorphan; Myungmoon Pharm, Korea), and 1.15 mg/kg tiletamine/zolazepam (Zoletil; Virbac, France) were performed. After surgery, the capybara showed cecal tympany symptoms. An intravascular injection of 0.03 mg/kg neostigmine (Neogmine; Handong, Korea) and cecal catheterization was performed to relieve the symptoms. Intravascular 0.03 mg/kg atipamezole (Reversal; Provet Veterinary Products, Turkey) and 0.01 mg/kg flumazenil (Flunil; Bukwang Pharm, Korea) were injected to reverse the anesthesia. For analgesic effects, a subcutaneous injection of 0.1 mg/kg meloxicam (Meloxicam 2% injection; Labiana Life Sciences, Spain), and an intramuscular injection of 5.75 mg/kg tramadol (Tridol injection; Yuhan, Korea) were performed. Furthermore, the combination of 1.92 mg/kg tramadol, 1 mg/kg 2% lidocaine (Lidocaine injection 2%; Daihan Pharm, Korea), and 11.53 mg/kg ketamine (Ketamine 50 injection; Yuhan) diluted in 491.75 mL of normal saline, were injected by intravenous constant rate infusion. An intravenous injection of 20 mg/kg cefazoline (Cefazoline injection; Chongkundang, Korea) was administered as a prophylactic and post-surgery antibiotic. The excised mass of uterine and ovaries was immersed in a 10% formalin solution and sent to a pathology laboratory at Konkuk Veterinary University (Korea) for a post-operative histopathologic diagnosis. After surgery, the capybara showed anorexia, so an antibiotic

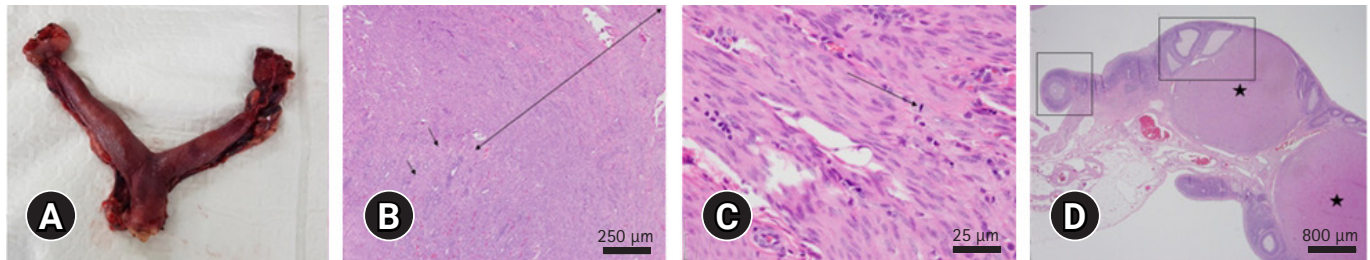


Fig. 3. Postsurgical images of the excised uterus and ovaries (A) and histology section of the uterine mass (B-D). (A) Removed mass of ovaries and a uterine from the capybara. The uterine part of this mass showed endometrial hyperplasia. The right ovary is larger than the left ovary. (B) Abnormal hyperplasia myometrium (both side arrow) and invasive proliferation to the endometrium (one side arrows) were observed. H&E, scale bar: 250 μ m. (C) Uterine mass, which consisted of spindle smooth muscle cells with anisokaryosis and mitotic figures (arrow), showed malignant features. H&E, scale bar: 25 μ m. (D) Ovaries with normal structures of the corpus luteum (asterisks) and ovarian follicles (rectangles) were observed without any abnormal lesions. H&E, scale bar: 800 μ m.

(cefazoline 20 mg/kg intravascular [IV]), analgesics (meloxicam 0.1 mg/kg subcutaneous [SC], butorphanol tartrate 0.05 mg/kg IM, tramadol 5.75 mg/kg IM), and nutritional supplements (aminoethane sulfonic acid 25 mg/kg IV (Taurine F injection; Samyang Anipharm, Korea), amino acid mix 5 mL IV (Amitop S injection; Handong), ascorbic acid 28.84 mg/kg SC (Merit C injection; Huons, Korea) were administered, but the animal died in the next day. The gross findings showed that the excised left ovary was larger than the right ovary. In addition, endometrial hyperplasia from the uterine mass was observed. The excised mass from the uterine and ovaries was also diagnosed as leiomyosarcoma. In the case of the uterine mass, myometrium hyperplasia and invasive proliferation of the muscle cells to the endometrium were observed in the low magnification of microscopic view. In a high magnification view, spindle-shaped smooth cells revealed anisokaryosis and dense chromatin. In addition, mitotic indices from the neoplastic cells showed malignant features. As a result, the mass was confirmed to be a leiomyosarcoma. In the case of the ovaries, it consisted of normal corpus luteum and ovarian follicles without any neoplastic and invasive changes (Fig. 3).

In this case, the histopathology results of the released mass from the vulva of the capybara and the excised uterine mass were consistent. As a result, the released mass originated from the uterine. Therefore, the cytological examination of the vaginal discharge or histopathological examination of the released mass from reproductive organs can help identify the reproductive diseases of capybaras. The histopathological changes of leiomyosarcoma in the capybara, which were spindle cells with anisokaryosis and mitotic figures, are similar to other animals features of leiomyosarcoma. In a case of rabbit uterine leiomyosarcoma also showed spindle cells with elongated, blunt-ended nuclei and moderate anisokaryosis [11]. Only a few tumor cases

of capybara have been reported, such as a squamous cell carcinoma and a digital histiocytic sarcoma [12,13]. This appears to be the first report of leiomyosarcoma in capybaras. The most effective treatment option for reproductive tumors, such as uterine leiomyosarcomas, is an ovariohysterectomy [14]. In the case of capybaras, the high occurrences of acute cecal tympany during chemical restraint can cause death to the animal. Capybaras are hindgut fermenters with large cecum. Therefore, under anesthesia, decreased gastrointestinal motility produces excessive volatile gas, which can lead to acute cecal tympany [15]. In this case, the capybara woke up well after anesthesia but died the next day. The necropsy results of the capybara suggested death by cecal dilation with acute respiratory and circulatory failure. The exerted pressure from cecal dilation against the diaphragm and compression of major blood vessels might lead to hypoxia and hypovolemic shock of the capybara. Therefore, after anesthetizing a capybara, intensive care of the animal is essential. Catheterization of dilated cecum is the main treatment option of cecal tympany [15]. Therefore, it is important to release over produced gas in the cecum during and after anesthesia when capybaras have cecal dilation. In this case, the capybara did not show cecal dilation during anesthesia. However, after surgery, the capybara showed cecal tympany symptom once, so that the symptom was relieved by cecal catheterization and neostigmine injection. However, it seemed like that the cecal dilation of the capybara reoccurred at night. Since this zoo animal hospital was not a 24-hour operated hospital, it was hard to monitor the animals' health status at the night-time. Therefore, 24-hour intensive monitoring of capybaras is recommended after anesthetizing capybaras to manage acute cecal dilation of the animals. In conclusion, a female capybara of unknown age showed vaginal discharge and released mass from its vulva. The mass was diagnosed as a uterine leiomyosarcoma, so an ovario-

hysterectomy was performed. The excised uterine after surgery was also confirmed as a uterine leiomyosarcoma. This report is the first official case of a uterine leiomyosarcoma of a capybara. Many cases of uterine leiomyosarcoma of companion animals are usually diagnosed by diagnostic imaging. However, the uterine leiomyosarcoma in this capybara was diagnosed by histopathological exam of the released vulva mass. Therefore, the diagnostic method of uterine disease of the capybara was differed from previously published cases. Capybaras are difficult to perform anesthesia because of acute cecal tympany [15]. In this reason, examination of vulva discharge or mass will be a clue for diagnosis of reproductive diseases in the species although the correlation between released mass and diseases of other capybaras will be needed more studies in the future.

ORCID

Hany Lee, <https://orcid.org/0000-0002-1848-9452>

Soo-Hyeon Kim, <https://orcid.org/0000-0002-1662-2651>

Min-Kyung Bae, <https://orcid.org/0000-0001-8654-1761>

References

1. Barreto GR, Herrera EA. Foraging patterns of capybaras in a seasonally flooded savanna of Venezuela. *J Trop Ecol* 1998; 14:87–98.
2. Cueto GR. Diseases of the Capybara. In: Moreira J, Ferraz KM, Herrera EA, Macdonald DW, eds. *Capybara: Biology, Use and Conservation of an Exceptional Neotropical Species*. pp. 169–184, Springer, New York, 2013.
3. Meireles MV, Soares RM, Bonello F, Gennari SM. Natural infection with zoonotic subtype of *Cryptosporidium parvum* in Capybara (*Hydrochoerus hydrochaeris*) from Brazil. *Vet Parasitol* 2007;147:166–170.
4. Brodey RS, Roszel JF. Neoplasms of the canine uterus, vagina, and vulva: a clinicopathologic survey of 90 cases. *J Am Vet Med Assoc* 1967;151:1294–1307.
5. Solomon LA, Schimp VL, Ali-Fehmi R, Diamond MP, Munkarah AR. Clinical update of smooth muscle tumors of the uterus. *J Minim Invasive Gynecol* 2005;12:401–408.
6. Hurcombe SD, Slovis NM, Kohn CW, Oglesbee M. Poorly differentiated leiomyosarcoma of the urogenital tract in a horse. *J Am Vet Med Assoc* 2008;233:1908–1912.
7. MacGillivray KC, Graham TD, Parente EJ. Multicentric leiomyosarcoma in a young male horse. *J Am Vet Med Assoc* 2003 223:1017–1021, 986.
8. Theilen GH, Madewell BR. Tumors of the Urogenital Tract. In: Theilen GH eds. *Veterinary Cancer Medicine*. pp. 367–373, Lea and Febiger, Philadelphia, 1979.
9. Brodey RS. Canine and feline neoplasia. *Adv Vet Sci Comp Med* 1970;14:309–354.
10. Ajayi OL, Olaniyi MO, Alaka OO, Antia RE, Oladipo TM. Uterine leiomyosarcoma associated with cystic endometrial polyps, chondriod metaplasia and uterine horn intussusception in a greater cane rat. *Mac Vet Rev* 2020;43:197–204.
11. Saito K, Nakanishi M, Hasegawa A. Uterine disorders diagnosed by ventrotomy in 47 rabbits. *J Vet Med Sci* 2002;64: 495–497.
12. Hamano T, Terasawa F, Tachikawa Y, Murai A, Mori T, El-Dakhly K, Sakai H, Yanai T. Squamous cell carcinoma in a capybara (*Hydrochoerus hydrochaeris*). *J Vet Med Sci* 2014;76: 1301–1304.
13. Srivorakul S, Boonsri K, Vechmanus T, Boonthong P, O'Sullivan MG, Pringproa K. Localized histiocytic sarcoma in a captive capybara (*Hydrochoerus hydrochaeris*). *Thai J Vet Med* 2017;47:131–135.
14. Harvey M. Conditions of the Non-Pregnant Female. *Manual of Small Animal Reproduction and Neonatology*. 1st ed. p. 49, British Small Animal Veterinary Association, Loughborough, 1998.
15. Rosenfield DA, Ferraro MA, Yanai PR, Igayara C, Pizzutto CS. Acute cecal tympany during chemical restraint in free-ranging Capybara (*Hydrochoerus hydrochaeris*): iatrogenic cause and treatment. *Braz J Vet Pathol* 2019;12:117–122.