

Image vignette

Playing snakes and ladders with
the common fibular nerve on
ultrasound after knee dislocationNatan Bensoussan ^{id}, Mathieu Boudier-Revéret ^{id},
Johan Michaud ^{id}Department of Physical Medicine and Rehabilitation, Centre
hospitalier de l'Université de Montréal, Montréal, QC, Canada

Received: July 30, 2021 Revised: August 19, 2021

Accepted: August 20, 2021

Corresponding author: Mathieu Boudier-Revéret, MD
Hôtel-Dieu du Centre hospitalier de l'Université de Montréal, 3840 rue Saint-
Urbain, Montréal, QC, H2W 1T8, Canada
Tel: +1-514-890-8000 Fax: +1-514-412-7610
E-mail: mathieu.boudier-reveret@umontreal.caJ Yeungnam Med Sci 2022;39(3):266-267
<https://doi.org/10.12701/yujm.2021.01389>Copyright © 2022 Yeungnam University College of Medicine, Yeungnam Univer-
sity Institute of Medical ScienceThis is an Open Access article distributed under the terms of the Creative
Commons Attribution Non-Commercial License (<http://creativecommons.org/licenses/by-nc/4.0/>) which permits unrestricted non-commercial use, distri-
bution, and reproduction in any medium, provided the original work is properly
cited.

We present the case of a 21-year-old previously healthy varsity rugby athlete with left common fibular nerve (CFN) injury following knee dislocation. She presented to a local hospital with a traumatic knee injury following blunt anterior impact causing posterior dislocation. Immediately, she noted anesthesia of the lateral leg and dorsal foot, and dorsiflexion paralysis. Computed tomography revealed a tibial plateau fracture with 2 mm impaction. Magnetic resonance identified torn anterior and posterior cruciate ligaments, a torn lateral collateral ligament, and a grade one medial collateral ligamentous sprain. The fibular nerve was not commented on. Electromyography (EMG) studies confirmed a CFN mononeuropathy. She underwent orthopedic surgery for ligament repair 2 weeks post-injury followed by consultation with a peripheral nerve surgeon.

The patient was seen in our musculoskeletal medicine clinic for preoperative ultrasonographic assessment. She had regained partial sensation of the left distal

extremity, however, remained unable to dorsiflex and evert the foot. Ultrasonographic analysis (Samsung RS80A machine, linear L4-18B probe; Samsung, Seoul, Korea) identified a tortuous fibular nerve extending 5 cm proximal to its passage over the fibular neck (Fig. 1, Supplementary Video 1). Loss of fascicular pattern began prior to division from the sciatic nerve and extended 7 cm distally, with maximal edema at 9 cm proximal to the fibular neck measuring 1 cm in diameter, with no nerve discontinuity. Common and superficial fibular nerves were unremarkable distal to the fibular neck. Upon surgical exploration, the CFN distal to its branching off the sciatic nerve was scarred and hardened. The neuroma in continuity was excised followed by grafting using cable grafts from the sural nerve. Pathology results confirmed a traumatic neuroma. At the 1-year follow-up, there was slight improvement on clinical and EMG exam in the fibular muscles (Medical Research Council Scale for Muscle Strength score 2/5), but no improvement in the muscles of the anterior compartment of the leg (tibialis anterior, extensor digitorum longus, extensor hallucis longus: strength 0/5).

Like seven of the eight patients described by Coraci et al. [1], we did not observe CFN neurotmesis. In our

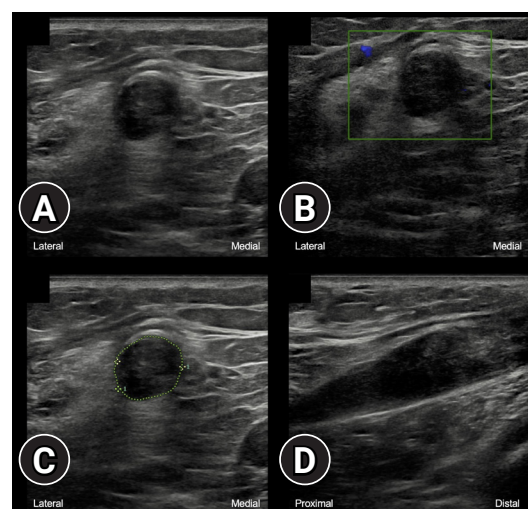


Fig. 1. Ultrasonography of the left common fibular nerve shows intraneural swelling and loss of fascicular pattern without discontinuity after a knee posterior dislocation, in transverse axis (A) without and (B) with color doppler imaging, (C) with area (75 mm²) and diameter (9.9 mm) measurements, and (D) in longitudinal axis.

patient, we additionally described distinct features of a neuroma which was tortuous at the popliteal fossa. Ultrasonographic analysis changed the course of treatment and the surgical approach. Numerous studies have shown the incidence of CFN palsy post-knee dislocation ranges from 10% to 40% [2]. Imaging findings include perineural edema, nerve discontinuity, and neuroma formation. Morris et al. [3] described a case of fibular nerve looping at the site of injury, which they termed the “lariat sign.” What we have described here is a redundant nerve in the absence of rupture, raising the question as to whether the anomaly is that of severe nerve stretching without rupture or rather nerve entrapment within disorganized fibrous scar tissue leading to its tortuous nature.

Supplementary material

Supplementary Video 1 can be found via <https://doi.org/10.12701/yujm.2021.01389>.

Notes

Ethical statements

Written patient consent was obtained.

Conflicts of interest

No potential conflict of interest relevant to this article was reported.

Funding

None.

Author contributions

Conceptualization: all authors; Writing-original draft: NB, MBR; Writing-review & editing, Validation: all authors.

References

1. Coraci D, Tsukamoto H, Granata G, Briani C, Santilli V, Padua L. Fibular nerve damage in knee dislocation: Spectrum of ultrasound patterns. *Muscle Nerve* 2015;51:859–63.
2. Bonneville P, Dubrana F, Galau B, Lustig S, Barbier O, Neyret P, et al. Common peroneal nerve palsy complicating knee dislocation and bicruciate ligaments tears. *Orthop Traumatol Surg Res* 2010; 96:64–9.
3. Morris BL, Grinde AS, Olson H, Brubacher JW, Schroepel JP, Everist BM. Lariat sign: an MRI finding associated with common peroneal nerve rupture. *Radiol Case Rep* 2018;13:743–6.