



Case Report

Korean Medicine Treatment for Managing Complex Regional Pain Syndrome: Case Report

Ji-won Park^{1,*}, Myung-In Jeong¹, Wu-Jin Jeong¹, Hae-Won Hong¹, Ji-eun Koo², Sung-won Choi², Da-hyun Kyung³

1 Department of Acupuncture and Moxibustion Medicine, Daejeon Jaseng Hospital of Korean Medicine, Daejeon, Korea

2 Department of Rehabilitation Medicine of Korean Medicine, Daejeon Jaseng Hospital of Korean Medicine, Daejeon, Korea

3 Ophthalmology and Otolaryngology and Dermatology of Korean Medicine, Daejeon Jaseng Hospital of Korean Medicine, Daejeon, Korea

ABSTRACT

Article history:

Submitted: May 17, 2022

Revised: July 19, 2022

Accepted: July 26, 2022

Keywords:

acupuncture,
complex regional pain syndrome,
Korean traditional medicine

A 53-year-old male who had received surgery on his right ankle joint 10 years previously was diagnosed with Complex Regional Pain Syndrome the following year. Despite various treatments (sympathetic nerve-block medication, pain relievers, corticosteroids, nerve blocks, and transcutaneous electrical nerve stimulation) over the years there was no improvement in his symptoms. Recently the patient was admitted to a Korean medicine hospital where he received treatment (acupuncture, pharmacopuncture, and herbal treatment) and his symptoms gradually showed improvement. The patient was concurrently on psychiatric medicine, antihistamine medication, and opioids for pain (when necessary). A decrease in numeric rating scale, Oswestry disability index scores, and an increase in the Korean version of the 5-level EuroQol-5 dimension score showed symptom improvement within 36 days. This study suggests complex Korean medicine treatment for Complex Regional Pain Syndrome may result in a reduction in pain and improved quality of life.

<https://doi.org/10.13045/jar.2022.00122>
pISSN 2586-288X eISSN 2586-2898

©2022 Korean Acupuncture & Moxibustion Medicine Society. This is an open access article under the CC BY-NC-ND license (<http://creativecommons.org/licenses/by-nc-nd/4.0/>).

Introduction

Complex regional pain syndrome (CRPS) is a neuropathic condition/disease characterized by prolonged pain and inflammation that can emerge after acute injury to a limb. In addition to neuropathic pain, CRPS patients experience sensory, motor, and trophic symptoms which are disproportionate to the initial trauma [1]. Among the typical precipitating events such as contusions, soft tissue injuries, and sprains, CRPS has been reported to occur after fractures [2]. The intensity, duration, and clinical course of CRPS is reported to be unpredictable [3].

The underlying pathophysiology of CRPS is unknown, but

it is generally accepted that it is multifactorial and is associated with diverse presentations across patients. Mechanisms suspected to contribute to CRPS include neuropathic inflammation, an imbalance in the autonomic nervous system, and autoimmunity [4-6].

There is currently no cure for CRPS. Management of CRPS, extends to several treatment modalities involving patient education, physical therapy, pharmacotherapy, and surgical therapy [7]. Effective treatment options for CRPS, to reduce patient suffering and improve quality of life, are required [8]. The results from this case study suggests that complex Korean medicine maybe an alternative option for the management of CRPS symptoms.

*Corresponding author. Ji-won Park

Department of Acupuncture and Moxibustion Medicine, Daejeon Jaseng Hospital of Korean Medicine, 58, Munjeong-ro, 48 Beon-gil, Seo-gu, Daejeon, Korea

E-mail: lilybells93@jaseng.org

ORCID: Ji-won Park <https://orcid.org/0000-0001-5029-5570>, Myung-In Jeong <https://orcid.org/0000-0003-1048-7003>,

Wu-Jin Jeong <https://orcid.org/0000-0002-5285-4337>, Hae-Won Hong <https://orcid.org/0000-0002-3609-8500>, Ji-eun Koo <https://orcid.org/0000-0002-0112-9688>,

Sung-won Choi <https://orcid.org/0000-0002-1244-0105>, Da-hyun Kyung <https://orcid.org/0000-0002-0682-5631>

©2022 Korean Acupuncture & Moxibustion Medicine Society. This is an open access article under the CC BY-NC-ND license (<http://creativecommons.org/licenses/by-nc-nd/4.0/>).

Case Report

Medical history

An unemployed 53-year-old male, presented with pain and paresthesia in his right leg was accompanied with lower back pain. The patient was admitted to the Jaseng Korean medicine hospital on December 18, 2021.

In 2011, the patient fell at work which resulted in a right calcaneus bone fracture. After radiological examinations, he underwent a calcaneal fracture fixation operation to hold the bone fragments together. However, his pain was not alleviated despite all the rehabilitation treatments he received. Subsequently, in 2012, after radiological examinations and neuro-motor examinations at a tertiary referral hospital he was diagnosed with Type 1 CRPS. He visited other medical institutions to seek further treatment including sympathetic nerve-blocking medication, pain relievers, corticosteroids, nerve blocks, and transcutaneous electrical nerve stimulation before visiting our hospital. His persistent symptoms consequently led to the patient developing a panic disorder and depression, and since 2018 the patient had been taking antidepressants and anticonvulsants. The patient developed lower back pain in October 2021.

When the patient visited the Korean medicine hospital on December 18th, 2021, he was taking antihistamine for insomnia (doxylamine succinate, 50 mg/day), medication for his panic disorder and depression (alprazolam 1.5 mg/day and escitalopram oxalate 10 mg/day), and prescription opioids for general pain (tapentadol hydrochloride 50 mg) which were prescribed to be taken when pain aggravated. Evaluations of the lumbar spine were performed to investigate the lower back pain. The lumbar range of motion was in the normal range and tenderness in the lower back were elicited through palpation. Bragard and Laseque tests were negative and bilateral straight leg raising tests were positive at 40°. Lumbar X-rays were performed and showed no abnormalities in the bony structure and soft tissue opacity (Fig. 1).

Treatment

Acupuncture

Acupuncture was performed after sterilizing the skin with ethanol around the needling points, standard, disposable sterile acupuncture needles [0.20 × 30mm (Dong-bang Acupuncture, SeongNam, Korea)] were used. The acupoints used included Shinsu (BL23), Wijung (BL40), Sameumgyo (SP6), Seungsan (BL57), and Hyeonjong (GB39).

Electroacupuncture (1–25 Hz) was applied at 2 acupuncture points using a low-frequency treatment device (STN-330 Stratek, Anyang, Korea) and all the needles were retained for 5 minutes. Considering the characteristics of CRPS, manipulation to induce de-qi sensation was not adopted.

To perform Shinbaro pharmacopuncture, Shinbaro (Jaseng Wonoe Tangjunwon, Namyangju, Korea) was injected at Gollyun (BL60) and Taegye (KI3). Disposable, 29-gauge, 12.7 mm needles were used on 1 cc syringes (Sungshim Medical, Bucheon, Korea) filled with refrigerated Shinbaro pharmacopuncture solution,

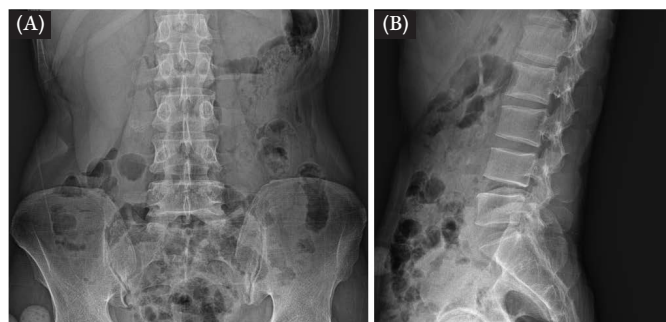


Fig. 1. X-ray imaging (November 18th, 2021). (A) Axial X-ray of lumbar spine. (B) Sagittal X-ray of lumbar spine.

and 0.2–1.0 mL of solution was used per session. A Korean medicine doctor performed the pharmacopuncture daily during hospitalization (Table 1).

Herbal medicine

Chungpajun-H decoction (120 mL/package) was taken 3 times a day after meals for their anti-inflammatory and pain control effects (Table 2). In addition, when the patient complained of insomnia, Woohwangchungsim-won was given (tablets) was taken before going to sleep.

Assessments

Numeric rating scale

The numerical rating scale (NRS) is a scale used to measure the intensity of the respondent's pain where 0 indicated no pain, and 10 indicated the worst pain imaginable. NRS scores were taken every day to find the curative effects of the treatment course [9].

Oswestry disability index

The Oswestry disability index (ODI) is a patient-reported measure comprising 10 questions to estimate lower back pain and accompanying disability [10]. ODI was taken at admission and discharge.

European Quality of Life-5 dimensions

The EuroQol 5-dimension 5-level (EQ-5D-5L) is a survey to assess the state of health over 5 categories. EQ-5D-5L was taken to compare the patient's self-reported health status before and after treatment [11].

Ethics statement

The medical records of the patient were acquired retrospectively and approved for use by the Institutional Review Board of Jaseng Hospital of Korean Medicine (IRB file no.:2022-05-007).

Progress note

On the 1st day of inpatient treatment on the 18th December, 2021, he rated both his right limb pain and lower back pain as an

Table 1. Details of Interventions Using the STRICTA 2010 Checklist.

Item	Details
Acupuncture rationale	1a) Acupoints were selected based on traditional Korean medicine meridian theory in treating leg and lower back pain. 1b) Acupuncture treatment was administered for its anti-inflammatory and analgesic effects. 1c) Needles were removed when the patient complained of too much pain in the area.
Details of acupuncture	2a) 6-10 needles were used per session. 2b) BL23, BL40, SP6, BL57, GB39 2c) The depth of inserted needles was between 0.5cm and 2.5 cm. 2d) Any manipulations to induce de-qi sensation were not adopted. 2e) Electrical stimulation was applied using a low-frequency electro stimulator (STN-330 Stratek, Anyang, Korea). 2f) Needles were retained for 5 minutes. 2g) 0.20×30 mm disposable stainless steel needles were used (Dong-bang Acupuncture, SeongNam, Korea).
Treatment regimen	3a) The patient received 57 sessions of acupuncture treatment. 3b) Acupuncture was administered twice a day during hospitalization.
Other components of treatment	4a) Pharmacopuncture treatment based on the meridian theory was performed every day. Herbal treatment was taken 3 times a day. Psychiatric medication was allowed to be taken. 4b) The patient was informed about their diagnosis and treatments.
Practitioner background	5) 3 Korean medicine doctors with 1-15 years of clinical experience provided treatments in the treatment room.
Control or comparator intervention	6a) This study was not relevant because there was no control group. 6b) This study was not relevant because there was no control group.

Table 2. The Composition of Herbal Medicine.

Herbal medicine	Herbal components (g)
Chungpajun-H	Lasiophaera Seu Calvatia 7.5, Acanthopanax Cortex 5, Cibotti Rhizoma 5, Eucommiae Cortex 5, Achyranthes bidentata Bl. 5, Saposhnikovia Radix 5, Atractylodis Rhizoma Alba 2.5, Geranii Herba 2.5, Amomi Fructus 2.5 glycyrrhizae Radix 1.6, Zingiberis Rhizoma 1.25, Scolopendra morsitans L 0.25
Woohwangchungsim-won	Dioscoreae Rhizoma 1.052, Glycyrrhizae Radix et Rhizoma 0.752, Ginseng Radix Alba 0.376, Typhae Pollen 0.376, Massa Medicata Fermentata 0.376, Bubalus bubalis 0.301, Glycine Semen Germinatum 0.263, Cinnamomi Cortex 0.263, Asini Corii Colla 0.263, Paeonia obovata var 0.226, Liriopsis seu Ophiopogonis Tuber 0.226, Scutellariae Radix 0.226, Angelicae Gigantis Radix 0.226, Saposhnikovia Radix 0.226, Atractylodis Rhizoma Alba 0.226, Bupleurum falcaum 0.188, Platycodonis Radix 0.188, Zizyphi Fructus 1.174, Bovis Calculus 0.028, Aquilariae Lignum 0.028, Bomeolum 0.019

NRS score 7, and the ODI and EQ-5D-5L scores were 72 and 0.275, respectively. Of note the patient had opioid pain relief on the 23rd December, 2021. On the 26th December, 2021, 9th day of hospitalization, he reported that his lower back pain had slightly improved and he indicated a score of 6 on the NRS. Of note the patient had opioid pain relief on the 30th December, 2021. On the 30th December, 2021, his right limb pain had not improved but his lower back pain had improved and he indicated a score of 4 on the NRS. On the 3rd January, 2022, his right limb pain decreased by a little and he indicated a score of 6 on the NRS. On January 22nd, 2022, he was discharged from the hospital grading his right limb pain as NRS 4 and his lower back pain as NRS 3. Furthermore, his ODI score was 58 and his EQ-5D-5L score was 0.324 (Fig. 2). In addition, the amount of medication needed to manage the patient's pain had been reduced, and the panic disorder, depression, and insomnia medication had been stopped by the 3rd January, 2022 (Table 3).

Discussion

The current understanding of CRPS has improved since the early definitions of the 19th century, but to date, CRPS remains poorly understood and does not have a cure. CRPS is a multifactorial disorder affecting the vascular, nervous, skeletal, and immune systems, so a multidisciplinary approach is recommended for its management [12]. However, the effectiveness of treatments for CRPS are reported to be lacking high-quality evidence, and the side effects of some treatments add further concern [13]. Moreover, patients in Korea with CRPS are often resistant to conventional Western treatments. In this case, the patient had received various treatments but to no avail and decided to be treated with Korean medicine.

Acupuncture treatment, which is increasingly being used internationally, has a long history in the management of many disorders, and it is thought that it contributes to the balance of

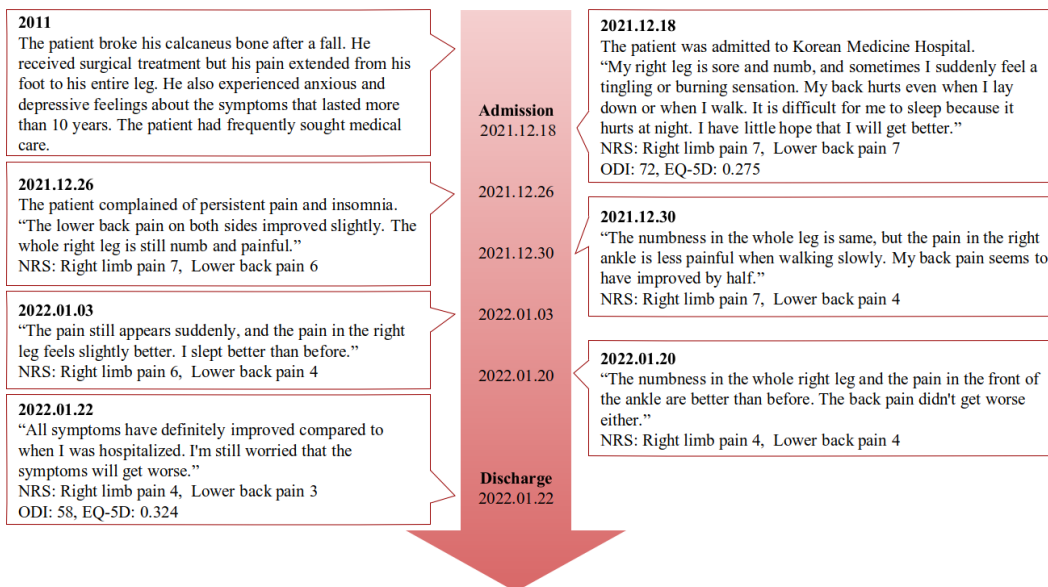


Fig. 2. Timeline of patient history and clinical symptoms. EQ-5D, EuroQol-5 dimension; NRS, numerical rating scale; ODI, Oswestry disability index.

Table 3. Changes in Drug Dose by Date.

Date (y/mo/d)	Panic disorder medication alprazolam (mg/d)	Panic disorder/ depression medication escitalopram (mg/d)	Anti-histamine medication doxylamine succinate (mg/d)	Opioid pain medication tapentadol hydrochloride (mg/d)	Herbal medicine for insomnia (tablet/d)
2021/12/18	2	10	50	None	None
2021/12/20	2	10	50	None	Woohwangchungsim-won
2021/12/23	2	10	50	50	Woohwangchungsim-won
2021/12/26	2	10	25	None	None
2021/12/30	2	10	25	50	None
2022/01/03	0	0	25	None	None
2022/01/22	0	0	25	None	None

the autonomous system and stimulation of the central nervous system. In addition to the anti-inflammatory and analgesic effects of acupuncture, acupuncture treatment could be a favorable option for the management of CRPS in patients with autonomic dysfunction or inflammatory changes [14,15].

Pharmacopuncture is a newly developed therapy (compared with acupuncture) that involves the injection of herbal extracts into acupuncture points. This method aims to induce the chemical effects of herbal medicine with the mechanical effect of acupuncture. In this case, Shinbaro pharmacopuncture extracted from GCSB-5 (*Eucommia ulmoides* cortex, *Acanthopanax*

sessiliflorum cortex, *Achyranthis bidentata* radix, *Saposhnikovia divaricata* radix, and *Cibotium barometz* rhizoma) was used. GCSB-5 has been reported to affect the regulation of both acute and chronic inflammation and modulate oxidative stress to promote nerve recovery [16,17]. These mechanisms may have contributed to alleviating the patient's symptoms in this case report.

Herbal medicine contains multiple substances. Cheongpajeon has anti-inflammatory and pain control properties and may have helped relieve the patient's pain. In addition, the patient was prescribed Woohwangchungsim-won in the 1st week of admission because he complained of difficulty sleeping. He tended

to have delayed onset of sleep and waking up early in the morning. Woohwangchungsim-won is a prescription that has been used to treat sleep disorders in Korean medicine.

We report a patient with CPRS who was intensively treated, as an inpatient, with complex Korean medicine for more than one month whereby the patient's course of recovery could be observed. Not only were there no side effects, but CRPS symptoms that had persisted for more than 10 years, which had been treated with sympathetic nerve-blocking medication, pain relievers, corticosteroids, nerve blocks, and transcutaneous electrical nerve stimulation, were alleviated following Korean medicine treatment. Since there are not many experimental studies on the treatment of CRPS with Korean medicine, we believe reporting this case would lead to broader recognition and development of this treatment [18–20].

However, this study has some limitations. Firstly, this is a single case report and therefore the results from this study cannot be generalized. Secondly, the mechanism underlying this condition remains unknown. Thus, the practice of Korean medicine treatment for CRPS is mostly limited to personal experiences of Korean medicine practitioners. Thirdly, the therapeutic effects of Korean medicine could not be distinguished from the therapeutic effects of the other medicines the patient was taking during hospitalization (antihistamines, opioids, and psychiatric drugs). Large-scale randomized controlled trials are needed in the future to determine the effects of Korean medicine treatment for CRPS.

Complex Korean medicine may be helpful for alleviating symptoms of CPRS pain and improving quality of life.

Author Contributions

Conceptualization: JWP. Methodology: JWP. Formal investigation: JWP, MIJ, WJJ, HWH and JEK. Data analysis: JWP. Writing original draft: JWP. Writing – review and editing: JWP, SWC and DHK.

Conflicts of Interest

The authors declare that they have no competing interests.

Funding

None.

Ethical Statement

This research did not involve any human or animal experiments

Data Availability

All relevant data are included in this manuscript.

References

- [1] Ott S, Maihöfner C. Signs and Symptoms in 1,043 Patients with Complex Regional Pain Syndrome. *J Pain* 2018;19:599–611.
- [2] Mos M, Huygen FJPM, Dieleman JP, Koopman JSHA, Stricker CBH, Sturkenboom MCJM. Medical history and the onset of complex regional pain syndrome (CRPS). *Pain* 2008;139:458–466.
- [3] Rho RH, Brewer RP, Lamer TJ, Wilson PR. Complex regional pain syndrome. *Mayo Clin Proc* 2002;77:174–180.
- [4] Clark JD, Tawfik VL, Tajerian M, Kingery WS. Autoinflammatory and autoimmune contributions to complex regional pain syndrome. *Mol Pain* 2018;14:1744806918799127.
- [5] Knudsen LF, Terkelsen AJ, Drummond PD, Birklein F. Complex regional pain syndrome: A focus on the autonomic nervous system. *Clin Auton Res* 2019;29:457–467.
- [6] Tajerian M, Clark JD. New concepts in complex regional pain syndrome. *Hand Clin* 2016;32:41–49.
- [7] Harden RN, Oaklander AL, Burton AW, Perez RS, Richardson K, Swan M et al. Complex regional pain syndrome: Practical diagnostic and treatment guidelines, 4th edition. *Pain Med* 2013;14:180–229.
- [8] Eldufani J, Elahmer N, Blaise G. A medical mystery of complex regional pain syndrome. *Heliyon* 2020;6:e03329.
- [9] Hawker GA, Mian S, Kendzerska T, French M. Measures of adult pain: Visual Analog Scale for Pain (VAS Pain), Numeric Rating Scale for Pain (NRS Pain), McGill Pain Questionnaire (MPQ), Short-Form McGill Pain Questionnaire (SF-MPQ), Chronic Pain Grade Scale (CPGS), Short Form-36 Bodily Pain Scale (SF-36 BPS), and Measure of Intermittent and Constant Osteoarthritis Pain (ICOAP). *Arthritis Care Res (Hoboken)* 2011;63:240–252.
- [10] Vianin M. Psychometric properties and clinical usefulness of the Oswestry Disability Index. *J Chiropr Med* 2008;7:161–163.
- [11] Herdman M, Gudex C, Lloyd A, Janssen MF, Kind P, Parkin D et al. Development and preliminary testing of the new five-level version of EQ-5D (EQ-5D-5 L). *Qual Life Res* 2011;20:1727–1736.
- [12] Harden RN, Oaklander AL, Burton AW, Perez RSGM, Richardson K, Swan M et al. Complex regional pain syndrome: Practical diagnostic and treatment guidelines, 4th edition. *Pain Med* 2013;14:180–229.
- [13] O'Connell NE, Wand BM, McAuley J, Marston L, Moseley GL. Interventions for treating pain and disability in adults with complex regional pain syndrome. *Cochrane Database Syst Rev* 2013;2013:CD009416.
- [14] Jin BX, Jin LL, Jin GY. The anti-inflammatory effect of acupuncture and its significance in analgesia. *World J Acupunct Moxibustion* 2019;1:1–6.
- [15] Xiao LY, Wang XR, Yang Y, Yang JW, Cao Y, Ma SM et al. Applications of Acupuncture Therapy in Modulating Plasticity of Central Nervous System. *Neuromodulation* 2018;21:762–776.
- [16] Chung HJ, Lee HS, Shin JS, Lee SH, Park BM, Youn YS et al. Modulation of acute and chronic inflammatory processes by a traditional medicine preparation GCSB-5 both in vitro and in vivo animal models. *J Ethnopharmacol* 2010;130:450–459.
- [17] Kim TH, Yoon SJ, Lee WC, Kim JK, Shin J, Lee S et al. Protective effect of GCSB-5, an herbal preparation, against peripheral nerve injury in rats. *J Ethnopharmacol* 2011;136:297–304.
- [18] Kim SY, Kim SW, Kim DW, Kang KR, Ha DH, Kim SY et al. A Case Report of a Patient Diagnosed with Complex Regional Pain Syndrome (Type 1) Improved by Integrative Korean Medical Treatment. *J Int Korean Med* 2018;39:895–903.
- [19] Hwang MH, Lee YK, Kim JS, Lee HJ, Lim SC. A Clinical Case Study of a Patient with Complex Regional Pain Syndrome (CRPS) Type I Treated by 8 Constitution Acupuncture. *Acupunct* 2016;33:181–187.
- [20] Jo HJ, Kim JY, Kim YS, Nam SS. Complex Regional Pain Syndrome (CRPS) type I Patient Treated with complex traditional Korean medicine: A Case Report. *J Spine Joint Korean Med* 2015;12:55–63.