

Review Article



OPEN ACCESS

Received: Apr 20, 2022
Revised: Jun 28, 2022
Accepted: Sep 21, 2022
Published online: Nov 2, 2022

Correspondence to

Merve Güvenoğlu

Department of Pediatric Genetics, Hacettepe University Faculty of Medicine, Ankara 06100, Turkey.

Email: merveguvenoglu@hacettepe.edu.tr









Copyright © 2022 by The Korean Society of Pediatric Gastroenterology, Hepatology and Nutrition

This is an open-access article distributed under the terms of the Creative Commons Attribution Non-Commercial License (<https://creativecommons.org/licenses/by-nc/4.0/>) which permits unrestricted non-commercial use, distribution, and reproduction in any medium, provided the original work is properly cited.

ORCID iDs

Merve Güvenoğlu 
<https://orcid.org/0000-0003-2368-5797>
Pelin Özlem Şimşek-Kiper 
<https://orcid.org/0000-0001-7244-7766>
Can Koşukcu 
<https://orcid.org/0000-0002-6129-0510>
Ekim Z. Taskiran 
<https://orcid.org/0000-0001-6040-6625>
İnci Nur Saltık-Temizel 
<https://orcid.org/0000-0002-5580-5100>
Safak Gucer 
<https://orcid.org/0000-0002-6021-4612>
Eda Utine 
<https://orcid.org/0000-0001-6577-5542>
Koray Boduroğlu 
<https://orcid.org/0000-0001-6260-1942>

Homozygous Missense Epithelial Cell Adhesion Molecule Variant in a Patient with Congenital Tufting Enteropathy and Literature Review

Merve Güvenoğlu ¹, **Pelin Özlem Şimşek-Kiper** ¹, **Can Koşukcu** ²,
Ekim Z. Taskiran ³, **İnci Nur Saltık-Temizel** ⁴, **Safak Gucer** ⁵, **Eda Utine** ¹
and **Koray Boduroğlu** ¹

¹Department of Pediatric Genetics, Hacettepe University Faculty of Medicine, Ankara, Turkey

²Department of Bioinformatics, Institute of Health Sciences, Hacettepe University, Ankara, Turkey

³Department of Medical Genetics, Hacettepe University Faculty of Medicine, Ankara, Turkey

⁴Department of Pediatric Gastroenterology, Hepatology, and Nutrition, Hacettepe University Faculty of Medicine, Ankara, Turkey

⁵Division of Pediatric Pathology, Department of Pediatrics, Hacettepe University, Ankara, Turkey

ABSTRACT

Congenital diarrheal disorders (CDDs) with genetic etiology are uncommon hereditary intestinal diseases characterized by chronic, life-threatening, intractable watery diarrhea that starts in infancy. CDDs can be mechanistically divided into osmotic and secretory diarrhea. Congenital tufting enteropathy (CTE), also known as intestinal epithelial dysplasia, is a type of secretory CDD. CTE is a rare autosomal recessive enteropathy that presents with intractable neonatal-onset diarrhea, intestinal failure, severe malnutrition, and parenteral nutrition dependence. Villous atrophy of the intestinal epithelium, crypt hyperplasia, and irregularity of surface enterocytes are the specific pathological findings of CTE. The small intestine and occasionally the colonic mucosa include focal epithelial tufts. In 2008, Sivagnanam et al. discovered that mutations in the epithelial cell adhesion molecule (*EpCAM*, MIM# 185535) were the genetic cause of CTE (MIM# 613217). More than a hundred mutations have been reported to date. Furthermore, mutations in the serine peptidase inhibitor Kunitz type 2 (*SPINT2*, MIM# 605124) have been linked to syndromic CTE. In this study, we report the case of a 17-month-old male infant with congenital diarrhea. Despite extensive etiological workup, no etiology could be established before admission to our center. The patient died 15 hours after being admitted to our center in a metabolically decompensated state, probably due to a delay in admission and diagnosis. Molecular autopsy with exome sequencing revealed a previously reported homozygous missense variant, c.757G>A, in *EpCAM*, which was confirmed by histopathological examination.

Keywords: Infantile diarrhea; Epithelial cell adhesion molecule; Whole exome sequencing; Diagnostic molecular pathology

Conflict of Interest

The authors have no financial conflicts of interest.

INTRODUCTION

Congenital diarrheal disorders (CDDs) are rare intestinal diseases characterized by chronic, life-threatening, intractable watery diarrhea that starts in infancy, and most cases are caused by genetic defects [1]. CDDs can be mechanistically divided into osmotic and secretory diarrhea. Congenital tufting enteropathy (CTE), also known as intestinal epithelial dysplasia [2], is a secretory CDD. CTE is a rare autosomal recessive enteropathy first defined by Reifen et al. [3] in 1994. The prevalence of CTE is 1 in 50,000-100,000 live births in western Europe. CTE is characterized by intractable watery diarrhea and severe malnutrition. Intractable diarrhea is independent of breast or formula feeding, and most patients with CTE depend on parenteral nutrition (PN) to gain weight [4]. Patients with CTE may present with extraintestinal findings, such as choanal atresia, ophthalmologic findings, and dysmorphic facial features representing syndromic forms of CTE [5,6]. Villous atrophy of the intestinal epithelium, crypt hyperplasia, and irregularity of surface enterocytes are specific pathological findings in CTE [7]. The small intestine and occasionally the colonic mucosa exhibit focal epithelial tufts [8]. Intestinal epithelial cells form tufts by rounding the plasma membrane and forming a teardrop-shaped structure [9]. In 2008, Sivagnanam et al. [10] discovered that mutations in the epithelial cell adhesion molecule (*EpCAM*, MIM#185535) cause CTE. Furthermore, mutations in the serine peptidase inhibitor Kunitz type 2 (*SPINT2*, MIM#605124) have been linked to syndromic CTE [6].

A molecular autopsy involves the analysis of the DNA of deceased patients to determine whether they had a genetic mutation that contributed to their death. Recently, next-generation sequencing or exome sequencing (ES) has been used to identify new mutations that could underlie and perhaps explain the unknown cause in deceased patients [11,12]. In this study, we aimed to report the clinical, histopathological, and molecular features of a patient with CTE in whom molecular autopsy revealed a homozygous missense variant in *EpCAM*, along with a review of the literature.

Clinical report

A 17-month-old infant was admitted to our hospital with intractable watery diarrhea that began after birth and occurred 7-8 times per day. The patient was born to a G₂P₂PPex₁ mother by cesarean section at 35 weeks of gestation with a birth weight of 2,700 g. The prenatal history was complicated by gestational hypertension. The parents were consanguineous (first cousins) and healthy. The family history was remarkable for a similarly affected sibling who was born at term and died on postnatal day 15 of intractable watery diarrhea. An autopsy was not performed, and no diagnosis was established.

Before his admission to our center, the patient was frequently hospitalized because of diarrhea and recurrent infections with malnutrition, dehydration, and electrolyte imbalance. Despite extensive laboratory workup, no definitive diagnosis could be established. Endoscopy and colonoscopy were performed, and histopathological examination of the duodenal biopsy specimen revealed villous atrophy, crypt hyperplasia, and intraepithelial lymphocyte accumulation. Stool microscopy revealed *Giardia lamblia*, which required treatment with metronidazole. Blood and stool cultures were negative. Although he gained weight within the first three months of life, his diarrhea worsened after the third month, and he started to lose weight. Despite lactose-free or amino-acid-based formulas, diarrhea continued, and he gained only 300 g within 17 months.

On admission, the patient had fever, tachycardia, and severe malnutrition. His body weight was 3,600 g (−9.7 standard deviation score [SDS]), body length was 61 cm (−7.7 SDS), and occipitofrontal circumference was 40 cm (−5.49 SDS). He looked dehydrated, and the skin turgor decreased. He was hypoactive. Laboratory evaluation revealed metabolic acidosis with a blood pH of 7.19 (normal range, 7.26–7.42) and bicarbonate of 9.9 mmol/L (normal range, 22.5–26.9 mmol/L). He had hyponatremia and hyperuricemia with serum sodium and uric acid levels of 127 mEq/L (normal range 136–146 mEq/L) and 8.9 mg/dL (normal range 3.5–7.2 mg/dL), respectively. The C-reactive protein test was negative. The patient received parenteral hydration with bicarbonate, enteral nutrition with lactose-free formula, and antibiotics. However, his clinical condition deteriorated during follow-up, and he died 15 hours after hospitalization. The family provided consent for the autopsy and molecular genetic tests.

MATERIALS AND METHODS

Genomic DNA was extracted using a salting-out procedure from the peripheral blood of the affected individual and unaffected parents after obtaining written informed consent. This study was approved by the Hacettepe University Ethics Committee (GO 15-530/25). To determine genetic etiology, ES was performed on the affected individual. Sanger sequencing was performed to validate this variant and analyze the segregation. We reviewed all published cases, including 22 articles and 116 patients. Articles were included if they reported clinical data of patients with CTE linked to *EpCAM* mutations. Articles without clinical data, such as reviews, animal models, or functional studies, were not included. A systematic search was conducted from 2008, when *EpCAM* was identified as a gene for CTE, to 2022 in PubMed using the following terms: “*EpCAM* tufting enteropathy,” “*EpCAM* diarrhea,” and “*EpCAM* exome”. For all patients, data on coding DNA, type of mutation, zygosity, ethnicity, symptoms, consanguinity, treatment, and outcomes were recorded (Table 1).

Exome sequencing

The Ion AmpliSeq Exome RDY Kit (Thermo Fisher Scientific, Waltham, MA, USA) was used for exome library preparation. Emulsion polymerase chain reaction was performed on an Ion OneTouch 2 instrument using the Ion PI Hi-Q OT2 200 Kit (Thermo Fisher Scientific) according to the manufacturer’s instructions. The enrichment of the Ion Sphere particles (ISPs) was performed using the OneTouch ES module. ISPs were loaded on Ion PI chips and sequenced with the Ion Proton platform (Thermo Fisher Scientific).

Bioinformatic analysis

ES was performed for the index case. The variant filtering steps were performed as previously described [13]. All variants that passed the quality score filters were annotated using Ion Reporter 5.10 software. Exonic and non-synonymous rare variants (minimum allele frequency < 0.01) were selected for in-house filtering. Subsequently, alterations in the boundaries of runs of homozygosity (ROH) regions ≥ 1 Mb within all chromosomes were extracted. We used HomSI, a software that maps disease loci by single nucleotide polymorphism genotyping using a variant call format file obtained from the ES data, to identify the ROH in index cases. Finally, variants that were observed in the ExAC Browser (in the homozygous state) were ruled out.

Homozygous Missense EpCAM Variant in a Patient with CTE and Review of the Literature

Table 1. Variants of *EpCAM* in CTE patients

Study	Patient	Year	Coding DNA	Type of mutation	Zygoty	Ethnicity	Sypmtoms	Consanguinity in family	Treatment	Outcome
Sivagnanam et al. [10]	P1.1, P1.2 (cousins)	2008	c.491+1G>A (intron 4)	Noncoding-splicing mutation	Homozygous	Mexican American	Diarrhea	None	PN	Unknown
	P2		c.427-1G>A (intron 4)	Noncoding-splicing mutation	Homozygous	Native Canadian	Diarrhea	None	PN	Unknown
	P3		c.200G>A (exon 3)	Missense mutation	Heterozygous	English/Italian	Diarrhea	Yes	PN	Unknown
Al-Mayouf et al. [15]	P1	2009	c.498insC (exon 5)	Frameshift mutation	Homozygous	Arabic	Diarrhea, chronic arthritis [†]	Yes	PN	Unknown
Sivagnanam et al. [27]	P1	2010	c.412C>T (exon 3)	Nonsense mutation	Homozygous	Pakistani	Diarrhea	Yes	PN	Unknown
Ko et al. [22]	P1.1, P1.2 (siblings)	2010	c.491+1G>A (intron 4)/c.316A>T (exon 3)	Noncoding-splicing mutation/nonsense mutation	Compound heterozygous	Korean	Diarrhea, oligoarticular juvenile rheumatoid arthritis (P1.1) [†]	None	PN	Alive
Salomon et al. [24]	P1	2010	c.492-2A>G (intron 5)	Noncoding-splicing mutation	Homozygous	Arabic	Diarrhea	Yes	PN	Unknown
	P2.1, P2.2 (siblings)		c.498insC (exon 5)	Frameshift mutation	Homozygous	Arabic	Diarrhea	Yes	PN	Unknown
	P3		c.498insC (exon 5)	Frameshift mutation	Homozygous	Arabic	Diarrhea	Yes	PN	Unknown
	P4		c.492-2A>G (intron 5)/c.498insC (exon 5)	Noncoding-splicing mutation/frameshift mutation	Compound heterozygous	Arabic	Diarrhea	Yes	PN	Unknown
	P5.1, P5.2 (siblings)		c.498insC (exon 5)	Frameshift mutation	Homozygous	Arabic	Diarrhea	Yes	PN	Unknown
	P6.1, P6.2 (second cousins)		c.498insC (exon 5) (P6.1), Frameshift mutation c.492-2A>G (intron 5)/c.498insC (exon 5) (P6.2)	Frameshift mutation (P6.1), noncoding-splicing mutation/frameshift mutation (P6.2)	Homozygous (P6.1), compound heterozygous (P6.2)	Arabic	Diarrhea	Yes	PN	Unknown
	P7.1, P7.2 (siblings)		c.498insC (exon 5)	Frameshift mutation	Homozygous	Arabic	Diarrhea	Yes	PN	Unknown
Thoeni et al. [29]	P1	2013	c.227C>G (exon 3)	Nonsense mutation	Homozygous	East African	Diarrhea	Yes	PN	Alive
Pégas et al. [32]	P1	2014	c.556-14A>G (intron 6)	Noncoding-splicing mutation	Homozygous	Brazilian	Diarrhea	Unknown	PN	Alive
Salomon et al. [25] (39 patients)	P1	2014	c.139C>T/? (exon 2)	Noncoding-splicing mutation	Heterozygous	Italian	Diarrhea		PN	Alive
	P2		c.227C>G (exon 3)	Nonsense mutation	Homozygous	Turkish	Diarrhea		PN	Alive
	P3		c.227C>G (exon 3)/c.555+1G>C (intron 5)	Nonsense mutation/noncoding-splicing mutation	Compound heterozygous	Italian	Diarrhea		PN	Alive
	P4		c.307G>A (exon 3)	Missense mutation	Homozygous	Italian	Diarrhea		PN	Alive
	P5		c.314T>G (exon 3)	Missense mutation	Homozygous	Sri Lankan	Diarrhea		PN	Alive
	P6		c.321delC (exon 3)	Noncoding-splicing mutation	Homozygous	Mali	Diarrhea		PN	Deceased
	P7.1, P7.2		c.352_368del (exon 3)	Frameshift mutation	Homozygous	Moroccan	Diarrhea	45% consanguineous in family	ITx (P7.1), PN (P7.2)	Alive
	P8		c.359A>T (exon3)	Missense mutation	Homozygous	Algerian	Diarrhea		PN	Alive
	P9		c.380C>T/? (exon3)	Missense mutation/?	Heterozygous	Algerian	Diarrhea		PN	Alive
	P10		c.394G>T (exon 3)	Nonsense mutation	Homozygous	Egyptian	Diarrhea		ITx (at 5 years)	Alive
	P11		c.467delC (exon 4)/c.492-1G>A (intron 5)	Frameshift mutation/noncoding-splicing mutation	Compound heterozygous	French	Diarrhea		ITx (at 7 years)	Alive
	P12		c.492-2A>G (intron 5)	Noncoding-splicing mutation	Homozygous	Kuwaiti	Diarrhea		Unknown	Unknown
	P13		c.492-2A>G (intron 5)/c.498insC (exon 5)	Noncoding-splicing mutation/frameshift mutation	Compound heterozygous	Kuwaiti	Diarrhea		PN	Alive

(continued to the next page)

Homozygous Missense EpCAM Variant in a Patient with CTE and Review of the Literature

Table 1. (Continued) Variants of *EpCAM* in CTE patients

Study	Patient	Year	Coding DNA	Type of mutation	Zygosity	Ethnicity	Sypmtoms	Consanguinity in family	Treatment	Outcome
	P14.1, P14.2		c.492-2A>G (intron 5)/c.498insC (exon 5)	Noncoding-splicing mutation/frameshift mutation	Compound heterozygous	Kuwaiti	Diarrhea		PN	Deceased (P14.1), alive (P14.2)
	P15		c.492_555del (exon 5)	Deletion	Homozygous	French	Diarrhea		ITx (at 4 years)	Alive
	P16		c.498insC (exon 5)	Frameshift mutation	Homozygous	Kuwaiti	Diarrhea		PN	Alive
	P17.1, P17.2		c.498insC (exon 5)	Frameshift mutation	Homozygous	Kuwaiti	Diarrhea		Unknown	Unknown
	P18		c.498insC (exon 5)	Frameshift mutation	Homozygous	Kuwaiti	Diarrhea		PN	Deceased
	P19.1, P19.2		c.498insC (exon 5)	Frameshift mutation	Homozygous	Kuwaiti	Diarrhea		PN	Deceased
	P20.1, P20.2		c.498insC (exon 5)	Frameshift mutation	Homozygous	Qatari	Diarrhea		Unknown	Unknown
	P21		c.498insC (exon 5)	Frameshift mutation	Homozygous	Kuwaiti	Diarrhea		Unknown	Unknown
	P22		c.555+1G>C (intron 5)	Noncoding-splicing mutation	Homozygous	Turkish	Diarrhea, keratoderm [†]		ITx (at 5 years)	Alive
	P23		c.555+1G>C (intron 5)	Noncoding-splicing mutation	Homozygous	Turkish	Diarrhea		ITx (at 11 years)	Alive
	P24		c.556-14A>G (intron 6)	Noncoding-splicing mutation	Homozygous	Morroccan	Diarrhea, arthritis [†]	45% consanguineous in family	PN	Alive
	P25		c.556-14A>G (intron 6)	Noncoding-splicing mutation	Homozygous	Morroccan	Diarrhea		PN	Alive
	P26		c.556-14A>G (intron 6)	Noncoding-splicing mutation	Homozygous	Algerian	Diarrhea		PN	Alive
	P27		c.556-14A>G (intron 6)	Noncoding-splicing mutation	Homozygous	Algerian	Diarrhea		PN	Alive
	P28		c.556-14A>G (intron 6)	Noncoding-splicing mutation	Homozygous	Portugal	Diarrhea		PN	Deceased
	P29		c.556-14A>G/? (intron 6)	Noncoding-splicing mutation	Heterozygous	Morroccan	Diarrhea, arthritis, oesophageal atresia [†]		PN	Alive
	P30.1, P30.2		c.556-14A>G (intron 6)/c.654delA (exon 6)	Noncoding-splicing mutation/frameshift mutation	Compound heterozygous	Italian	Diarrhea		ITx (at 9 years)	Alive
	P31		Del Ex 1-4	Deletion	Homozygous	Turkish	Diarrhea		PN	Alive
	P32		Del Ex 1-7	Deletion	Homozygous	Turkish	Diarrhea		PN	Alive
	P33		Del <i>EpCAM</i>	Deletion	Homozygous	Algerian	Diarrhea	ITx (at 12 years)	Alive	
Haas et al. [20]	P1.1, P1.2 (siblings)	2016	NA	NA	Homozygous	Unknown	Diarrhea	Unknown	PN	Alive
d'Apolito et al. [18]	P1.1, P1.2 (siblings)	2016	c.654delA (exon 6)/c.556-14A>G (intron 6) (P1.1, P1.2)	Frameshift mutation/noncoding-splicing mutation (P1.1, P1.2)	Compound heterozygous (P1.1, P1.2)	Italian	Diarrhea	None	ITx (P1.1 at 10 years, P1.2 at 11 years)	Deceased (P1.1, P1.2)
	P2		c.437T>A (exon 4)	Missense mutation	Heterozygous	Italian	Diarrhea	None	PN	Alive
Tang et al. [7]	P1	2016	c.307G>A (exon 3)/deletion (exon 2-5)	Missense mutation	Compound heterozygous	Chinese	Diarrhea	None	PN	Alive
AlMahamed and Hammo et al. [14]	P1	2017	c.498insC (exon 5)	Frameshift mutation	Homozygous	Arabic	Diarrhea	Yes	PN, ITx at 4 years	Alive
	P2		c.498insC (exon 5)	Frameshift mutation	Homozygous	Arabic	Diarrhea	Yes	PN	Deceased
	P3		Homozygous deletion of whole gene	Deletion	Homozygous	Arabic	Diarrhea	None	PN	Deceased
	P4		c.412C>T (exon 3)	Nonsense mutation	Homozygous	Arabic	Diarrhea	Yes	PN, ITx at 2.5 years	Alive
Bodian et al. [17]	P1.1, P1.2 (second cousins)	2017	c.556-14A>G (intron 6)	Noncoding-splicing mutation	Homozygous	Hispanic	Diarrhea, dilate cardiomyopathy (unexplained) (P1) [†]	None (?)	PN	Deceased (P1.1), alive (P1.2)
Tan et al. [28]	P1	2017	c.38_62dup25 (exon 1)+c.1A>C (exon1)	Frameshift mutation+ Missense mutation	Homozygous (for two different <i>EpCAM</i> variants)	Unknown	Diarrhea	Yes	PN	Alive
Shakhnovich et al. [26]	P1	2018	c.426-1G>A (intron 4)/c.265C>T (exon 3)	Noncoding-splicing mutation/nonsense mutation	Compound heterozygous	Caucasian	Diarrhea	None	PN	Alive

(continued to the next page)

Homozygous Missense EpCAM Variant in a Patient with CTE and Review of the Literature

Table 1. (Continued) Variants of *EpCAM* in CTE patients

Study	Patient	Year	Coding DNA	Type of mutation	Zygoty	Ethnicity	Sypmtoms	Consanguinity in family	Treatment	Outcome
Chuanjie et al. [33]	P1	2018	c.412C>T (exon 3)	Missense mutation	Homozygous	Chinese	Diarrhea	Unknown	PN	Unknown
Pathak et al. [23] (17 patients; many of whom were from families without consanguinity)	P1	2019	c.113G>A (exon 2)/c.48_68del21 (exon 1)	Missense mutation/ inframe deletion	Compound heterozygous	Caucasian	Diarrhea	Unknown	PN	Alive
	P2		c.1A>C (exon 1)/c.38_62dup25 (exon 1)	Missense mutation/ frameshift mutation	Compound heterozygous	Palestinian	Diarrhea	Unknown	PN	Alive
	P3		c.267G>C (exon 3)/c.118T>C (exon 2)	Missense mutation/ unknown	Compound heterozygous	English	Diarrhea	Unknown	PN	Alive
	P4		c.307G>A (exon 3)/c.492-5T>C (intron 5)	Missense mutation/ noncoding-splicing mutation	Compound heterozygous	English/ Italian	Diarrhea	Unknown	PN	Alive
	P5.1, P5.2		c.491+1G>A (intron 4)/c.556-14A>G (intron 6)	Noncoding-splicing mutation	Compound heterozygous	Bangladeshi	Diarrhea	Unknown	PN	Alive
	P6		c.492-1G>A (intron 5)/c.491+1G>A (intron 4)	Noncoding-splicing mutation	Compound heterozygous	Hispanic	Diarrhea	Unknown	PN	Alive
	P7		c.509_511delTCA (exon 5)	In-frame deletion	Homozygous	Pakistani	Diarrhea	Unknown	PN	Alive
	P8		c.555+1G>C (intron 5)	Noncoding-splicing mutation	Homozygous	Turkish	Diarrhea	Unknown	PN	Alive
	P9.1, P9.2		c.579delT (exon 6)	Frameshift mutation	Homozygous	Bedouin	Diarrhea	Unknown	PN	Alive
	P10		c.589C>T (exon 6)	Nonsense mutation	Homozygous	Iraqi	Diarrhea	Unknown	PN	Alive
	P11.1, P11.2		c.540delT (exon 5)/c.491+1G>A (intron 4)	Frameshift mutation/ noncoding-splicing mutation	Compound heterozygous	Unknown	Diarrhea	Unknown	PN	Alive
	P12		c.757G>A (exon 7)	Missense mutation	Homozygous	Turkish	Diarrhea	Unknown	PN	Alive
	P13		Deletion (end of exon 1 and intron 3-4)	Deletion	Homozygous	Hispanic	Diarrhea	Unknown	PN	Alive
	P14		c.227C>G (exon 3)	Nonsense mutation	Homozygous	Israeli	Diarrhea	Unknown	PN	Alive
Hassan et al. [21] (18 patients)	P1-P18*	2019	c.498insC (exon 5)	Frameshift mutation	Homozygous	Qataris	Diarrhea	Yes (86%)	PN, ITx (17%)	Deceased (50%), alive (50%)
Fang et al. [19]	P1	2019	c.491+1G>A (intron 4)	Noncoding-splicing mutation	Homozygous	Chinese	Diarrhea	None	PN	Deceased
Zhou et al. [31]	P1	2020	c.657+1G>A (intron 6)	Noncoding-splicing mutation	Homozygous	Chinese	Diarrhea	None	PN	Alive
Yan et al. [30]	P1	2021	c.184+6T>G (intron 2)/ large deletion (exon 1-9)	Noncoding-splicing mutation/ large deletion	Compound heterozygous	Chinese	Diarrhea	None	PN	Deceased
	P2		c.96C>A (exon 2)/c.823delG (exon 7)	Nonsense mutation/ frameshift mutation	Compound heterozygous	Chinese	Diarrhea	None	PN	Alive
Ayyıldız Civan et al. [16]	P1	2021	c.1_46del (exon 1)	Frameshift mutation	Homozygous	Unknown	Diarrhea	Yes	PN	Alive
	P2.1, P2.2 (siblings)		c.326A>G (exon 3) (P2.1, P2.2.)	Missense mutation (P2.1, P2.2)	Homozygous	Unknown	Diarrhea	Yes	PN	Deceased (P2.1), alive (P2.2)
	P3		c.429G>A (exon 4)/c.556-14A>G (intron 6)	Nonsense mutation/ noncoding-splicing mutation	Compound heterozygous	Unknown	Diarrhea	None	PN	Alive

EpCAM: epithelial cell adhesion molecule, CTE: congenital tufting enteropathy, NA: not available, PN: parenteral nutrition, ITx: intestinal transplantation.

*Two siblings as part of a previously published study (Salomon et al. [24]).

†Extraintestinal symptoms.

Sanger sequencing

The *EpCAM* variant identified by ES was verified by DNA sequencing. For conventional sequencing, the BigDye Terminator v.3.1 Cycle Sequencing Kit and sequencing products were applied to an ABI 3500 genetic analyzer (Thermo Fisher Scientific). Sanger sequencing was also performed to evaluate cosegregation among family members.

RESULTS

The clinical findings of the present patient are shown in **Table 1**, along with the findings of patients reported to date in the literature. The initial histopathological findings of the patient's autopsy were villous atrophy and crypt hyperplasia without inflammation in the duodenum and destruction of the intestinal surface epithelium. Electron microscopy revealed villous atrophy in the duodenum, jejunum, ileum, and colon and decreased size and number of microvilli. The epithelium was regular and did not contain microvillus inclusions. These findings were not compatible with CTE, microvillus inclusion disease, and immune dysregulation polyendocrinopathy enteropathy X-linked. Villous atrophy was remarkable in celiac disease, but an increase in the number of intraepithelial lymphocytes was absent.

ES was performed for the index cases. After selection and filtering, we identified 35 candidate variants in 17 homozygous regions. Among these, we identified a homozygous c.757G>A missense variant in *EpCAM* (RefSeq Number: NM_002354.3; p.Asp253Asn) compatible with the disease phenotype in the affected individual (**Fig. 1A**). Genetic counseling for autosomal recessive disorders was provided to the family. The family was informed about the carrier testing of at-risk relatives, prenatal testing, and preimplantation genetic testing for future pregnancies.

After the detection of the *EpCAM* variant, the histopathological findings of the patient were reviewed. A thorough histological examination of the slides and deeper sections revealed villus abnormalities, including epithelial crowding, disorganization, and focal tufting with no epithelial lymphocytosis (**Fig. 1B**).

EpCAM variants causing the CTE

After a comprehensive analysis of previous reports on CTE and *EpCAM*, we found 140 mutations (48 different *EpCAM* mutations in 116 patients) in *EpCAM* from 22 studies, including missense, nonsense, frameshift, noncoding/splicing mutations, and chromosomal deletions (**Table 1, Fig. 2**) [7,10,14-33]. Among them, pathogenic variants c.491+1G>A (intron 4), c.556-14A>G (intron 6), c.492-2A>G (intron 5), and c.498insC (exon 5) were reported in five or more patients (**Fig. 2B**). The frameshift mutation (c.498insC) was the most common

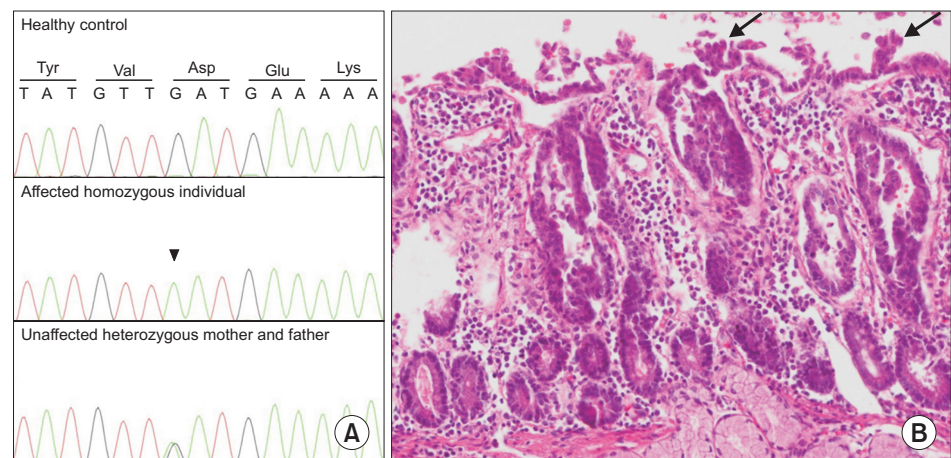


Fig. 1. (A) Sanger Sequencing of healthy control, affected individual (homozygous c.757G>A variant), and unaffected mother and father (heterozygous c.757G>A variant). (B) Staining with hematoxylin and eosin revealed villus abnormalities, including epithelial crowding, disorganization, and focal tufting (arrows) with no epithelial lymphocytosis shown at 400× magnification.

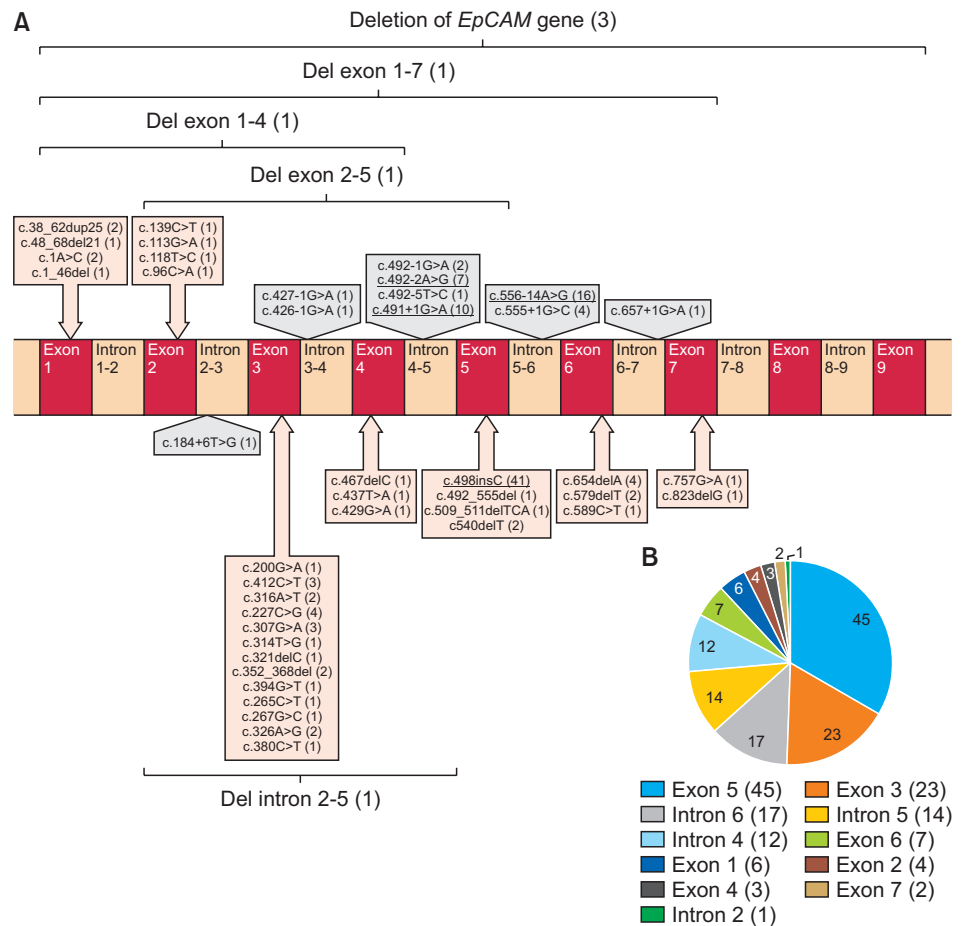


Fig. 2. (A) Pathogenic *EpCAM* variants identified in patients with CTE. Schematic diagram of the *EpCAM* gene illustrating 48 variants to date. The number of patients carrying variants in parentheses (the most common variants were reported in five or more patients are underlined). (B) The number of patients carrying mutations in different exons/introns (the number of patients carrying variants in parentheses). *EpCAM*: epithelial cell adhesion molecule, CTE: congenital tufting enteropathy.

mutation in all patients with CTE. Many patients (84 of 116, 72.4%) were homozygous for *EpCAM* mutations, and most of the remaining patients were compound heterozygotes (27 of 116 patients, 23.2%) (**Table 1**). The disease is more common in consanguineous families, such as those seen in Middle Eastern populations.

Clinically, patients with *EpCAM* variants mainly present with isolated congenital diarrhea. Only a few patients had extraintestinal symptoms, such as arthritis (2 patients) [15,25], oligoarticular juvenile rheumatoid arthritis (1 patient) [22], unexplained dilated cardiomyopathy (1 patient) [17], keratoderma (1 patient) [25], and esophageal atresia (1 patient) [25]. CTE is a life-threatening disease characterized by persistent, severe diarrhea. Of the 90 patients for whom data were available, 23 (25.5%) died. In most patients, CTE causes irreversible intestinal failure; therefore, intestinal transplantation (ITx) is required in severe cases. Of the 110 patients for whom data were available, 13 (11.8%) required ITx (**Table 1**).

DISCUSSION

In this study, we identified a homozygous missense variant of *EpCAM* in a patient presenting with congenital diarrhea. The initial histopathological examination during the patient's autopsy was inconclusive. However, molecular autopsy with the aid of ES revealed a homozygous missense variant in *EpCAM*, which further contributed to the detection of tufts in the histopathological specimen after the reevaluation of the autopsy material.

CTE is a rare autosomal recessive enteropathy that presents with intractable neonatal-onset diarrhea, intestinal failure, severe malnutrition, and PN dependence [3]. Most patients with CTE have significant intestinal malabsorption and diarrhea, requiring long-term full PN; however, positive outcomes with definitive weaning from PN have also been reported [34]. In general, laboratory workup and imaging methods do not contribute to the diagnosis of CTE in most patients [2]. Patients suspected of having CTE usually undergo endoscopy and colonoscopy, during which mucosal biopsies are performed in multiple regions. Histological abnormalities in the intestines of CTE patients include total or partial villous atrophy, crypt hyperplasia without inflammation, and basement membrane abnormalities. Focal epithelial tufts were observed from the duodenum to the large intestine. In most patients, typical abnormalities are localized primarily to the surface epithelium, forming focal epithelial "tufts" that consist of tightly packed enterocytes with rounding of the plasma membrane, shaping a tear-like structure by the cells [3,8]. Sometimes, these characteristic tufts could be absent in the biopsy of patients with early CTE with typical clinical symptoms, as was the case in the present patient. Despite extensive laboratory workup, imaging methods, and histopathologic findings, no specific diagnosis could be established. However, molecular autopsy with the aid of ES identified a homozygous c.757G>A missense variant in *EpCAM*.

The *EpCAM* gene maps to chromosome 2p21 and encodes a 40 kDa transmembrane glycoprotein consisting of an extracellular domain (encoded by exon 1–6), a single transmembrane domain (encoded by exon 7), and an intracellular domain (encoded by exon 8–9). In addition, the thyroglobulin homology domain, N-domain, and C-domain are three compactly folded extracellular domains. *EpCAM* is involved in cell signaling, proliferation, differentiation, and organ morphology development and maintenance [35]. *EpCAM* (MIM #185535) variants were identified in the genetic etiology of CTE by Sivagnanam et al. [10] in 2008. Since then, more than 100 *EpCAM* variants have been identified (Table 1, Fig. 2) [36]. The frameshift pathogenic variant (c.498insC) in exon 5 is the most common form in all patients with CTE [15]. Although the c.498insC homozygous pathogenic variant in exon 5 is common in the Middle East, exon 3 pathogenic variants are more common in East Asia [7,24]. The exon regions in which the most frequent pathogenic variants are defined vary across different populations.

We identified a homozygous c.757G>A missense variant in exon 7 of our patient. The variant was classified as "uncertain significance" according to ACMG 2015 guidelines and predicted to be "disease causing" by MutationTaster. The combined annotation-dependent depletion score was 28.2 (deleterious). *EpCAM* missense mutations encoding single amino acid substitutions primarily affected the extracellular thyroglobulin homology domain and internal portions of the extracellular C-terminal domain of *EpCAM*, consistent with the hypothesis that defects in cell-cell interactions are causal in CTE. The missense variant c.757G>A, p.(Asp253Asn) affects residues at one of the two contact regions between the thyroglobulin homology domain and the C-terminal domain [23]. Although this variant has

not been previously submitted to ClinVar, a Turkish patient with the same variant presenting with neonatal-onset intractable diarrhea who is still alive with full PN support has previously been reported in the literature [23].

Pathak et al. [23] hypothesized that some differential clinical outcomes, including nutritional data/PN status, need for intestinal transplantation, and mortality, could be used as markers of disease severity. The patients were classified into genotypic groups in which *EpCAM* alleles were mapped to categories (frameshift mutations, nonsense mutations, missense mutations, and splicing defects) to investigate these data for evidence of genotype-phenotype correlation. Patients with frameshift mutations were more likely to require total PN and to have died, suggesting that frameshift mutations are consistent with more severe disease. In contrast, splice site mutations are more common in patients who require PN only partially. Neither nonsense nor missense mutations were significantly associated with any clinical outcome [23]. Our findings verified that frameshift mutations were more common in patients who died (13 of 23 patients). In contrast, noncoding/splicing mutations (four patients), mixed mutations (four patients), missense mutations (one patient), and deletions (one patient) were less common in deceased patients (**Table 1**). These data suggest that frameshift mutations correlate with more aggressive treatment and poorer outcomes. Despite having a missense mutation, our patient died during infancy, probably due to a delay in the admission and diagnosis. Despite progress in nutritional management, the patient died of complications from severe malnutrition. Therefore, patients with early-onset severe diarrhea should be referred to a specialized center to avoid malnutrition and plan the diagnostic workup. Although there is evidence that frameshift mutations are associated with a more severe phenotype in general, establishing specific genotype/phenotype correlations in CTE is complicated by several factors, including the rarity of CTE, presence of compound heterozygotes, and lack of standard quantitative assessments for disease severity. The development of quantitative CTE severity assessments is required to investigate genotype-phenotype correlations and to guide patient treatment and prognosis.

CONCLUSION

Since the genetic etiology of CTE was discovered, there has been considerable progress in molecular diagnosis, particularly with the wide use of ES in clinical practice over the past ten years. Molecular diagnosis with ES provides early diagnosis and treatment and prevents invasive procedures in the diagnostic approach for these patients.

ACKNOWLEDGEMENTS

The authors thank the patient's parents for their participation in the study. This study was supported by Hacettepe University Scientific Research Unit under the project entitled Hacettepe Exome Project (Grant ID: TAY 2015-7335).

REFERENCES

1. Terrin G, Tomaiuolo R, Passariello A, Elce A, Amato F, Di Costanzo M, et al. Congenital diarrheal disorders: an updated diagnostic approach. *Int J Mol Sci* 2012;13:4168-85.
[PUBMED](#) | [CROSSREF](#)

2. Sherman PM, Mitchell DJ, Cutz E. Neonatal enteropathies: defining the causes of protracted diarrhea of infancy. *J Pediatr Gastroenterol Nutr* 2004;38:16-26.
[PUBMED](#) | [CROSSREF](#)
3. Reifen RM, Cutz E, Griffiths AM, Ngan BY, Sherman PM. Tufting enteropathy: a newly recognized clinicopathological entity associated with refractory diarrhea in infants. *J Pediatr Gastroenterol Nutr* 1994;18:379-85.
[PUBMED](#) | [CROSSREF](#)
4. Gambarara M, Diamanti A, Ferretti F, Papadatou B, Knafelz D, Pietrobbattista A, et al. Intractable diarrhea of infancy with congenital intestinal mucosa abnormalities: outcome of four cases. *Transplant Proc* 2003;35:3052-3.
[PUBMED](#) | [CROSSREF](#)
5. Roche O, Putterman M, Salomon J, Lacaille F, Brousse N, Goulet O, et al. Superficial punctate keratitis and conjunctival erosions associated with congenital tufting enteropathy. *Am J Ophthalmol* 2010;150:116-21.e1.
[PUBMED](#) | [CROSSREF](#)
6. Heinz-Erian P, Müller T, Krabichler B, Schranz M, Becker C, Rüschenendorf F, et al. Mutations in SPINT2 cause a syndromic form of congenital sodium diarrhea. *Am J Hum Genet* 2009;84:188-96.
[PUBMED](#) | [CROSSREF](#)
7. Tang W, Huang T, Xu Z, Huang Y. Novel mutations in EPCAM cause congenital tufting enteropathy. *J Clin Gastroenterol* 2018;52:e1-6.
[PUBMED](#) | [CROSSREF](#)
8. Goulet O, Kedinger M, Brousse N, Cuenod B, Colomb V, Patey N, et al. Intractable diarrhea of infancy with epithelial and basement membrane abnormalities. *J Pediatr* 1995;127:212-9.
[PUBMED](#) | [CROSSREF](#)
9. Goulet O, Salomon J, Ruemmele F, de Serres NP, Brousse N. Intestinal epithelial dysplasia (tufting enteropathy). *Orphanet J Rare Dis* 2007;2:20.
[PUBMED](#) | [CROSSREF](#)
10. Sivagnanam M, Mueller JL, Lee H, Chen Z, Nelson SF, Turner D, et al. Identification of EpCAM as the gene for congenital tufting enteropathy. *Gastroenterology* 2008;135:429-37.
[PUBMED](#) | [CROSSREF](#)
11. Opdal SH, Rognum TO. The sudden infant death syndrome gene: does it exist? *Pediatrics* 2004;114:e506-12.
[PUBMED](#) | [CROSSREF](#)
12. Heathfield LJ, Martin LJ, Ramesar R. A systematic review of molecular autopsy studies in sudden infant death cases. *J Pediatr Genet* 2018;7:143-9.
[PUBMED](#) | [CROSSREF](#)
13. Utine GE, Taşkıran EZ, Koşukcu C, Karaosmanoğlu B, Güleray N, Doğan ÖA, et al. HERC1 mutations in idiopathic intellectual disability. *Eur J Med Genet* 2017;60:279-83.
[PUBMED](#) | [CROSSREF](#)
14. AlMahamed S, Hammo A. New mutations of *EpCAM* gene for tufting enteropathy in Saudi Arabia. *Saudi J Gastroenterol* 2017;23:123-6.
[PUBMED](#) | [CROSSREF](#)
15. Al-Mayouf SM, Alswaid N, Alkuraya FS, Almehaidib A, Faqih M. Tufting enteropathy and chronic arthritis: a newly recognized association with a novel EpCAM gene mutation. *J Pediatr Gastroenterol Nutr* 2009;49:642-4.
[PUBMED](#) | [CROSSREF](#)
16. Ayyıldız Civan H, Leitner C, Östreicher I, Schneider AM, Cremer M, Mayr JA, et al. Three novel EPCAM variants causing tufting enteropathy in three families. *Children (Basel)* 2021;8:503.
[PUBMED](#) | [CROSSREF](#)
17. Bodian DL, Vilboux T, Hourigan SK, Jenevein CL, Mani H, Kent KC, et al. Genomic analysis of an infant with intractable diarrhea and dilated cardiomyopathy. *Cold Spring Harb Mol Case Stud* 2017;3:a002055.
[PUBMED](#) | [CROSSREF](#)
18. d'Apolito M, Pisanelli D, Faletta F, Giardino I, Gigante M, Pettoello-Mantovani M, et al. Genetic analysis of Italian patients with congenital tufting enteropathy. *World J Pediatr* 2016;12:219-24.
[PUBMED](#) | [CROSSREF](#)
19. Fang Y, Luo Y, Yu J, Chen J. A case of severe malnutrition infant with neonatal onset intractable diarrhea. *BMC Pediatr* 2020;20:133.
[PUBMED](#) | [CROSSREF](#)
20. Haas K, Martin B, Martín M, Kerner J. Intractable diarrhea in two brothers: late diagnosis of tufting enteropathy in adolescence. *Dig Dis Sci* 2016;61:381-3.
[PUBMED](#) | [CROSSREF](#)

21. Hassan K, Sher G, Hamid E, Hazima KA, Abdelrahman H, Al Mudahka F, et al. Outcome associated with EPCAM founder mutation c.499dup in Qatar. *Eur J Med Genet* 2020;63:104023.
[PUBMED](#) | [CROSSREF](#)
22. Ko JS, Seo JK, Shim JO, Hwang SH, Park HS, Kang GH. Tufting enteropathy with EpCAM mutations in two siblings. *Gut Liver* 2010;4:407-10.
[PUBMED](#) | [CROSSREF](#)
23. Pathak SJ, Mueller JL, Okamoto K, Das B, Hertecant J, Greenhalgh L, et al. EPCAM mutation update: variants associated with congenital tufting enteropathy and Lynch syndrome. *Hum Mutat* 2019;40:142-61.
[PUBMED](#) | [CROSSREF](#)
24. Salomon J, Espinosa-Parrilla Y, Goulet O, Al-Qabandi W, Guigue P, Canioni D, et al. A founder effect at the EPCAM locus in Congenital Tufting Enteropathy in the Arabic Gulf. *Eur J Med Genet* 2011;54:319-22.
[PUBMED](#) | [CROSSREF](#)
25. Salomon J, Goulet O, Canioni D, Brousse N, Lemale J, Tounian P, et al. Genetic characterization of congenital tufting enteropathy: epcam associated phenotype and involvement of SPINT2 in the syndromic form. *Hum Genet* 2014;133:299-310.
[PUBMED](#) | [CROSSREF](#)
26. Shakhnovich V, Dinwiddie D, Hildreth A, Attard T, Kingsmore S. A novel compound-heterozygous epithelial cell adhesion molecule mutation in tufting enteropathy. *J Pediatr Gastroenterol Nutr* 2017;64:e14-6.
[PUBMED](#) | [CROSSREF](#)
27. Sivagnanam M, Janecke AR, Müller T, Heinz-Erian P, Taylor S, Bird LM. Case of syndromic tufting enteropathy harbors SPINT2 mutation seen in congenital sodium diarrhea. *Clin Dysmorphol* 2010;19:48.
[PUBMED](#) | [CROSSREF](#)
28. Tan QK, Cardona DM, Rehder CW, McDonald MT. Identification of *EPCAM* mutation: clinical use of microarray. *Clin Case Rep* 2017;5:980-5.
[PUBMED](#) | [CROSSREF](#)
29. Thoeni C, Amir A, Guo C, Zhang S, Avitzur Y, Heng YM, et al. A novel nonsense mutation in the EpCAM gene in a patient with congenital tufting enteropathy. *J Pediatr Gastroenterol Nutr* 2014;58:18-21.
[PUBMED](#) | [CROSSREF](#)
30. Yan W, Xiao Y, Zhang Y, Tao Y, Cao Y, Liu K, et al. Monogenic mutations in four cases of neonatal-onset watery diarrhea and a mutation review in East Asia. *Orphanet J Rare Dis* 2021;16:383.
[PUBMED](#) | [CROSSREF](#)
31. Zhou YQ, Wu GS, Kong YM, Zhang XY, Wang CL. New mutation in *EPCAM* for congenital tufting enteropathy: a case report. *World J Clin Cases* 2020;8:4975-80.
[PUBMED](#) | [CROSSREF](#)
32. Pêgas KL, Cambuzzi E, Ferrelli RS, da Silva CS, Guedes RR, Adami M, et al. Tufting enteropathy with EpCAM mutation: case report. *J Bras Patol Med Lab* 2014;50:234-7.
[CROSSREF](#)
33. Yuan C, Wu J. Congenital tufting enteropathy caused by mutation of EPCAM gene: a case report and review of literature. Paper presented at: 57th Annual ESPE; 2018 Sep 27-29; Athens, Greece.
34. Lemale J, Coulomb A, Dubern B, Boudjemaa S, Viola S, Josset P, et al. Intractable diarrhea with tufting enteropathy: a favorable outcome is possible. *J Pediatr Gastroenterol Nutr* 2011;52:734-9.
[PUBMED](#) | [CROSSREF](#)
35. Schnell U, Cirulli V, Giepmans BN. EpCAM: structure and function in health and disease. *Biochim Biophys Acta* 2013;1828:1989-2001.
[PUBMED](#) | [CROSSREF](#)
36. Cai C, Chen Y, Chen X, Ji F. Tufting enteropathy: a review of clinical and histological presentation, etiology, management, and outcome. *Gastroenterol Res Pract* 2020;2020:5608069.
[PUBMED](#) | [CROSSREF](#)