



A Review of Recent Evidence on Trigeminal Neuralgia

Mee-Eun Kim | Hye-Kyoung Kim

Department of Orofacial Pain and Oral Medicine, College of Dentistry, Dankook University, Cheonan, Korea

Received December 7, 2022
Revised January 10, 2023
Accepted January 11, 2023

Correspondence to:

Hye-Kyoung Kim
Department of Orofacial Pain and Oral
Medicine, College of Dentistry, Dankook
University, 119 Dandae-ro, Dongnam-gu,
Cheonan 31116, Korea
E-mail: dent5991@gmail.com
<https://orcid.org/0000-0002-0734-5533>

This review aimed to update our knowledge of the classification, pathophysiology, prognosis, and treatment of trigeminal neuralgia (TN), with the intention of establishing better treatment protocols. The latest version of the International Classification of Headache Disorders uses an etiology-based approach to characterize TN patients, potentially contributing to the development of targeted treatment measures. Noticeable changes in the recent European Academy of Neurology guidelines for the management of TN include the use of magnetic resonance imaging for exclusion of secondary TN and differentiation of idiopathic and classical TN. Additionally, the use of botulinum toxin type A as an add-on therapy for mid-term treatment of TN has also been included. Though there has been limited recent progress in the treatment of TN, previous studies emphasize the importance of customized, multidisciplinary management protocols that include drug therapy optimization; provision of continuous education and support; and timely referral of medically refractory patients for surgery in order to achieve favorable prognosis. Furthermore, slow but growing evidence on gene mutations will help elucidate the pathophysiology of TN and contribute to the development of targeted drugs that are effective and safe.

Keywords: Classification; Pathology; Prognosis; Therapeutics; Trigeminal neuralgia

INTRODUCTION

Trigeminal neuralgia (TN), a rare condition arising from the orofacial region, presents as a sudden, unilateral, brief but severe, stabbing pain that is often recurrent and occurs along one or more branches of the fifth cranial nerve [1]. The pain typically lasts for less than 2 minutes and can occur spontaneously or in response to innocuous sensory stimuli or slight movements [2]. Although TN has a typical clinical phenotype due to its characteristic features, clinicians may encounter considerable diversity in presenting symptoms with some patients exhibiting continuous or near continuous pain and others reporting lacrimation during pain paroxysms [3]. Longer durations of pain may also be observed and these variations in the symptoms of TN can

cause confusion and delay diagnosis considerably, preventing early intervention. Undiagnosed and uncontrolled TN pain can profoundly affect the psychological and functional aspects of a patient's life, with many reporting pain disability, anxiety, depression, and impaired quality of life [4-6].

The International Classification of Headache Disorders (ICHD-3) version 3, published in 2018 by the International Headache Society in consensus with the International Association for the Study of Pain (IASP), proposes a new etiological method of classification wherein TN is grouped into *idiopathic*, *classical*, and *secondary* [7]. Accurate diagnosis and management of TN requires multispecialty involvement, highlighting the need for a clear classification system and comprehensive treatment guidelines based on scientific evidence. In accordance with this, the European

Academy of Neurology (EAN) developed clinical guidelines for the management of TN in 2019 [8], and comparison of this with the previous version published in 2008 as a collaboration between the EAN and the American Academy of Neurology (AAN) [9] showed noticeable differences in the classification system and imaging (magnetic resonance imaging, MRI) examinations uses and minimal changes in the management protocols themselves [8]. However, a recent study examining treatment utilization patterns in TN patients in the United States reported observing frequent switching of treatment measures and widespread use of polypharmacy including opioids, suggesting poor efficacy and tolerability of currently available pharmacological treatment protocols [10].

The etiology, pathophysiology, diagnosis, and prognosis of TN has been extensively examined over the past decade [11], with more recent studies also focusing on gene mutations and familial incidence of the same [12-14]. These genetic studies have largely focused on genes coding voltage-dependent ion channels as sodium channel blockers represent an effective treatment measure for TN [12,13].

The current review of recent evidence aims to update our knowledge of the diagnosis, pathophysiology, prognosis, and treatment of TN with the intention of establishing better strategies for the management of TN.

CLASSIFICATION OF TN

Table 1 shows changes in the ICHD classification of TN over the last two decades [7,15,16]. ICHD-2, published in 2004 [15], divided TN into the classical and symptomatic types. The former included cases caused by neurovascular compression (NVC), a common identifiable cause of TN frequently observed through MRI or during surgical procedures [2,17], as well as those without any identifiable etiology, while the latter including patients exhibiting other demonstrable structural lesions (i.e., space-occupying lesions [e.g., a tumor of the cerebellopontine angle] or multiple sclerosis) [7,15]. However, inclusion of cases without any identifiable etiology as well as those occurring secondary to NVC in the classical TN group [2] considerably affected accurate identification of clinical features and the consequent treatment response and prognosis. In particular, the inability to distinguish between the two types of classical TN delayed accurate diagnosis of TN occurring secondary to NVC and negatively impacted treatment outcomes.

The ICHD-3 beta (2013) [16] replaced symptomatic TN with a painful trigeminal neuropathy group to describe head and/or facial pain along the trigeminal nerve caused by other disorders indicative of neuronal damage (e.g., herpes zoster, trauma, space-occupying lesions, multiple sclerosis, etc.). Symptomatic TN included three subtypes based on etiology (i.e., space-occupying lesions, MS, and other disorders) and its diagnostic criteria included pain along

Table 1. Comparison of the ICHD classification of trigeminal neuralgia

ICHD-2 (2004) [15]	ICHD-3.0 beta (2013) [16]	ICHD-3.0 (2018) [7]
Classical TN	Classical TN -TN with purely paroxysmal pain -TN with concomitant persistent pain (Previously termed as atypical TN; TN type 2)	Classical TN -TN with purely paroxysmal pain -TN with concomitant continuous pain
Symptomatic TN: Pain indistinguishable from classical TN and caused by a demonstrable structural lesion other than vascular compression	Painful trigeminal neuropathy (Symptomatic TN) -Painful trigeminal neuropathy attributed to multiple sclerosis -Painful trigeminal neuropathy attributed to space-occupying lesions -Painful trigeminal neuropathy attributed to other disorders	Secondary TN -TN attributed to multiple sclerosis -TN attributed to space-occupying lesions -TN attributed to other causes
		Idiopathic TN -TN with purely paroxysmal pain -TN with concomitant continuous pain

ICHD, The International Classification of Headache Disorders; TN, trigeminal neuralgia.

with the characteristics of classical TN [16].

The latest version of the ICHD [7] changed this into secondary TN, thus providing appropriate clarification of terminology and sub-classification. Importantly, the ICHD-3 differentiated idiopathic TN from classical TN, with the latter referring to cases exhibiting morphological changes (e.g., displacement, indentation, atrophy, etc.) in the trigeminal nerve root and no obvious etiology other than vascular compression (not simply contact) [18] and the former including TN with no apparent cause (i.e., no neurovascular contact or neurovascular contact without morphological changes of the trigeminal root) [7]. However, demonstration of NVC should not be used to confirm diagnosis as evidence suggests that idiopathic TN is moderately associated with NVC without morphological changes (a frequent variation of normal anatomy observed on the asymptomatic side during MRI examination or surgery) [8,17] while classical TN is highly associated with NVC with morphological changes [8].

Idiopathic and classical TN can be divided into two further subtypes, purely paroxysmal TN and TN with concomitant continuous pain [7].

MRI INVESTIGATION

Exclusion of secondary TN when establishing the type of lesion is essential; however, the lack of specific clinical features distinguishing it from the other types necessitates the use of MRI examination for this purpose [2,3,8]. EAN recommends the use of standard MRI for the exclusion of secondary TN as it exhibits good high sensitivity when detecting major neurological diseases (e.g., tumor, MS, etc.) [8]. The introduction of idiopathic TN in the new ICHD-3 classification system also emphasizes the importance of identifying vascular compression with morphological changes such as atrophy, indentation, or displacement of the trigeminal nerve root. Advanced MRI techniques are recommended for this purpose as three-dimensional T2-weighted MRIs provide excellent contrast between cerebrospinal fluid and neurovascular structures [19]; three-dimensional time-of-flight MR angiographies allow good visualization of arteries; and three-dimensional T1-weighted gadolinium is effective for the evaluation of nerves [2,8]. During MRI investigation, it is essential that the neuroradiologist is blinded

to the symptomatic side to minimize the risk of bias during evaluation of NVC [8].

Recently, diffusion-tensor imaging has also been used to evaluate disruptions in the micro-structure caused by demyelination or demyelination of the trigeminal nerve [20].

PATHOPHYSIOLOGY OF TN

The largely unclear complex pathophysiology of TN includes both peripheral and central mechanisms [12,14,21]. The peripheral mechanism includes focal demyelination caused by an NVC at the trigeminal nerve root close to the brainstem (root entry zone) that lowers the excitability threshold of the affected fibers and promotes ephaptic exchange of neural signals at the site of neuropathy [2,20,22,23]. Neuronal hyper-excitability may also occur in 2nd order neurons in the trigeminal brainstem sensory nuclei and 3rd order neurons in the thalamus projecting to the cortical gray matter, leading to diminished gamma-aminobutyric acid-mediated inhibition [24]. Some neuroimaging studies also report observing alterations in gray matter volume and connectivity in TN patients [25].

The role of epigenetic factors has also been highlighted by several experimental studies, with one reporting observation of peripheral inflammation-altered DNA methylation in rat trigeminal ganglia and consequent abnormal expression of pro-nociceptive genes [14]. Bai et al. [26] suggested that trigeminal ganglia pro-nociceptive genes may be subject to epigenetic modulation via DNA methylation that regulates genes.

Evidence on the role of genetic factors in TN has increased recently. Although familial TN has been considered to be relatively rare, with prevalence rates ranging between 1%-2% [12,13], more recent evidence suggests that it may occur more frequently than previously assumed [12-14,27]. Eide PK [14] reported observing familial TN in 41 out of 268 (15.2%) Norwegian patients with idiopathic or classical TN. Gene mutations and voltage-gated ion channels, particularly sodium channels, have been examined by various human and experimental animal studies as sodium channel blockers are effective in TN patients [12,13]. Important candidate genes in human studies include those coding for sodium channels, calcium channels, and serotonin

transporters [12,14]. Some studies identified dysfunctional NaV1.3, NaV1.6, NaV1.7, and NaV1.8 [12], while other experimental animal studies tried to find mutational genes coding for sodium channels, calcium channels, TRP channels, purinoceptors, and tachykinin proteins [12]. Some of the genes identified in these animal studies coincided with those reported by human studies [12].

Though such evidence is still limited and the experimental pain models used in animal studies are closer to neuropathic trigeminal pain models [12], growing evidence on gene variants suggest that genetic factors have a more important role in the pathophysiology of TN than previously considered [12-14]. Existing evidence also suggests that neuronal hyper-excitability due to mutations in voltage-gated ion channels may render the trigeminal nerve more sensitive to vascular compression [14].

PROGNOSIS OF TN

There is a dearth of reliable longitudinal evidence on the prognosis of TN [22], with patients often experiencing unpredictable periods of complete remission lasting a few weeks to several years [2,22]. However, in most cases, remission lasts for a few months only [28,29], although this is relatively uncommon in neuropathic pain possibly due to reduced excitability and partial remyelination [29]. However, a recent epidemiological study found that these periods of remission tend to get shorter and the relapse rate increases over time [30]. Although the underlying pathophysiology of these recurrence patterns remains unclear, neuroinflammation of the affective nerve and central sensitization may have a potential role.

To date, TN has been considered a progressive disease with poor prognosis over time [7], with patients with a long history of the disease experiencing prolonged medically refractory pain; sensory disturbances; and progressive neuroanatomical changes of the trigeminal nerve root [22,31]. However, this traditional notion has been contradicted by more recent evidence, with a retrospective study of 200 patients with classical TN reporting no deterioration in the frequency/duration of pain over time and an absence of delayed development of drug resistance in the majority of patients [32]. Maarbjerg et al. [33], also found that age and the

duration of disease were not related to concomitant continuous pain and neuroanatomical morphological changes.

Heinskou et al. [34], in their prospective study over 2 years, emphasized the importance of multidisciplinary management (including optimization of drug therapy; provision of continuous advice, education, and support; and referral of medically intractable patients for surgery) for favorable prognosis in TN patients.

Although there are a limited number of studies examining prognosis in TN patients, the results may indicate more positive insight on TN management when early and accurate diagnosis and well-structured, customized management program is provided.

MANAGEMENT OF TN

The new etiological classification of TN suggests that treatment protocols should vary between the subtypes [3]. Secondary TN caused by space-occupying lesions require pathology-specific treatment measures such as surgery, oncological treatment, etc. [3], and referral of such patients to neurologists or neurosurgeons for further evaluation and appropriate management is recommended. In patients with classical or idiopathic TN, pharmacotherapy should be considered first [2,3,8], and if unsuccessful, neurosurgical options such as microvascular decompression (MVD) of the vessel-nerve contact, neuroablative treatments such as gamma knife surgery (GKS), and ganglion level surgery (e.g., radiofrequency thermocoagulation, balloon compression, and glycerol rhizolysis) should be offered [2,3,8,11]. MVD can be offered as the first line of surgical treatment in patients with classical TN caused by vascular compression of the trigeminal nerve at the root entry zone. Neuroablative procedures including GKS or ganglion level surgery may be considered otherwise, with the latter being particularly appropriate in patients with idiopathic TN [3,8].

Figure 1 shows the etiology-based treatment algorithm for TN.

1. Pharmacological Treatment

Based on current evidence, the new EAN guidelines for TN management strongly recommends the use of carbamazepine (CBZ; 200-1,200 mg/day) or oxcarbazepine (OXC;

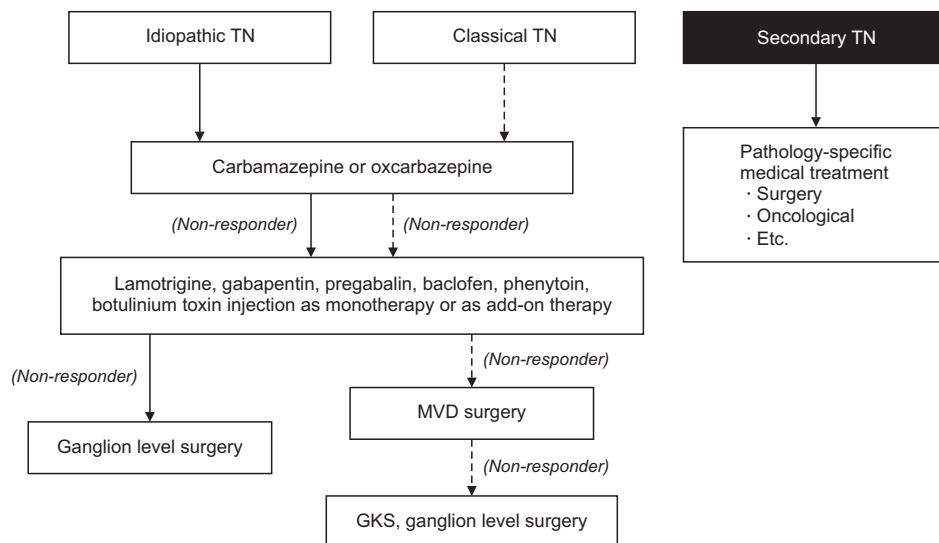


Fig. 1. Etiology-based treatment algorithm for trigeminal neuralgia. TN, trigeminal neuralgia; MVD, microvascular decompression; GKS, gamma-knife surgery.

300-1,800 mg/day) as the first line drug for the long-term treatment of TN [8]. While the use of CBZ is supported by evidence of a moderate quality, OXC is suggested based on evidence of a very poor quality but with a high degree of clinical confidence in its efficacy [8]. By blocking voltage-dependent sodium channels, CBZ reduces the frequency and intensity of paroxysmal pain as well as spontaneous and evoked pain [35]. However, it also has a variety of side effects including ataxia, drowsiness, and fatigue. Other more idiosyncratic side effects of CBZ include leukopenia, agranulocytosis, and aplastic anemia [36], and discontinuation of its use can most commonly be attributed to its side effects rather than drug inefficacy [32]. OXC, a keto-analog of CBZ, exhibits similar mechanisms of action and effects, although better tolerability and fewer drug interactions and adverse effects make it the drug of choice for TN [2,36]. However, a common side effect of OXC is hyponatremia [32].

The EAN guidelines recommend the use of lamotrigine, gabapentin, botulinum toxin type A, pregabalin, baclofen, and phenytoin as mono-/add-on therapies when CBZ and OXC prove unsuccessful, although this is largely based on low to very low quality of supporting evidence [8]. Notably, subcutaneous injection of botulinum toxin type A to trigger areas has been included as a treatment option in the new EAN guideline [8]. The resultant pain relief may last several months, with the main side effect being transient weakness in the facial muscles of the injected area [37]. A previous study found that the effects of an injection of 20-50 units

of botulinum toxin into the trigger zone appeared after 1-2 weeks [3]. Weak recommendation was given as add-on therapy for medium-term treatment of TN and more data is still required [8,37].

2. Surgical Treatment

Surgical interventions may be considered if pharmacological treatment measures prove unsuccessful due to insufficient effects or poor tolerability [8]. The optimal time for offering surgery and selection of surgical option are the two key considerations for surgical treatment of both classical and idiopathic TN to achieve prolonged pain relief and minimal side effects [8].

1) Optimal timing for surgical intervention

Pharmacotherapy with adequate dosage and regular monitoring should be the first line of treatment in patients with idiopathic or classical TN, although there is no evidence on the number of drug trials necessary prior to recommendation of surgery [3,8]. Selection of inappropriate drugs, inadequate titration, and negligent monitoring may increase the risk of poor tolerability, potentially leading to unsuccessful pharmacological treatment and early surgical intervention [10].

However, if medication is unsuccessful due to insufficient effects or poor tolerability, surgery should be recommended [8]. One study of 250 MVD cases found that performance of the procedure within 7 years of classical TN onset resulted

in superior treatment outcomes [38], while others found that some patients would have opted for surgery sooner [39,40]. Therefore, TN patients should be informed of the possibility of surgery at an early stage [8], and sufficient explanation of the potential complications and alternative procedures should also be provided [3]. The patient's age and physical status should be evaluated thoroughly prior to recommending surgery, especially in cases requiring general anesthesia (e.g., MVD surgery) [3].

2) Selection of surgical technique

Surgical options for classical and idiopathic TN include peripheral procedures at the affected branch (e.g., nerve block with local anesthetics, alcohol, or glycerol, neurectomy, and cryosurgery) and central procedures (e.g., MVD, GKS, and ganglion level surgery) at the trigeminal ganglion or the nerve root [2,3]. However, peripheral procedures are typically associated with shorter durations of pain relief and higher recurrence and complication rates [3].

The EAN guideline strongly recommends MVD over GKS in patients with classical TN [8]. Despite the low or very low quality of supporting data, all published studies consistently demonstrated superiority of MVD over GKS in the medium and long-term [8]. Pooled analyses of outcomes from single intervention trials also showed that 62%–89% (N=5,149) of patients were pain free 3–11 years after MVD while 30%–66% of patients were pain free 4–11 years after GKS. Additionally, 55%–80% of patients were pain-free 4–11 years after balloon compression, and the corresponding values after radiofrequency thermocoagulation and glycerol injection were 26%–82% and 19%–58%, respectively [8]. There is limited recent evidence suggesting that MVD may also be more effective in pain relief compared to other ablative procedures (weak recommendation in the EAN guideline) [8]. Neuroablative surgery may be considered in the absence of an NVC, although whether it is preferred over MVD is still unclear due to limited supporting evidence and large differences in the success rates [2,3,8,11].

The post-operative complications of MVD, a posterior fossa surgery, include mortality (0.3%); rare but serious problems such as cerebrospinal fluid leakage (1.9%), stroke (0.6%), anesthesia dolorosa (0.02%), and meningitis (0.4%) [8]; and more common but less serious conditions such as

facial hypoesthesia (2.9%), cranial nerve palsy (4%) and hearing loss (1.9%) [8]. The most frequently reported complications of neuroablative procedures include facial hypoesthesia (19%), corneal hypoesthesia (5%), and trigeminal motor weakness (5%) [8,11], while GKS exhibits lower rates of complications such as facial hypoesthesia. However, evidence suggests that better long-term outcomes can be achieved with higher dosage, increasing the risk of sensory loss [8,41].

CONCLUSION

The newest ICHD etiological classification of TN can potentially be useful for the characterization of TN patients, leading to development of etiology-specific treatment measures. Noticeable changes in the recent EAN guidelines for the management of TN include the usage of MRI for exclusion of secondary TN and differentiation of idiopathic and classical TN. Additionally, the use of botulinum toxin type A as an add-on therapy for mid-term treatment of TN has also been included. Though there has been limited recent progress in the treatment of TN, current studies emphasize the importance of customized, multidisciplinary management protocols that include drug therapy optimization; provision of continuous education and support; and timely referral of medically refractory patients for surgery in order to achieve favorable prognosis. Furthermore, slow but growing evidence on gene mutations will help elucidate the pathophysiology of TN and contribute to the development of targeted drugs that are effective and safe.

CONFLICT OF INTEREST

Mee-Eun Kim serves on the editorial board of the *Journal of Oral Medicine and Pain*. Hye-Kyoung Kim has been the Editor-in-Chief of the *Journal of Oral Medicine and Pain* since April 1, 2022. But they have no role in the decision to publish this article. Except for that, no potential conflict of interest relevant to this article was reported.

FUNDING

None.

AUTHOR CONTRIBUTIONS

Conceptualization: MEK, HKK. Writing original draft & visualization: MEK. Writing review & editing: MEK, HKK.

REFERENCES

- Merskey H, Bogduk N. Classification of chronic pain: descriptions of chronic pain syndromes and definitions of pain terms. Seattle: IASP Press; 1994.
- Cruccu G. Trigeminal neuralgia. *Continuum* 2017;23:396-420.
- Maarbjerg S, Benoliel R. The changing face of trigeminal neuralgia: a narrative review. *Headache* 2021;61:817-837.
- Zakrzewska JM, Wu J, Mon-Williams M, Phillips N, Pavitt SH. Evaluating the impact of trigeminal neuralgia. *Pain* 2017;158:1166-1174.
- Tölle T, Dukes E, Sadosky A. Patient burden of trigeminal neuralgia: results from a cross-sectional survey of health state impairment and treatment patterns in six European countries. *Pain Pract* 2006;6:153-160.
- Melek LN, Devine M, Renton T. The psychosocial impact of orofacial pain in trigeminal neuralgia patients: a systematic review. *Int J Oral Maxillofac Surg* 2018;47:869-878.
- Headache Classification Committee of the International Headache Society (IHS). The international classification of headache disorders, 3rd edition. *Cephalalgia* 2018;38:1-211.
- Bendtsen L, Zakrzewska JM, Abbott J, et al. European Academy of Neurology guideline on trigeminal neuralgia. *Eur J Neurol* 2019;26:831-849.
- Cruccu G, Gronseth G, Alksne J, et al. AAN-EFNS guidelines on trigeminal neuralgia management. *Eur J Neurol* 2008;15:1013-1028.
- Zakrzewska JM, Wu N, Lee JYK, Werneburg B, Hoffman D, Liu Y. Characterizing treatment utilization patterns for trigeminal neuralgia in the United States. *Clin J Pain* 2018;34:691-699.
- Bendtsen L, Zakrzewska JM, Heinskou TB, et al. Advances in diagnosis, classification, pathophysiology, and management of trigeminal neuralgia. *Lancet Neurol* 2020;19:784-796.
- Mannerak MA, Lashkarivand A, Eide PK. Trigeminal neuralgia and genetics: a systematic review. *Mol Pain* 2021;17:17448069211016139.
- Di Stefano G, Yuan JH, Cruccu G, Waxman SG, Dib-Hajj SD, Truini A. Familial trigeminal neuralgia: a systematic clinical study with a genomic screen of the neuronal electrogenisome. *Cephalalgia* 2020;40:767-777.
- Eide PK. Familial occurrence of classical and idiopathic trigeminal neuralgia. *J Neurol Sci* 2022;434:120101.
- Headache Classification Subcommittee of the International Headache Society (IHS). The international classification of headache disorders: 2nd edition. *Cephalalgia* 2004;24 Suppl 1:9-160.
- Headache Classification Committee of the International Headache Society (IHS). The international classification of headache disorders, 3rd edition (beta version). *Cephalalgia* 2013;33:629-808.
- Antonini G, Di Pasquale A, Cruccu G, et al. Magnetic resonance imaging contribution for diagnosing symptomatic neurovascular contact in classical trigeminal neuralgia: a blinded case-control study and meta-analysis. *Pain* 2014;155:1464-1471.
- Cruccu G, Finnerup NB, Jensen TS, et al. Trigeminal neuralgia: new classification and diagnostic grading for practice and research. *Neurology* 2016;87:220-228.
- Leal PR, Hermier M, Souza MA, Cristino-Filho G, Froment JC, Sindou M. Visualization of vascular compression of the trigeminal nerve with high-resolution 3T MRI: a prospective study comparing preoperative imaging analysis to surgical findings in 40 consecutive patients who underwent microvascular decompression for trigeminal neuralgia. *Neurosurgery* 2011;69:15-25; discussion 26.
- Lutz J, Thon N, Stahl R, et al. Microstructural alterations in trigeminal neuralgia determined by diffusion tensor imaging are independent of symptom duration, severity, and type of neurovascular conflict. *J Neurosurg* 2016;124:823-830.
- Love S, Coakham HB. Trigeminal neuralgia: pathology and pathogenesis. *Brain* 2001;124(Pt 12):2347-2360. Erratum in: *Brain* 2002;125(Pt 3):687.
- Maarbjerg S, Di Stefano G, Bendtsen L, Cruccu G. Trigeminal neuralgia - diagnosis and treatment. *Cephalalgia* 2017;37:648-657.
- Obermann M, Yoon MS, Ese D, et al. Impaired trigeminal nociceptive processing in patients with trigeminal neuralgia. *Neurology* 2007;69:835-841.
- Dong W, Jin SC, Allocco A, et al. Exome sequencing implicates impaired GABA signaling and neuronal ion transport in trigeminal neuralgia. *iScience* 2020;23:101552.
- Gambeta E, Chichorro JG, Zamponi GW. Trigeminal neuralgia: an overview from pathophysiology to pharmacological treatments. *Mol Pain* 2020;16:1744806920901890.
- Bai G, Ross H, Zhang Y, Lee K, Ro JY. The role of DNA methylation in transcriptional regulation of pro-nociceptive genes in rat trigeminal ganglia. *Epigenet Insights* 2020;13:2516865720938677.
- Panchagnula S, Sularz AK, Kahle KT. Familial trigeminal neuralgia cases implicate genetic factors in disease pathogenesis. *JAMA Neurol* 2019;76:9-10.
- Maarbjerg S, Gozalov A, Olesen J, Bendtsen L. Concomitant persistent pain in classical trigeminal neuralgia--evidence for different subtypes. *Headache* 2014;54:1173-1183.
- Devor M, Amir R, Rappaport ZH. Pathophysiology of trigeminal neuralgia: the ignition hypothesis. *Clin J Pain* 2002;18:4-13.
- Zakrzewska JM. Assessment and treatment of trigeminal neuralgia. *Br J Hosp Med (Lond)* 2010;71:490-494.
- Burchiel KJ, Slavin KV. On the natural history of trigeminal neuralgia. *Neurosurgery* 2000;46:152-154; discussion 154-155.
- Di Stefano G, La Cesa S, Truini A, Cruccu G. Natural history and outcome of 200 outpatients with classical trigeminal neuralgia treated with carbamazepine or oxcarbazepine in a tertiary centre for neuropathic pain. *J Headache Pain* 2014;15:34.
- Maarbjerg S, Wolfram F, Gozalov A, Olesen J, Bendtsen L. Association between neurovascular contact and clinical characteristics in classical trigeminal neuralgia: a prospective clinical study us-

- ing 3.0 Tesla MRI. *Cephalalgia* 2015;35:1077-1084.
34. Heinskou TB, Maarbjerg S, Wolfram F, et al. Favourable prognosis of trigeminal neuralgia when enrolled in a multidisciplinary management program: a two-year prospective real-life study. *J Headache Pain* 2019;20:23.
 35. Oomens MA, Forouzanfar T. Pharmaceutical management of trigeminal neuralgia in the elderly. *Drugs Aging* 2015;32:717-726.
 36. Okeson JP. *Bell's oral and facial pain*. 7th ed. Chicago: Quintessence Publishing Co.; 2014. pp. 438-452.
 37. Morra ME, Elgebaly A, Elmaraezy A, et al. Therapeutic efficacy and safety of botulinum toxin A therapy in trigeminal neuralgia: a systematic review and meta-analysis of randomized controlled trials. *J Headache Pain* 2016;17:63.
 38. Broggi G, Ferroli P, Franzini A, Servello D, Dones I. Microvascular decompression for trigeminal neuralgia: comments on a series of 250 cases, including 10 patients with multiple sclerosis. *J Neurol Neurosurg Psychiatry* 2000;68:59-64.
 39. Spatz AL, Zakrzewska JM, Kay EJ. Decision analysis of medical and surgical treatments for trigeminal neuralgia: how patient evaluations of benefits and risks affect the utility of treatment decisions. *Pain* 2007;131:302-310.
 40. Zakrzewska JM, Lopez BC, Kim SE, Varian EA, Coakham HB. Patient satisfaction after surgery for trigeminal neuralgia--development of a questionnaire. *Acta Neurochir (Wien)* 2005;147:925-932.
 41. Young B, Shivazad A, Kryscio RJ, St Clair W, Bush HM. Long-term outcome of high-dose γ knife surgery in treatment of trigeminal neuralgia. *J Neurosurg* 2013;119:1166-1175.