

세포교정영양요법(OCNT)을 이용한 자궁선근증 환자 사례 연구

김정명 약사

경기도 화성시 동탄대로시범길 146 열린온누리약국

A Case Study of a Patient with Adenomyosis Using Ortho-Cellular Nutrition Therapy (OCNT)

Pharmacist Jeong-myeong Kim

Yeollinon-nuri Pharmacy, 146, Dongtan-daero Sibum-gil, Hwaseong-si, Gyeonggi-do, South Korea

ABSTRACT

Objective: A case report on the improvement of adenomyosis using cell correction nutritional therapy.**Methods:** A 39-year-old Korean woman who experienced severe dysmenorrhea after childbirth and had elevated levels of cancer antigen 125 (CA-125) during recent regular check-up.**Results:** Application of nutritional therapy resulted in relief of dysmenorrhea, elimination of oxidized blood, and reduction in CA-125 levels.**Conclusion:** Nutritional therapy can be helpful in alleviating symptoms and assisting in the treatment of patients with adenomyosis.**Keywords** Ortho-Cellular Nutrition Therapy (OCNT), dysmenorrhea, irregular uterine bleeding, adenomyosis

Introduction

Adenomyosis, also known as heterotopic endometriosis, is a condition characterized by the presence of endometrial glands and stroma within the muscular layer of the uterus, leading to the proliferation of surrounding smooth muscle.¹ Adenomyosis is a

condition that commonly occurs in women aged 35-50 and is characterized by chronic pelvic pain. It is also associated with symptoms such as heavy menstrual bleeding (40-50%), dysmenorrhea (15-30%), and abnormal uterine bleeding (10-12%). Menstrual pain can be classified into primary dysmenorrhea and secondary dysmenorrhea.² Primary dysmenorrhea refers to menstrual pain that occurs without any underlying secondary causes. It is associated with the menstrual cycle and is caused by contractions of the uterine muscles. On the other hand, secondary dysmenorrhea is menstrual pain that is related to abnormalities in pelvic organs. It is often associated with conditions such as endometriosis, adenomyosis, uterine fibroids, and pelvic inflammatory disease. Furthermore, conditions such as endometriosis, adenomyosis, uterine fibroids, and

*Correspondence: Jeong-myeong Kim

E-mail: dtopkjm@naver.com

Received May 31, 2023; Accepted May 31, 2023; Published May 31, 2023

doi: <http://dx.doi.org/10.5667/CellMed.spc.024>

©2023 by CellMed Orthocellular Medicine Pharmaceutical Association

This is an open access article under the CC BY-NC license.

<http://creativecommons.org/licenses/by-nc/3.0/>

† This report has been translated and edited by the CellMed editor-in-chief, Prof. Beom-Jin Lee.

endometrial cancer can also cause abnormal uterine bleeding.³ Cancer antigen (CA)-125 is used as a marker for ovarian cancer in diseases involving membrane structures such as adenomyosis.⁴ CA-125 is a tumor-associated antigen that is a high-molecular-weight glycoprotein produced not only by ovarian cancer cells but also by normal cells. It can be elevated in pancreatic cancer, lung cancer, breast cancer, colorectal cancer, and gastrointestinal cancer, but its utility as a screening test is not recognized. The patient in this case was diagnosed with adenomyosis 12 years ago. After giving birth in 2017, she began to experience severe menstrual pain and abnormal uterine bleeding. Recently, she underwent significant stress and showed elevated CA-125 levels during a routine check-up, requiring management. Therefore, the application of nutritional therapy was initiated, and the progress is reported here.

Case Study

1. Subject

The study targeted one case of adenomyosis in a patient.

- 1) Name: O O O (F/39 years old)
- 2) Diagnosis: Adenomyosis
- 3) Date of occurrence: 2011
- 4) Treatment period: From March 2, 2023
- 5) Main symptoms: dysmenorrhea, irregular bleeding
- 6) Past history: none
- 7) Social history: Alcohol consumption twice a week
- 8) Family history: None
- 9) Medical history: Usually has severe menstrual cramps, so takes painkillers.

2. Method

Cyaplex F Capsules (303, twice a day, 3 capsules per day)
Eufaplex Alpha Capsules (303, twice a day, 3 capsules per day)
Angelan (101, twice a day, 1 packet per day)
Selenase Capsules (101, twice a day, 1 capsule per day)

The patient took the treatment for 2 months following the method above.

Additionally, the patient showed symptoms of constipation and started taking Bioplex-F (101, twice a day, 1 capsule per day).

Results

The patient in this case experienced symptoms

associated with adenomyosis, such as menstrual difficulties and abnormal uterine bleeding, following childbirth. In 2017, the patient underwent a Mirena procedure, which resolved the abnormal uterine bleeding. However, during the initial regular check-up, the CA-125 level was found to be elevated at 50.66, indicating a potential association with adenomyosis or possible ovarian cancer. After implementing nutritional therapy, one and a half months later, the CA-125 level improved to 45.8, although it did not reach the normal range (0-35), indicating a positive trend. Additionally, following the application of nutritional therapy, old tissues and blood trapped within the uterine muscle layer were expelled (Figure 1).

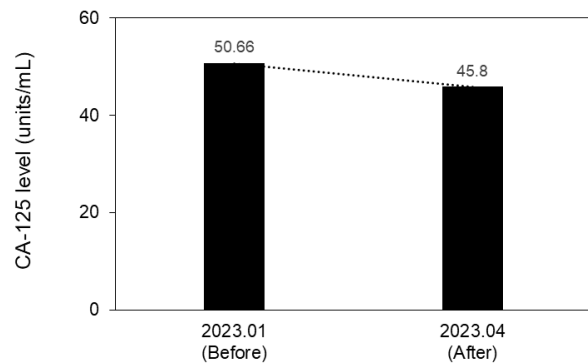


Figure 1. Changes in Cancer Antigen 125 (CA-125) Levels Over Time Following the Application of OCNT.

Discussion

Adenomyosis is a condition characterized by the presence of endometrial glandular tissue and stroma within the muscular layer of the uterus, leading to an enlargement of the uterus. The abnormally infiltrated endometrial tissue promotes the growth of surrounding uterine muscle layers, resembling the uterine enlargement seen during pregnancy. Macroscopically, adenomyosis is characterized by overall thickening of the uterine wall and is commonly found in a disproportionate and posterior distribution compared to the anterior wall. The exact cause of adenomyosis has not been fully elucidated. Two hypotheses regarding the etiology are proposed: the infiltration of endometrial tissue into the uterine muscle layer and the transformation of uterine muscle tissue into tissue resembling endometrial tissue.⁶ Adenomyosis is a condition where the endometrial tissue, including glands and stroma, abnormally grows within the muscular layer

of the uterus. It causes the accumulation of old tissue and blood within the uterine myometrium, resulting in increased size of the uterus during the menstrual cycle and menstrual bleeding. Quercetin, found in the black Cyaplex F Capsule, has been shown to inhibit the growth of ovarian cancer and endometrial cancer cells in in vitro studies.⁷

Furthermore, it has been demonstrated through animal experiments that Omega-3 interacts with Peroxisome proliferator-activated receptor (PPAR) to regulate the menstrual cycle. Therefore, the consumption of Omega-3 may have the potential to regulate the development of endometrial tissue.⁸

Angelin, EGCG has been shown to induce proliferation and apoptosis of ovarian cancer and endometrial cancer cells through in vivo and in vitro experiments.⁹

Chlorogenic acid, found in the Selenase Capsule, has been reported to be involved in anti-inflammatory responses by inhibiting the expression of TLR4 receptors in the TLR4/NF- κ B signaling pathway associated with inflammation in animal endometrial epithelial cells.¹⁰

This case report is based on a single patient, and although it has limitations in generalizing to other patients, it showed relatively rapid efficacy in relieving dysmenorrhea and reducing CA-125 levels. Additionally, it is a case where nutritional therapy was appropriately implemented to address discomfort caused by constipation through dietary fiber intake. Therefore, with the patient's consent, we report this case.

References

- 1 Lee, W. H. *et al.* Uterine artery embolization: the interventional treatment of female genital diseases. **76**, 1-9 (2017).
- 2 Osayande, A. S. & Mehulic, S. J. A. f. p. Diagnosis and initial management of dysmenorrhea. **89**, 341-346 (2014).
- 3 Wouk, N. & Helton, M. Abnormal Uterine Bleeding in Premenopausal Women. *Am Fam Physician* **99**, 435-443 (2019).
- 4 Ferenczy, A. Pathophysiology of adenomyosis. *Hum Reprod Update* **4**, 312-322, doi:10.1093/humupd/4.4.312 (1998).
- 5 Jung J-W, Y. Y.-J. The Effect of Herbal Medicine for Adenomyosis patients: A Systematic Review. *he Journal of Korean Obstetrics and Gynecology* **32**, 87-101, doi:10.15204/JKOBGY.2019.32.4.087 (2019).
- 6 Miralles, C. *et al.* Cancer antigen 125 associated with multiple benign and malignant pathologies. *Ann Surg Oncol* **10**, 150-154, doi:10.1245/aso.2003.05.015 (2003).
- 7 Scambia, G. *et al.* Inhibitory effect of quercetin on primary ovarian and endometrial cancers and synergistic activity with cis-diamminedichloroplatinum (II). *Gynecol Oncol* **45**, 13-19, doi:10.1016/0090-8258(92)90484-z (1992).
- 8 MacLaren, L. A., Guzeloglu, A., Michel, F. & Thatcher, W. W. Peroxisome proliferator-activated receptor (PPAR) expression in cultured bovine endometrial cells and response to omega-3 fatty acid, growth hormone and agonist stimulation in relation to series 2 prostaglandin production. *Domest Anim Endocrinol* **30**, 155-169, doi:10.1016/j.domaniend.2005.07.003 (2006).
- 9 Huang, Y. J., Wang, K. L., Chen, H. Y., Chiang, Y. F. & Hsia, S. M. Protective Effects of Epigallocatechin Gallate (EGCG) on Endometrial, Breast, and Ovarian Cancers. *Biomolecules* **10**, doi:10.3390/biom10111481 (2020).
- 10 Hu, X. *et al.* Anti-inflammatory Effect of Astragaloside and Chlorogenic Acid on Escherichia coli-Induced Inflammation of Sheep Endometrial Epithelium Cells. *Front Vet Sci* **7**, 201, doi:10.3389/fvets.2020.00201 (2020).
- 11 Morais, M. B., Vitolo, M. R., Aguirre, A. N. C. & Fagundes-Neto, U. Measurement of Low Dietary Fiber Intake As a Risk Factor for Chronic Constipation in Children. **29**, 132-135 (1999).