

Letter to the Editor : Classifying the Anatomical Location of the Ureter after Retroperitoneal Dissection

Su-Hun Lee,¹ Dong-Wuk Son,^{1,2} Jun-Seok Lee,^{1,2} Geun-Sung Song^{1,2}

Department of Neurosurgery,¹ Pusan National University Yangsan Hospital, Research Institute for Convergence of Biomedical Science and Technology, Pusan National University Yangsan Hospital, Yangsan, Korea

Department of Neurosurgery,² School of Medicine, Pusan National University, Yangsan, Korea

To the Editor,

With the growing favorable evidence of lateral lumbar interbody fusion (LLIF), the use of LLIF is increasing^{9,12,15}. Ureter injuries are a rare but serious complication of LLIF⁵, and some related case reports have been published^{1,6,7,10,16}. To prevent ureter injury, using preoperative computed tomography (CT) to evaluate the location of the ureter has also been recently reported³. Huang et al.⁴ recently published a study with a morphometric analysis of the ureter in *Journal of Korean Neurosurgical Society*, providing information on ureter position according to each level in a relatively large number of patients. Ouchida et al.¹¹ demonstrated the ureter location in the lateral decubitus position, and they proved that the ureter moves anteriorly compared to the supine position.

However, we should note that the LLIF procedure starts with retroperitoneal dissection to the psoas muscle. We then insert an electrode (extreme lumbar interbody fusion, XLIF) or dissect more anterior of the psoas muscle (oblique lateral interbody fusion, OLIF). This means that preoperative CT imaging alone cannot predict the real anatomy we find in LLIF surgery. Previous studies also suggested that ureteral injury

may be related to the limited exposure of the retroperitoneal space and blind maneuvering^{2,6,7,10,13}. In this letter, we aim to describe the three positions of the ureter that we can encounter after retroperitoneal dissection (Fig. 1A)¹⁴ : 1) above the psoas muscle (Fig. 1B) : the ureter is located inside the retroperitoneal fat, anterior to the psoas muscle, does not contact with the psoas muscle. It is easily retracted medially during retroperitoneal dissection. This location of ureter has a low risk of injury during XLIF and OLIF. The ureter is not visible unless the retroperitoneal fat is disrupted. 2) On the psoas muscle (Fig. 1C) : the ureter is in contact with the anterior border of psoas muscle, and it is easily visible and retracted medially during retroperitoneal dissection. If the retroperitoneal fat above the psoas muscle is not clearly swiped off, the XLIF procedure can be related to ureter injury. For the OLIF procedure, it has low risk of ureter injury because the retroperitoneal fat should be swiped off to the anterior border of psoas muscle. And 3) beside the psoas muscle (Fig. 1D) : the ureter is located at anterior margin of the psoas muscle, adjacent to disc space (or vertebral body) and, in some cases, under the psoas muscle. The ureter is attached to or slightly floats on the annulus. This location corresponds to II-v and

• Received : July 10, 2023 • Revised : July 17, 2023 • Accepted : August 1, 2023

• Address for correspondence : **Dong Wuk Son**

Department of Neurosurgery, Pusan National University Yangsan Hospital, 20 Geumo-ro, Mulgeum-eup, Yangsan 50612, Korea
Tel : +82-55-360-2126, Fax : +82-55-360-2156, E-mail : md6576@naver.com, ORCID : https://orcid.org/0000-0002-9154-1923

This is an Open Access article distributed under the terms of the Creative Commons Attribution Non-Commercial License (<http://creativecommons.org/licenses/by-nc/4.0>) which permits unrestricted non-commercial use, distribution, and reproduction in any medium, provided the original work is properly cited.

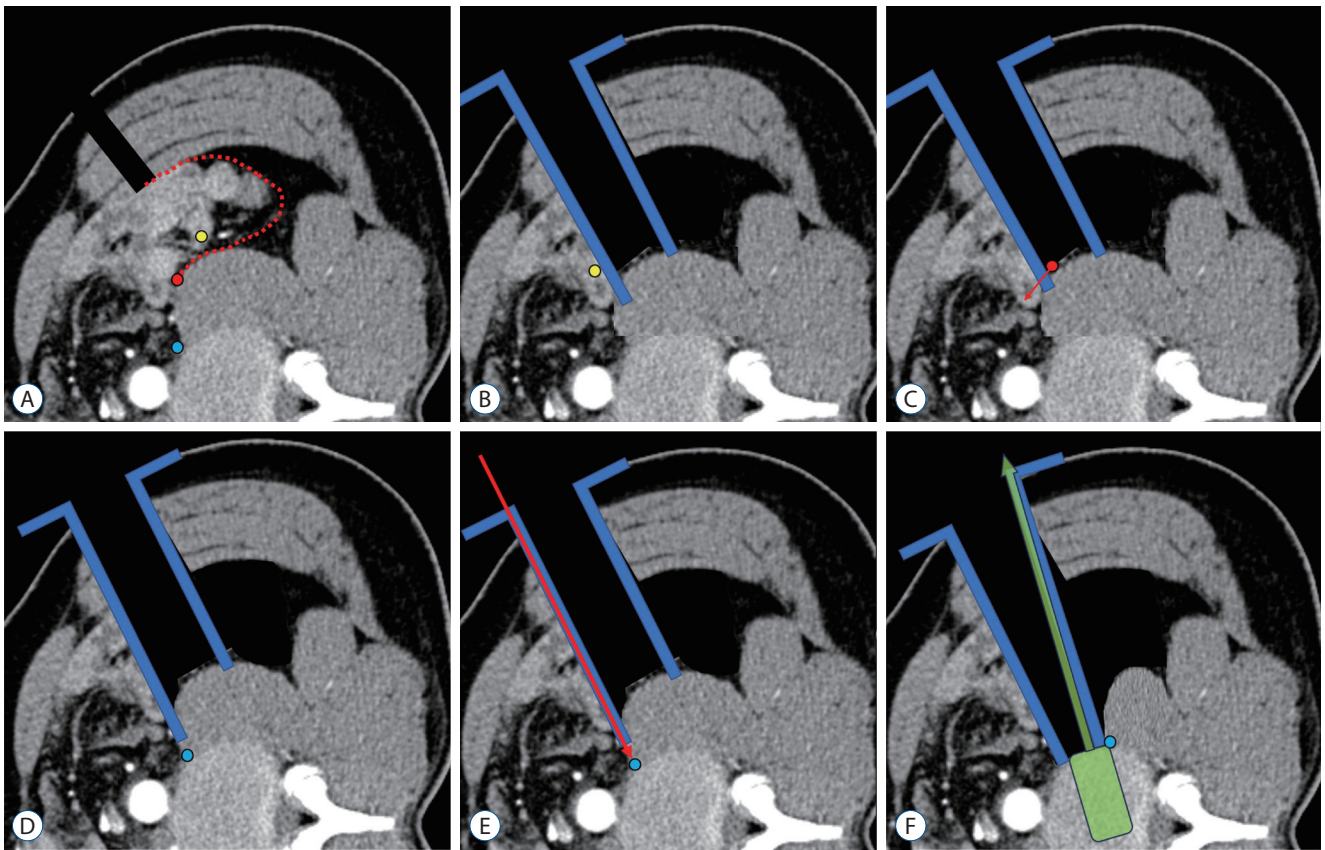


Fig. 1. Schematic location of the ureter on a dual-phase computed tomography scan. A : On the psoas (red circle), above the psoas (yellow circle), beside the psoas muscle (blue circle), retroperitoneal dissection plane (red dotted line). B : The ureter located above the psoas (yellow circle); after retroperitoneal dissection, the ureter can be easily retracted medially, retractor (blue). C : The ureter located on the psoas (red circle); after retroperitoneal dissection, the ureter can be easily visible and retracted medially (red arrow). D : The ureter is beside the psoas (blue circle); it is not identified even after conventional retroperitoneal dissection. E : The ureter can be injured by blindly fixing the retractor pinning (red arrow), or (F) blindly retracting the ureter laterally and injuring it during pull-out trials (green).

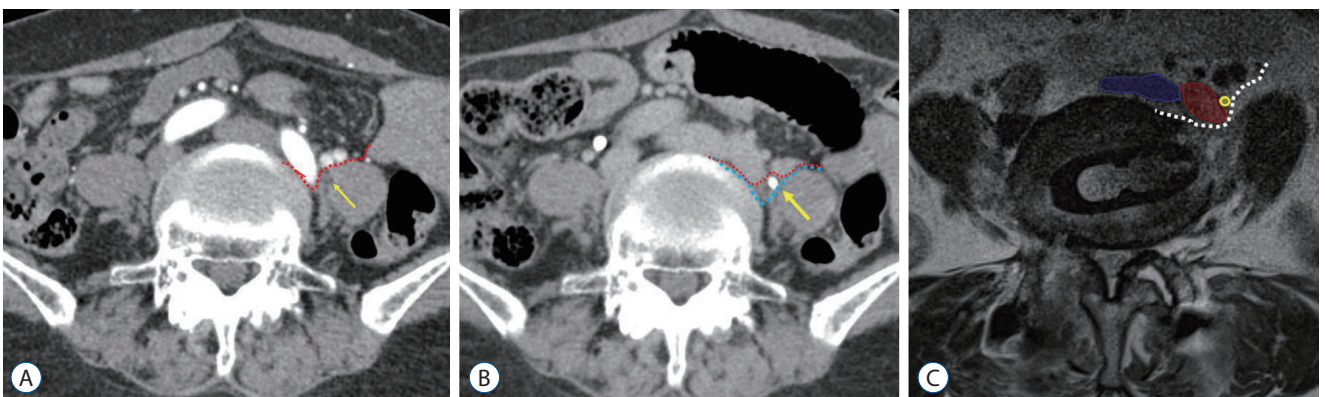


Fig. 2. Ureter under the psoas muscle. A and B : Preoperative dual phase computed tomography image (A : artery phase). The ureter (yellow arrow) cannot be distinguished from the psoas muscle, the retroperitoneal dissection plane is expected as a red dotted line (B : ureter phase). The left ureter (yellow arrow) hidden under the psoas muscle is contrast enhanced. To prevent ureter damage, identifying the ureter and medial retraction is necessary as the blue dotted line, (C) postoperative 1 week magnetic resonance imaging, left iliac vein and ureter and some visceral vessel was moved medially, white dotted line indicate the real dissection plane. Blue area : inferior vena cava, red area : left iliac artery, yellow circle : ureter.

I-p. In this case, XLIF could be performed safely but we should be concerned about the possibility that the ureter could be under the psoas (a rare location). However, for OLIF procedures, we should pay special attention to ureter injury. Since the ureter is not identified during retroperitoneal dissection to the anterior border of the psoas muscle, the surgeon might assume that the ureter is retracted medially. However, the ureter is close to the operative corridor, and this location has high risk of ureter injury. We retrospectively found that two ureter injuries occurred in this area from our more than 700 OLIF cases. We recently reported these cases, but also briefly introduce them here⁸⁾.

In the first case, the ureter was kinked or penetrated by retractor pin insertion; in particular, the pinning was performed over the psoas muscle where the retroperitoneal fat had not been clearly dissected (Fig. 1E). In the second case, the ureter was retracted laterally rather than in the medial direction, and the ureter was damaged when the trials were pulled out orthogonally (Fig. 1F).

We also introduce a recent interesting case where the ureter was under the psoas muscle. In this case, both XLIF and OLIF were risky. However, since we were aware of the location of the ureter before surgery, we were able to safely perform OLIF after medial retraction of the ureter, which was hidden below the psoas muscle (Fig. 2).

We would like to convey the message that it is important to predict the position of the ureter after retroperitoneal dissection, rather than simply evaluating the position of the ureter on preoperative CT before performing LLIF. Ureters located above or on the psoas muscle are relatively safe, but the locations of II-v and I-p should be regarded as a dangerous zone. For this danger zone, we need to perform clear dissection to the anterior border of psoas muscle and check the ureter location through direct visualization.

AUTHORS' DECLARATION

Conflicts of interest

No potential conflict of interest relevant to this article was reported.

Informed consent

This type of study does not require informed consent.

Author contributions

Conceptualization : SHL, JSL, DWS; Data curation : SHL, JSL; Formal analysis : SHL, DWS; Methodology : SHL, DWS; Project administration : DWS, GSS; Visualization : SHL; Writing - original draft : SHL, JSL, DWS, GSS; Writing - review & editing : SHL, JSL, DWS, GSS

Data sharing

None

Preprint

None

ORCID

Su-Hun Lee	https://orcid.org/0000-0001-8952-5556
Dong-Wuk Son	https://orcid.org/0000-0002-9154-1923
Jun-Seok Lee	https://orcid.org/0000-0003-2488-6953
Geun-Sung Song	https://orcid.org/0000-0001-8029-9011

References

1. Abe K, Orita S, Mannoji C, Motegi H, Aramomi M, Ishikawa T, et al. : Perioperative complications in 155 patients who underwent oblique lateral interbody fusion surgery: perspectives and indications from a retrospective, multicenter survey. **Spine (Phila Pa 1976)** **42** : 55-62, 2017
2. Bjurlin MA, Rousseau LA, Vidal PP, Hollowell CM : Iatrogenic ureteral injury secondary to a thoracolumbar lateral revision instrumentation and fusion. **Spine J** **9** : e13-e15, 2009
3. Fujibayashi S, Otsuki B, Kimura H, Tanida S, Masamoto K, Matsuda S : Preoperative assessment of the ureter with dual-phase contrast-enhanced computed tomography for lateral lumbar interbody fusion procedures. **J Orthop Sci** **22** : 420-424, 2017
4. Huang C, Bian Z, Zhu L : Morphometric analysis of the ureter with respect to lateral lumbar interbody fusion using contrast-enhanced computed tomography. **J Korean Neurosurg Soc** **66** : 155-161, 2023
5. Kim H, Chang BS, Chang SY : Pearls and pitfalls of oblique lateral interbody fusion: a comprehensive narrative review. **Neurospine** **19** : 163-176, 2022
6. Kubota G, Orita S, Umimura T, Takahashi K, Ohtori S : Insidious intraoperative ureteral injury as a complication in oblique lumbar interbody fusion surgery: a case report. **BMC Res Notes** **10** : 193, 2017
7. Lee HJ, Kim JS, Ryu KS, Park CK : Ureter injury as a complication of oblique lumbar interbody fusion. **World Neurosurg** **102** : 693.e7-693.e14, 2017

8. Lee KH, Son DW, Oh BK, Lee SH, Lee JS, Kim YH, et al. : Incidental ureteral complication in single-center consecutive oblique lateral interbody fusion cases. **Turk Neurosurg**, 2023 [Epub ahead of print]
9. Lee YS, Lee DH, Cho DC, Han I, Kim CH, Kwon HD, et al. : The change of spinal canal according to oblique lumbar interbody fusion in degenerative spondylolisthesis: a prospective observational study. **Neurospine** **19** : 492-500, 2022
10. Oh BK, Son DW, Lee SH, Lee JS, Sung SK, Lee SW, et al. : Learning curve and complications experience of oblique lateral interbody fusion : a single-center 143 consecutive cases. **J Korean Neurosurg Soc** **64** : 447-459, 2021
11. Ouchida J, Kanemura T, Satake K, Nakashima H, Segi N : Anatomic evaluation of retroperitoneal organs for lateral approach surgery: a prospective imaging study using computed tomography in the lateral decubitus position. **Eur Spine J** **28** : 835-841, 2019
12. Park SJ, Hwang JM, Cho DC, Lee S, Kim CH, Han I, et al. : Indirect decompression using oblique lumbar interbody fusion revision surgery following previous posterior decompression: comparison of clinical and radiologic outcomes between direct and indirect decompression revision surgery. **Neurospine** **19** : 544-554, 2022
13. Quillo-Olvera J, Lin GX, Jo HJ, Kim JS : Complications on minimally invasive oblique lumbar interbody fusion at L2-L5 levels: a review of the literature and surgical strategies. **Ann Transl Med** **6** : 101, 2018
14. Son D, Lee S : Oblique Lumbar Interbody Fusion (OLIF) in Ahn Y, Park JK, Park CK (eds) : **Core Techniques of Minimally Invasive Spine Surgery**. Singapore : Springer, 2023, pp243-265
15. Yingsakmongkol W, Jitpakdee K, Kerr S, Limthongkul W, Kotheeranurak V, Singhatanadgige W : Successful criteria for indirect decompression with lateral lumbar interbody fusion. **Neurospine** **19** : 805-815, 2022
16. Yoon SG, Kim MS, Kwon SC, Lyo IU, Sim HB : Delayed ureter stricture and kidney atrophy after oblique lumbar interbody fusion. **World Neurosurg** **134** : 137-140, 2020