

Neurosurgical Management of Cerebrospinal Tumors in the Era of Artificial Intelligence : A Scoping Review

Kuchalambal Agadi,¹ Asimina Dominari,^{1,2} Sameer Saleem Tebha,^{1,3} Asma Mohammadi,¹ Samina Zahid¹

Division of Research and Academic Affairs,¹ Larkin Health System, South Miami, FL, USA

Aristotle University of Thessaloniki School of Medicine,² Thessaloniki, Greece

Department of Neurosurgery and Neurology,³ Jinnah Medical and Dental College, Karachi, Pakistan

Central nervous system tumors are identified as tumors of the brain and spinal cord. The associated morbidity and mortality of cerebrospinal tumors are disproportionately high compared to other malignancies. While minimally invasive techniques have initiated a revolution in neurosurgery, artificial intelligence (AI) is expediting it. Our study aims to analyze AI's role in the neurosurgical management of cerebrospinal tumors. We conducted a scoping review using the Arksey and O'Malley framework. Upon screening, data extraction and analysis were focused on exploring all potential implications of AI, classification of these implications in the management of cerebrospinal tumors. AI has enhanced the precision of diagnosis of these tumors, enables surgeons to excise the tumor margins completely, thereby reducing the risk of recurrence, and helps to make a more accurate prediction of the patient's prognosis than the conventional methods. AI also offers real-time training to neurosurgeons using virtual and 3D simulation, thereby increasing their confidence and skills during procedures. In addition, robotics is integrated into neurosurgery and identified to increase patient outcomes by making surgery less invasive. AI, including machine learning, is rigorously considered for its applications in the neurosurgical management of cerebrospinal tumors. This field requires further research focused on areas clinically essential in improving the outcome that is also economically feasible for clinical use. The authors suggest that data analysts and neurosurgeons collaborate to explore the full potential of AI.

Key Words : Artificial intelligence · Neurosurgery · Central nervous system neoplasms · Disease management.

INTRODUCTION

Artificial intelligence (AI) is defined by Zini⁶¹⁾ as "AI is a computer-based science which aims to simulate human brain faculties using a computational system." Hashimoto et al.¹⁸⁾ describes four main branches or subtypes of AI, including machine learning, artificial neural networks, natural language processing, and computer vision. Machine learning

is an application or subset of AI in which machines can learn from the data without any prominent programming¹⁸⁾. The AI can process vast amounts of medical information that can aid in diagnosing and managing neurological conditions⁶¹⁾. Albeit, AI has demonstrated numerous benefits in the neurological care of patients with cerebrospinal tumors, although certain disadvantages have been recognized. Senders et al.⁴⁸⁾ note that though AI can enhance certain aspects of clinicians' duties, it

• Received : August 23, 2021 • Revised : October 6, 2021 • Accepted : March 14, 2022

• Address for correspondence : **Asimina Dominari**

Division of Research and Academic Affairs, Larkin Health System, 7031 SW 62nd Avenue, South Miami, FL 33143, USA

Tel : +1-305-284-7500, Fax : +1-305-384-7755, E-mail : asiminadom@gmail.com, ORCID : <https://orcid.org/0000-0002-4023-9767>

This is an Open Access article distributed under the terms of the Creative Commons Attribution Non-Commercial License (<http://creativecommons.org/licenses/by-nc/4.0>) which permits unrestricted non-commercial use, distribution, and reproduction in any medium, provided the original work is properly cited.

requires a substantial amount of quality dataset to generate AI models that are viable and deployable in the neurosurgical care of patients. Racine et al.⁴⁵⁾ identify that some of the challenges pertain to the nature of the informed consent needed, transparency and ownership of patient data, privacy and discrimination. They propose that overcoming these ethical challenges will help integrate AI into patient care⁴⁵⁾. Furthermore, in a cross-sectional survey, Palmisciano et al.⁴²⁾ found that more than 75% of the participants wanted neurosurgeons to remain in charge of the provided care ultimately. Hence, Senders et al.⁴⁹⁾ mentioned that our perspective for AI in neurosurgery should be to understand how AI and man can perform together instead of AI versus man.

To better understand AI and the impact of its development in the neurological care of patients with cerebrospinal tumors, it is vital to understand the management and prognosis of cerebrospinal tumors prior to the era of AI. Cerebrospinal tumor management is a multi-modality approach, depending on tumor type, grading, location, as well as individual patient characteristics. Treatment can be either monotherapy or a combination of surgical resection, radiation therapy, chemotherapy,

newer biological agents, or even alternating electric field therapy (Table 1)³⁹⁾.

The prognosis of CNS tumors depends on the type of tumor, malignant or benign, and the patient's age^{14,39,46,55,56)}. According to the data published by the American Cancer Society, the 5-year relative survival rate can be as low as <10% in middle-aged patients with glioblastoma, a malignant type of CNS tumor. However, a favorable prognosis is seen in younger patients (20–44 years of age) and those with benign tumors such as meningiomas (84%), oligodendrogliomas (90%), and ependymomas (92%)³⁾. In the hope of improving survival, neurosurgeons are constantly incorporating updated scientific data and technological advances into their practice⁴⁵⁾. Therefore, AI is introduced due to the difficulty of treating CNS tumors.

Our study aims to analyze the role AI is currently playing in the neurosurgical management of cerebrospinal tumors. The authors also suggest ways to improve it for a broader role.

Table 1. Treatment modalities available for CNS tumors

Treatment modality	Uses	Limitation
Surgery	<ul style="list-style-type: none"> For excising the tumor, or performing tissue biopsy, debulking a large tumor, alleviating symptoms of increased intracranial pressure or seizures^{14,60,61)} In disseminated malignancies for the placing a ventricular access catheter for delivery of chemotherapy, such as the Ommaya reservoir^{14,60,61)} 	<ul style="list-style-type: none"> For tumors located deep inside the brain, (brain stem) in parts that are less accessible, requires excessive brain tissue retraction to operate on^{14,60,61)} Not advisable for patients who are poor surgical candidates^{14,60,61)}
Radiation therapy	<ul style="list-style-type: none"> Mainstay of treatment in unresectable or recurrent tumors⁴³⁾ Eliminate the residual lesion⁴³⁾ Used in palliative care⁴³⁾ 	<ul style="list-style-type: none"> Damage normal brain tissue; causing mental decline, personality changes, fatigue⁴³⁾ Increases risk of secondary brain tumors⁴³⁾
Chemotherapy	<ul style="list-style-type: none"> Medulloblastoma and lymphoma are known to respond well to chemotherapy^{18,45)} 	<ul style="list-style-type: none"> Various systemic side effects^{18,45)}
Targeted medical therapy	<ul style="list-style-type: none"> Monoclonal anti-body of vascular endothelial growth factor^{18,45)} Bevacizumab is used to treat recurrent gliomas & meningiomas^{18,45)} mTOR protein inhibitor Everolimus is used to treat subependymal giant cell astrocytoma^{18,45)} 	<ul style="list-style-type: none"> Unclear effects on overall survival
Alternating electric field therapy	<ul style="list-style-type: none"> Increases survival in recurrent glioblastomas^{52,53)} 	<ul style="list-style-type: none"> No significant adverse event
Miscellaneous (corticosteroids, anticonvulsants & hormone replacement therapy)	<ul style="list-style-type: none"> Used for its neuroprotective purpose^{18,45)} For hormone responsive cancers^{18,45)} 	<ul style="list-style-type: none"> Prolonged use might be required

CNS : central nervous system, mTOR : mammalian target of rapamycin

MATERIALS AND METHODS

This scoping review was conducted according to the Arksey and O'Malley framework⁴. Our research was guided by the question, "What are the effective ways in which AI can be used in the neurosurgical management of cerebrospinal tumors?" We searched PubMed, Ovid, Web of Science, the Cochrane Library, Cumulative Index to Nursing and Allied Health Literature, EMBASE, and Scopus from January 10 to April 10, 2021. No filters were added. Details regarding study selection are provided using the Preferred Reporting Items for Systematic Reviews and Meta-Analyses (PRISMA) 2020 flow diagram in Fig. 1.

Studies focusing on the application of AI in the neurosurgical management of cerebrospinal tumors in human subjects were selected. We included case studies, case series, cross-sectional studies, case-control studies, cohort studies, and review articles. Only articles published in English were considered.

We excluded articles published as grey literature, preprints, and those published in languages other than English. We also excluded records for which we could not gain access to the full text, letters to the editor, meeting reports, systematic reviews, cadaver and animal studies, and articles referring to the appli-

cation of AI for the neurosurgical management of conditions other than tumors.

The screening was performed in two stages. In the first stage, we screened by title and abstract, and in the second, we reviewed the full-text articles. Screening and tabulation were performed by all authors and recorded in an Excel sheet. Due to the heterogeneity of the topic and vast study types, the authors did not perform a formal quality assessment consistent with scoping review methodology.

RESULTS

The initial database search retrieved 1521 articles and, after removing the duplicates and articles not relevant to our research question, 361 unique articles were identified. After screening the articles in two stages, 110 studies were selected for further analysis. The processes and results are further elaborated in the PRISMA 2020 flow chart (Fig. 1). The application of AI in the neurosurgical management of cerebrospinal tumors, as identified in our review, are presented in tabular form (Table 2). The application of AI from the extracted articles is summarized in the subheadings below.

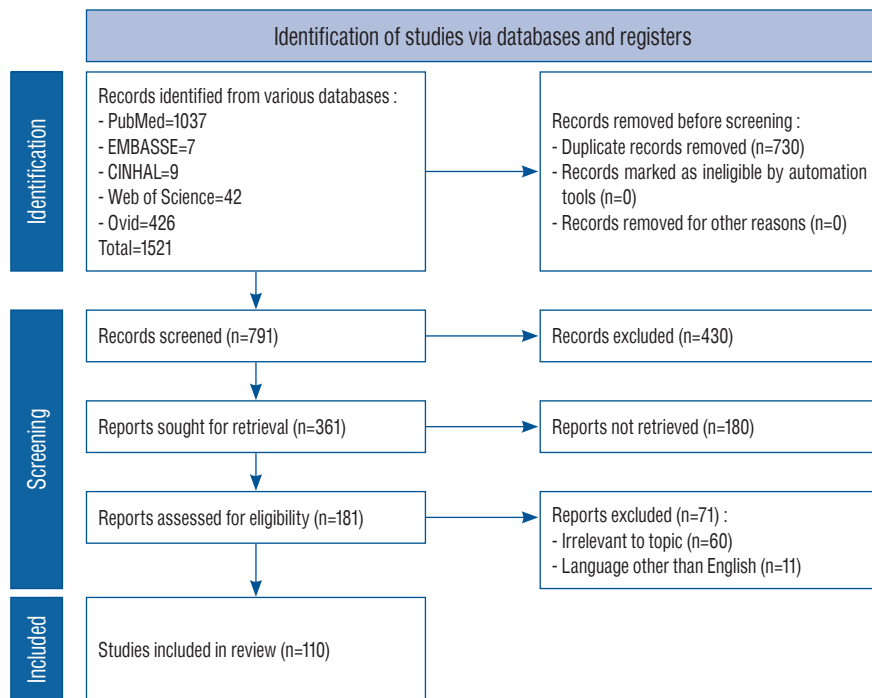


Fig. 1. Preferred Reporting Items for Systematic Reviews and Meta-Analyses 2020 flow chart. Modified from Page et al.⁴¹.

Preoperative diagnosis

The role of magnetic resonance imaging (MRI) as a diagnostic tool has been pivotal in the modern practice of neurosurgery¹³⁾. This tool allowed surgeons to evaluate structures at the base of the skull and increased the diagnostic accuracy of neuroimaging compared to conventional computed tomography (CT)³⁵⁾. The shortcomings of MRI include the difficulty in detecting small metastases and differentiating between tumors, between tumor and infectious foci, as well as between tumor

recurrence and treatment effects. Researchers have been trying to address these challenges, and the incorporation of AI might help in that direction⁴⁴⁾.

One study demonstrated the use of MRI in a subtype of brain tumor called meningeal tumors and mentioned the importance of AI in its management. Although MRI sequences can aid in identifying the different types of meningeal tumors, these characteristics can overlap with other conditions, thereby adding to the confusion. AI algorithms are effective in detect-

Table 2. Key aspects of the use of AI in the neurosurgical management of cerebrospinal tumors

Study	Main outcome(s)	Other outcome(s)
Senders et al. ⁴⁸⁾ (2018)	AI increases the efficiency and precision of perioperative decision making in neurosurgical care	Authors suggest parallel incorporation of practical and ethical issues in early stages
Senders et al. ⁴⁹⁾ (2018)	AI can potentiate clinicians' decision making. There are hurdles in creating, validating and implementing AI models into clinical practice	Change in the perception of neurosurgical care : from "human versus machine" to "human and machine working together"
Fabelo et al. ¹⁶⁾ (2018)	<i>In vivo</i> use of the hierarchical K-means algorithm for detecting glioblastoma tumor margins is promising	Takes a minute to provide the results (vs. 30 minutes by traditional histopathology)
Winkler-Schwartz et al. ⁵⁸⁾ (2019)	AI can evaluate surgical expertise with greater precision	–
Karhade et al. ²⁴⁾ (2020)	Potential utility identified by external validation of SORG ML algorithms for 90 days & 1-year survival prediction in case of metastatic spinal disease	Further prospective studies on a larger patient sample/international, multi-institutional trials needed
Jakola et al. ²²⁾ (2020)	Radiomics with the use of AI has the potential to improve predictions and prognostications in patients with glioma	–
Siyar et al. ⁵³⁾ (2020)	Virtual reality tumor resection can be incorporated into neurosurgical training. By tremor assessment, the psychomotor skill set of surgeons can be developed	–
Akbari et al. ²⁾ (2020)	Use of AI to differentiate true progression of glioblastoma from after-effects of treatment (pseudo progression)	The quantitative mpMRI analysis is freely available via Cancer Imaging Phenomic Toolkit
Van Niftrik et al. ⁵⁷⁾ (2019)	Using AI to preoperatively predict the EPC in patients undergoing tumor resection	–
Akbari et al. ²⁾ (2020)	Estimation of the extent of infiltration & the possible location of future tumor recurrence ³⁷⁾	This might increase the chances of success of the targeted treatment ³⁷⁾
Abi-Aad et al. ¹⁾ (2018)	AI may help the surgeon visualize brain deformation & help them to safely, accurately resect the tumorous tissue	–
Hollon et al. ²⁰⁾ (2020)	AI can help in streamlining intraoperative diagnosis	–
Marcus et al. ³⁴⁾ (2020)	Artificial neural network allows for improved prediction of surgical resectability in patients with GBM	–
Slosarek et al. ⁵⁴⁾ (2018)	AI can significantly increase radiotherapy coverage of tumor volume in case of multiple cerebral metastases, sparing the healthy brain tissue	–
Kamen et al. ²³⁾ (2016)	AI would be useful in providing intraoperative pathology, grading, tumor margins, and in guiding resection	–
Li et al. ³²⁾ (2017)	AI helps provide a more accurate diagnosis, and staging of low grade glioma	–

AI : artificial intelligence, ML : machine learning, mpMRI : multiparametric magnetic resonance imaging, EPC : early postoperative complications, GBM : glioblastoma multiforme

ing these minute differences for accurate diagnosis^{28,60}. In a study by Krivoschapkin et al.²⁸, MRI histogram peaks were used to formulate the AI algorithm to study the tumor volumes. By Tukey test and the Games-Howell test, the authors identified the mean deviation in agreement index between specialists (neurosurgeons and radiologists) was 0.98 (standard error of mean [SEM], 0.007). They then concluded that the advanced algorithm had proved high specificity, sensitivity, and inter-operator repeatability. In another study, the investigators utilized texture analysis algorithms and AI methods to differentiate between benign and malignant tumors, necrosis as a treatment effect, and disease progression, while some have also developed algorithms for calculating the number of metastatic lesions⁴¹. Researchers have utilized the radiologic dataset to distinguish between skull base chordomas versus chondrosarcomas and predict the molecular subgroups of medulloblastoma in a non-invasive manner^{6,11,31,59}. Hu et al.²¹ utilized AI techniques to distinguish between high-grade and low-grade tumors. The vastness of possibilities in surgical care with the use of AI is additionally witnessed in the study findings of Ker et al.²⁶. They utilized AI to classify glioma pathology specimens and extrapolated this knowledge to breast cancer specimens. Last but not least, Arle et al.⁵ found that 95% of posterior fossa tumors in the pediatric population can be accurately diagnosed with the use of AI, whereas only 72% can be predicted accurately by neuroradiologists.

In their study, Senders et al.⁴⁸ concluded that it is essential to validate AI algorithms before implementing them clinically thoroughly. They emphasize the importance of incorporating the practical and ethical aspects while developing these algorithms to “bridge the gap between research and clinical care”⁴⁹.

Surgical planning

Gross total resection of the tumor is still considered an essential component of managing cerebrospinal tumors. The traditional means to prepare for surgery is limited since it relies heavily on the surgeon’s spatial imagination, practical clinical experience, and understanding of the patient’s condition⁵¹. For tumors located at the base of the skull or close to the grey-white matter junction, a precise understanding of the anatomy is a prerequisite to perform surgery safely and successfully. Shen et al.⁵¹ propose using a 3D printed model of the skull to understand better the anatomy of the skull base in preparation for endoscopic endonasal transsphenoidal pituitary sur-

gery. Different researchers have utilized AI to better delineate the individual patient’s anatomy for preoperatively preparing the surgeon as to what to expect during surgical navigation. They have found it to be especially useful in skull base surgery, transsphenoidal pituitary surgery, or malignant tumor resection^{1,41,57}.

Even small angles of a shift in the tissue during surgery can lead to disproportionately adverse outcomes in neurosurgery. Positioning, fixing the head, and identifying landmarks are essential for neuronavigation. Intraoperative brain shifts pose a significant challenge on surgeons while resecting tumors in delicate areas like the base of the skull or surgery of posterior fossa tumors. Frisken et al.¹⁷ proposed the use of a complex finite element method, a method that takes into account biophysics and geometrics to predict shifts accurately in the manual landmarks.

Carlson and Link⁹ note that the lifetime prevalence of vestibular schwannoma is one in 500 persons. They are best evaluated by a volumetric measurement and managed based on tumor size. Semi-automated segmentation of tumors, especially schwannomas, saves time and improves segmentation accuracy and effort⁹. However, some limitations were noted regarding semi-automated segmentation that included unpredictability and error.

One of the preferred treatment options for spinal tumors is resection with stabilization. This accurate assessment of bone mineral density is a necessity. Nam et al.³⁸ have applied machine learning regression algorithms to predict the T-score of vertebrae. The authors found a classifying accuracy of 92.5% in the test data set of 40 vertebrae. They conclude that this algorithm could help the surgeons to plan preoperatively³⁸.

Lee et al.³⁰ proposed a study in which generative adversarial networks (GANs) were used to compare image synthesis. GANs are an emerging AI-based technique involving a pair of networks working against each other. This study applied GANs to image synthesis, demonstrating that synthetic systems could be trained using paired data to make MRT2 images from CT scans. The synthesized MRT2 images were further analyzed quantitatively compared to the reference MRT2 images that demonstrated close approximations. This study further concluded that the purpose of using GANs to synthesize MR images from spine CT images would demonstrate better diagnostic usefulness of CT³⁰.

Virtual training and simulation

Birkmeyer et al.⁸⁾ noted in their study that for most surgeries, the patient outcome is better if a surgeon with greater cumulative experience operates on them. Dewan et al.¹²⁾ highlight that the neurosurgeon to neurosurgical cases ratio is low, especially in low, middle-income countries. Given this shortage and the adoption of “healthcare for all” as a sustainable developmental goal, they re-emphasize the importance of ensuring that residents receive sufficient, organized skill-oriented training that will enable them to perform surgery confidently even early in their career¹²⁾. AI can be used to train, hone learned surgical skills, and assess neurosurgical residents and early- mid-career surgeons. Different researchers have utilized AI in various aspects of neurosurgical training, such as to improve diagnosis and 3D simulation labs to decrease surgeons’ hand tremors^{53,58)}. During microsurgery, tremors lead to an increased angle of resection, thereby increasing complications. Decreasing tremors has been shown to reduce the complications of high-risk surgeries directly. 3D simulation labs have also been shown to increase the surgeon’s confidence in performing the surgery, which is especially important for early career surgeons, and in contexts where there is less systematic hands-on clinical experience^{10,47,53)}.

Tumor margin detection

Remnants of tumorous tissue are the leading cause of tumor recurrence. There has been a revolution in neurosurgery with the advent of microsurgery and frozen section histopathological analysis. Despite the progress, the exact intraoperative identification of tumor margins is still an immense challenge faced by surgeons. Manni et al.³³⁾ designed a system utilizing AI to identify tumor margins by hyperspectral imaging with 80% accuracy.

A study conducted by Khalsa et al.²⁷⁾ reported the use of a microscopic technique called Raman scattering, coupled with an imaging technique called Stimulated Raman Histology to create virtual Hematoxylin and Eosin slides. This AI application helped determine the grade of the tumor without processing the tissue in real-time²⁷⁾. The same study reported the intraoperative use of AI algorithms to diagnose, classify and grade pediatric brain tumors with 100% accuracy. In their study, Khalsa et al.²⁷⁾ noted that a deep convolutional neural network (CNN) was used to distinguish 13 different brain tumors using intraoperative SRH specimens. This CNN-based

approach was proven to have a diagnostic accuracy of 94.6%. One of the best results was noted with a binary classifier and support vector machine (SVM) with F1 scores 0.92–0.94. The authors note that human neuro pathologists make diagnoses considering the clinical presentation, imaging findings, and other factors; hence, they predict that automated classifiers will not replace human pathologists, but it will improve the speed and accuracy with which a preliminary diagnosis is made²⁷⁾.

Survival prediction

Knowing the prognosis for a patient at the time of diagnosis can assist the neurosurgical team in charting the management plan for the patient. In one study, the researchers used AI algorithms to filter prognostic- related genes in high-grade gliomas (HGG)⁵²⁾. They noticed that IDH1 mutation status and protein expression of WEE1 were proven to induce HGG cell migration *in vitro*. They proposed the use of WEE1 as a prognostic biomarker that had potential diagnostic value for HGG patients⁵²⁾.

Emblem et al.¹⁵⁾ used a SVM and a whole- tumor cerebral blood volume for this purpose, while Nematollahi et al.⁴⁰⁾ proposed the C5.0 decision tree model, with tumor width and Karnofsky performance status scores being the most critical parameters for prediction of survival.

Reliable methods to predict the survival rates post-surgery help understand the early postoperative complications (EPC) and the long-term prognosis in such patients. A prospective study conducted by Van Niftrik et al.⁵⁷⁾ included data of 688 patients undergoing intracranial tumor surgery at a tertiary hospital between 2015 through 2017. They were assigned a score called the Clavien-Dindo classification score, which is based on histology, anatomical localization, and surgical access. AI algorithms were then used to predict the EPC, which was found to have better predictability than the conventional methods.

Karhade et al.²⁵⁾ investigated the use of four machine learning (ML) algorithms to predict 30-day mortality in patients undergoing spinal surgery for metastatic disease. Many pre-operative factors were used to deduce the algorithms, such as albumin, white blood cell count, hematocrit, alkaline phosphatase, spinal location of the metastasis, and severity of comorbid conditions. The performance of the algorithms was assessed and is now available as an open-access web applica-

tion²⁵). In another study done by Karhade et al.²⁴, algorithms for the 90-day and 1-year mortality in patients with spinal metastasis were proposed. As the proficiency in the use of AI grows, one can expect that they will be further utilized to increase the accuracy and time efficiency of the desired results.

Robotics

While many are exploring the incorporation of robotics into neurosurgery, it is still in the very nascent stages. Kwoh et al.²⁹ first described the use of a robotic device (programmable universal machine for assembly) for CT-guided stereotactic biopsy of an intracerebral tumor. Mattei et al.³⁶ explain how neurosurgeons from a remote workstation used an MRI-compatible robotic arm to successfully perform neurosurgical procedures, such as tumor biopsies and microsurgical dissection. McGrath et al.³⁷ in their study noted that integration of robotics might aid in improving patient outcomes, mainly by making surgery less invasive.

DISCUSSION

The application of AI in the neurosurgical management of cerebrospinal tumors is a rapidly evolving field. The potential benefits of amalgamating this field AI with current practice are extensive. It ranges from the training of budding neurosurgeons to robotic surgery applications to enhance precision in the diagnosis, pathological interpretation, and postoperative survival prediction.

Summary of the content

Over the past few decades, neuroimaging has advanced by giant strides. However, the subjective nature of the interpretation has posed limitations in making accurate preoperative diagnoses and planning surgery for patients with cerebrospinal tumors. Various authors mention that by deploying computer

algorithms, the accuracy of diagnosis and inter-operator repeatability can be improved^{28,60}. While many factors make the neurosurgical procedure successful, the surgeon's planning and competency are integral. AI algorithms have proven helpful in these aspects by improving anatomical delineation and enriching simulation-based training^{5,12,36}. The CNN-based approach has proven to increase neuropathologists' speed and accuracy to make intraoperative tissue diagnoses²⁶. This helps the neurosurgeons provide optimal surgical management in total tumor excision and pediatric tumor excision. Robotics are also being explored to improve surgical outcomes, especially by making these surgeries less invasive^{24,28,34}.

Predicting postoperative survival helps to plan postoperative care for patients with cerebrospinal tumors. Using various algorithms and scores, many authors have devised means to predict early, late postoperative survival for patients with cerebrospinal tumors^{23,25,36,51,56}. Pertinent points of AI identified in our analysis have been tabulated into pre-operative, intra-operative and post-operative applications for better visualization and can be seen in Table 3.

Limitations of study design

Potential limitations of this study include the systematic hand search in the databases and the inclusion of only peer-reviewed journal publications written in English and provided either open or institutional access to the full text. Articles in other languages, preprints, unpublished data, or other grey literature were not considered. The authors also did not perform a formal quality appraisal of the selected studies due to the significant heterogeneity.

The reliability of the AI algorithms developed is directly proportional to the size of the dataset utilized to develop it. There are very stringent rules and regulations on using confidential patient data, limiting the amount of data available for the researchers, and developing AI algorithms. Furthermore, these rules are also different in various parts of the world. The

Table 3. Summary of AI indications

Preoperative	Intraoperative	Postoperative
<ul style="list-style-type: none"> • Radiological diagnosis, classification and staging of tumors^{26-28,30} • Prediction of gross tumor resection^{5,6,9,11} • Anatomical delineation^{15,17,21} • Training of residents and early career surgeons^{34,41,42,49,57,58} 	<ul style="list-style-type: none"> • Delineation of tumor margin resection¹⁰ • Histopathological diagnosis¹⁵ • Prediction of brain shifts¹² 	<ul style="list-style-type: none"> • Prediction of postoperative survival^{7,27} • Differentiation of tumor recurrence vs. treatment effects^{7,27,32,50}

research in this field also calls for plenty of monetary input and expertise¹⁹.

Developing uniform health policies worldwide will help scientists further research in this field. Promoting funding and developing data scientists with expertise in healthcare will help overcome various limitations of using AI in the neurosurgical management of cerebrospinal tumors.

CONCLUSION

AI is rapidly evolving, and its applications in cerebrospinal tumor management are rigorously studied. Validation processes and extensive quality assessment of the proposed methods may be necessary to safely and effectively incorporate AI in neurosurgical care. In that direction, an overseeing body could guide decision-making. This field certainly requires further research, primarily focused on the economic and practical feasibility and the resolution of ethical concerns. The constant collaboration of data analysts and neurosurgeons should be encouraged to explore the full potential of AI in the management of tumors and beyond.

AUTHORS' DECLARATION

Conflicts of interest

No potential conflict of interest relevant to this article was reported.

Informed consent

This type of study does not require informed consent.

Author contributions

Conceptualization : KA; Data curation : KA, AD, SST, AM, SZ; Formal analysis : KA, AD, SST, AM, SZ; Funding acquisition : KA, AD, SZ, ST; Methodology : KA, AD; Project administration : KA, AD; Visualization : KA, AD, SST; Writing - original draft : KA, AD, AM; Writing - review & editing : KA, SZ, AD

Data sharing

None

Preprint

None

ORCID

Kuchalambal Agadi <https://orcid.org/0000-0001-8025-1261>

Asimina Dominari <https://orcid.org/0000-0002-4023-9767>

Sameer Saleem Tebha <https://orcid.org/0000-0001-8480-6148>

Asma Mohammadi <https://orcid.org/0000-0001-8556-8997>

Samina Zahid <https://orcid.org/0000-0001-6136-2724>

• Acknowledgements

Previous presentation : the abstract of this manuscript was previously accepted for presentation at: 2021 AANS Annual Scientific Meeting, August 21-25, 2021, Orlando, Florida, USA. E-poster.

References

1. Abi-Aad KR, Anderies BJ, Welz ME, Bendok BR : Machine Learning as a potential solution for shift during stereotactic brain surgery. **Neurosurgery** **82** : E102-E103, 2018
2. Akbari H, Rathore S, Bakas S, Nasrallah MP, Shukla G, Mamourian E, et al. : Histopathology-validated machine learning radiographic biomarker for noninvasive discrimination between true progression and pseudo-progression in glioblastoma. **Cancer** **126** : 2625-2636, 2020
3. American Cancer Society : **Survival rates for selected adult brain and spinal cord tumors**. Available at : <https://www.cancer.org/cancer/brain-spinal-cord-tumors-adults/detection-diagnosis-staging/survival-rates.html>
4. Arksey H, O'Malley L : Scoping studies: towards a methodological framework. **Int J Soc Res Methodol** **8** : 19-32, 2005
5. Arle JE, Morriss C, Wang ZJ, Zimmerman RA, Phillips PG, Sutton LN : Prediction of posterior fossa tumor type in children by means of magnetic resonance image properties, spectroscopy, and neural networks. **J Neurosurg** **86** : 755-761, 1997
6. Banzato T, Causin F, Della Puppa A, Cester G, Mazzai L, Zotti A : Accuracy of deep learning to differentiate the histopathological grading of meningiomas on MR images: a preliminary study. **J Magn Reson Imaging** **50** : 1152-1159, 2019
7. Bernardo A : Virtual reality and simulation in neurosurgical training. **World Neurosurg** **106** : 1015-1029, 2017
8. Birkmeyer JD, Stukel TA, Siewers AE, Goodney PP, Wennberg DE, Lucas FL : Surgeon volume and operative mortality in the united states. **N Engl J Med** **349** : 2117-2127, 2003

9. Carlson ML, Link MJ : Vestibular schwannomas. **N Engl J Med** **384** : 1335-1348, 2021
10. Christopher AS, Caruso D : Promoting health as a human right in the post-ACA united states. **AMA J Ethics** **17** : 958-965, 2015
11. Dasgupta A, Gupta T, Pungavkar S, Shirsat N, Epari S, Chinnaswamy G, et al. : Nomograms based on preoperative multiparametric magnetic resonance imaging for prediction of molecular subgrouping in medulloblastoma: results from a radiogenomics study of 111 patients. **Neuro Oncol** **21** : 115-124, 2019
12. Dewan MC, Rattani A, Fiegggen G, Arraez MA, Servadei F, Boop FA, et al. : Global neurosurgery: the current capacity and deficit in the provision of essential neurosurgical care. Executive summary of the global neurosurgery initiative at the program in global surgery and social change. **J Neurosurg** **130** : 1055-1064, 2018
13. Dietrich J : **Clinical presentation, diagnosis, and initial surgical management of high-grade gliomas**. Available at : <https://www.uptodate.com/contents/clinical-presentation-diagnosis-and-initial-surgical-management-of-high-grade-gliomas>
14. Dorsey JF, Salinas RD, Dang M : Chapter 63: cancer of the central nervous system in Niederhuber JE, Armitage JO, Doroshow JH, Kastan MB, Tepper JE (eds) : **Abeloff's Clinical Oncology, ed 6**. Philadelphia : Elsevier, 2020, pp906-967
15. Emblem KE, Pinho MC, Zöllner FG, Due-Tonnessen P, Hald JK, Schad LR, et al. : A generic support vector machine model for preoperative glioma survival associations. **Radiology** **275** : 228-234, 2015
16. Fabelo H, Ortega S, Ravi D, Kiran BR, Sosa C, Bulters D, et al. : Spatio-spectral classification of hyperspectral images for brain cancer detection during surgical operations. **PLoS One** **13** : e0193721, 2018
17. Frisken S, Luo M, Machado I, Unadkat P, Juvekar P, Bunevicius A, et al. : Preliminary results comparing thin plate splines with finite element methods for modeling brain deformation during neurosurgery using intraoperative ultrasound. **Proc SPIE Int Soc Opt Eng** **10951** : 1095120, 2019
18. Hashimoto DA, Rosman G, Rus D, Meireles OR : Artificial intelligence in surgery: promises and perils. **Ann Surg** **268** : 70-76, 2018
19. He J, Baxter SL, Xu J, Xu J, Zhou X, Zhang K : The practical implementation of artificial intelligence technologies in medicine. **Nat Med** **25** : 30-36, 2019
20. Hollon TC, Pandian B, Adapa AR, Urias E, Save AV, Khalsa SSS : Near real-time intraoperative brain tumor diagnosis using stimulated Raman histology and deep neural networks. **Nat Med** **26** : 52-58, 2020
21. Hu LS, Ning S, Eschbacher JM, Gaw N, Dueck AC, Smith KA, et al. : Multi-parametric MRI and texture analysis to visualize spatial histologic heterogeneity and tumor extent in glioblastoma. **PLoS One** **10** : e0141506, 2015
22. Jakola AS, Sagberg LM, Gulati S, Solheim O : Advancements in predicting outcomes in patients with glioma: a surgical perspective. **Expert Rev Anticancer Ther** **20** : 167-177, 2020
23. Kamen A, Sun S, Wan S, Kluckner S, Chen T, Gigler AM, et al. : Automatic tissue differentiation based on confocal endomicroscopic images for intraoperative guidance in neurosurgery. **Biomed Res Int** **2016** : 6183218, 2016
24. Karhade AV, Ahmed AK, Pennington Z, Chara A, Schilling A, Thio QCBS, et al. : External validation of the SORG 90-day and 1-year machine learning algorithms for survival in spinal metastatic disease. **Spine J** **20** : 14-21, 2020
25. Karhade AV, Thio QCBS, Ogink PT, Shah AA, Bono CM, Oh KS, et al. : Development of machine learning algorithms for prediction of 30-day mortality after surgery for spinal metastasis. **Neurosurgery** **85** : E83-E91, 2019
26. Ker J, Bai Y, Lee HY, Rao J, Wang L : Automated brain histology classification using machine learning. **J Clin Neurosci** **66** : 239-245, 2019
27. Khalsa SSS, Hollon TC, Adapa A, Urias E, Srinivasan S, Jairath N, et al. : Automated histologic diagnosis of CNS tumors with machine learning. **CNS Oncol** **9** : CNS56, 2020
28. Krivoshapkin AL, Sergeev GS, Kalneus LE, Gaytan AS, Murtazin VI, Kurbatov VP, et al. : New software for preoperative diagnostics of meningeal tumor histologic types. **World Neurosurg** **90** : 123-132, 2016
29. Kwoh YS, Hou J, Jonckheere EA, Hayati S : A robot with improved absolute positioning accuracy for CT guided stereotactic brain surgery. **IEEE Trans Biomed Eng** **35** : 153-160, 1988
30. Lee JH, Han IH, Kim DH, Yu S, Lee IS, Song YS, et al. : Spine computed tomography to magnetic resonance image synthesis using generative adversarial networks : a preliminary study. **J Korean Neurosurg Soc** **63** : 386-396, 2020
31. Li L, Wang K, Ma X, Liu Z, Wang S, Du J, et al. : Radiomic analysis of multiparametric magnetic resonance imaging for differentiating skull base chordoma and chondrosarcoma. **Eur J Radiol** **118** : 81-87, 2019
32. Li Z, Wang Y, Yu J, Shi Z, Guo Y, Chen L, et al. : Low-grade glioma segmentation based on CNN with fully connected CRF. **J Healthc Eng** **2017** : 9283480, 2017
33. Manni F, Van der Sommen F, Fabelo H, Zinger S, Shan C, Edström E, et al. : Hyperspectral imaging for glioblastoma surgery: improving tumor identification using a deep spectral-spatial approach. **Sensors (Basel)** **20** : 6955, 2020
34. Marcus AP, Marcus HJ, Camp SJ, Nandi D, Kitchen N, Thorne L : Improved prediction of surgical resectability in patients with glioblastoma using an artificial neural network. **Sci Rep** **10** : 5143, 2020
35. Mathur A, Jain N, Kesavadas C, Thomas B, Kapilamoorthy TR : Imaging of skull base pathologies: role of advanced magnetic resonance imaging techniques. **Neuroradiol J** **28** : 426-437, 2015
36. Mattei TA, Rodriguez AH, Sambhara D, Mendel E : Current state-of-the-art and future perspectives of robotic technology in neurosurgery. **Neurosurg Rev** **37** : 357-366, 2014
37. McGrath H, Li P, Dorent R, Bradford R, Saeed S, Bisdas S, et al. : Manual segmentation versus semi-automated segmentation for quantifying vestibular schwannoma volume on MRI. **Int J Comput Assist Radiol Surg** **15** : 1445-1455, 2020
38. Nam KH, Seo I, Kim DH, Lee JI, Choi BK, Han IH : Machine learning model to predict osteoporotic spine with hounsfield units on lumbar computed tomography. **J Korean Neurosurg Soc** **62** : 442-449, 2019
39. National Cancer Institute : **Adult Central Nervous System Tumors**

- Treatment - Health Professional Version. National Cancer Institute.** Available at : <https://www.cancer.gov/types/brain/hp/adult-brain-treatment-pdq>
40. Nematollahi M, Jajroudi M, Arbabi F, Azarhomayoun A, Azimifar Z : The benefits of decision tree to predict survival in patients with glioblastoma multiforme with the use of clinical and imaging features. **Asian J Neurosurg** **13** : 697-702, 2018
 41. Page MJ, McKenzie JE, Bossuyt PM, Boutron I, Hoffmann TC, Mulrow CD, et al. : The PRISMA 2020 statement: an updated guideline for reporting systematic reviews. **BMJ** **372** : n71, 2021
 42. Palmisciano P, Jamjoom AAB, Taylor D, Stoyanov D, Marcus HJ : Attitudes of patients and their relatives toward artificial intelligence in neurosurgery. **World Neurosurg** **138** : e627-e633, 2020
 43. Peng L, Parekh V, Huang P, Lin DD, Sheikh K, Baker B, et al. : Distinguishing true progression from radionecrosis after stereotactic radiation therapy for brain metastases with machine learning and radiomics. **Int J Radiat Oncol Biol Phys** **102** : 1236-1243, 2018
 44. Pope WB : Brain metastases: neuroimaging. **Handb Clin Neurol** **149** : 89-112, 2018
 45. Racine E, Boehlen W, Sample M : Healthcare uses of artificial intelligence: challenges and opportunities for growth. **Healthc Manage Forum** **32** : 272-275, 2019
 46. Scaringi C, Agolli L, Minniti G : Technical advances in radiation therapy for brain tumors. **Anticancer Res** **38** : 6041-6045, 2018
 47. Schlich T : The art and science of surgery: innovation and concepts of medical practice in operative fracture care, 1960s–1970s. **Sci Technol Human Values** **32** : 65-87, 2007
 48. Senders JT, Arnaout O, Karhade AV, Dasenbrock HH, Gormley WB, Broekman ML, et al. : Natural and artificial intelligence in neurosurgery: a systematic review. **Neurosurgery** **83** : 181-192, 2018
 49. Senders JT, Zaki MM, Karhade AV, Chang B, Gormley WB, Broekman ML, et al. : An introduction and overview of machine learning in neurosurgical care. **Acta Neurochir (Wien)** **160** : 29-38, 2018
 50. Shaikhouni A, Elder JB : Computers and neurosurgery. **World Neurosurg** **78** : 392-398, 2012
 51. Shen Z, Xie Y, Shang X, Xiong G, Chen S, Yao Y, et al. : The manufacturing procedure of 3D printed models for endoscopic endonasal transphenoidal pituitary surgery. **Technol Health Care** **28** : 131-150, 2020
 52. Shu C, Wang Q, Yan X, Wang J : Whole-genome expression microarray combined with machine learning to identify prognostic biomarkers for high-grade glioma. **J Mol Neurosci** **64** : 491-500, 2018
 53. Siyar S, Azarnoush H, Rashidi S, Del Maestro RF : Tremor assessment during virtual reality brain tumor resection. **J Surg Educ** **77** : 643-651, 2020
 54. Slosarek K, Bekman B, Wendykier J, Grządziel A, Fogliata A, Cozzi L : In silico assessment of the dosimetric quality of a novel, automated radiation treatment planning strategy for linac-based radiosurgery of multiple brain metastases and a comparison with robotic methods. **Radiat Oncol** **13** : 41, 2018
 55. Stupp R, Taillibert S, Kanner A, Read W, Steinberg D, Lhermitte B, et al. : Effect of tumor-treating fields plus maintenance temozolomide vs maintenance temozolomide alone on survival in patients with glioblastoma: a randomized clinical trial. **JAMA** **318** : 2306-2316, 2017
 56. Stupp R, Wong ET, Kanner AA, Steinberg D, Engelhard H, Heidecke V, et al. : NovoTTF-100A versus physician's choice chemotherapy in recurrent glioblastoma: a randomised phase III trial of a novel treatment modality. **Eur J Cancer** **48** : 2192-2202, 2012
 57. Van Niftrik CHB, Van der Wouden F, Staartjes VE, Fierstra J, Stienen MN, Akeret K, et al. : Machine learning algorithm identifies patients at high risk for early complications after intracranial tumor surgery: registry-based cohort study. **Neurosurgery** **85** : E756-E764, 2019
 58. Winkler-Schwartz A, Yilmaz R, Mirchi N, Bissonnette V, Ledwos N, Siyar S, et al. : Machine learning identification of surgical and operative factors associated with surgical expertise in virtual reality simulation. **JAMA Netw Open** **2** : e198363, 2019
 59. Yan J, Liu L, Wang W, Zhao Y, Li KK, Li K, et al. : Radiomic features from multi-parameter MRI combined with clinical parameters predict molecular subgroups in patients with medulloblastoma. **Front Oncol** **10** : 558162, 2020
 60. Yock AD, Kim GY : Technical note: using K-means clustering to determine the number and position of isocenters in MLC-based multiple target intracranial radiosurgery. **J Appl Clin Med Phys** **18** : 351-357, 2017
 61. Zini G : Artificial intelligence in hematology. **Hematology** **10** : 393-400, 2005