

Treatment of a lip defect in a patient with chorea-acanthocytosis using a combination of surgical and adjuvant onabotulinumtoxinA therapy: a case report

Man Wong Han, Ji-Ung Park

Department of Plastic and Reconstructive Surgery, Seoul Metropolitan Government Seoul National University Boramae Medical Center, Seoul National University College of Medicine, Seoul, Korea

Chorea-acanthocytosis (ChAc) is an extremely rare neurodegenerative disorder characterized by movement disorders and acanthocytosis. Orofacial dyskinesia is a distinct symptom of this disorder that can lead to lip injuries and feeding difficulties. This paper reports the first case of a patient with ChAc presenting with a lip defect, who was managed with surgical and adjuvant onabotulinumtoxinA (BTX-A) therapy. A 43-year-old woman diagnosed with ChAc was referred to our clinic because of a 5×5 mm lip defect resulting from orofacial dyskinesia. Wedge resection of the scar tissue was carried out, followed by reconstruction by suturing. Postoperatively, BTX-A injections were administered to ameliorate dyskinesia. Thirty units of BTX-A were injected into each masseter muscle, and 40 units were injected into the orbicularis oris muscle. At 1, 2, and 4 weeks after the injections, assessments were performed using the Abnormal Involuntary Movement Scale, and the patient's impression of change was assessed using the Global Rating of Change Scale. Subsequent adjuvant BTX-A treatment yielded subjective and objective improvements in orofacial dyskinesia. In conclusion, lip reconstruction and adjuvant BTX-A injections were effective in treating lip defects associated with orofacial dyskinesia in patients with ChAc, which highlights the need for a multimodal treatment approach.

Abbreviations: AIMS, Abnormal Involuntary Movement Scale; BTX-A, onabotulinumtoxinA; ChAc, chorea-acanthocytosis

Keywords: Botulinum toxins, type A / Case reports / Dyskinesias / Lip diseases / Mouth protectors / Neuroacanthocytosis

INTRODUCTION

Chorea-acanthocytosis (ChAc) is an uncommon neurodegenerative disorder inherited in an autosomal recessive manner. It

arises from a *VPS13A* gene mutation that influences the synthesis of chorein protein and molecular trafficking to the cell membrane [1]. Approximately 200 documented cases have been reported in the literature and an estimated 1,000 individuals have been potentially affected by this disease worldwide [2]. Typically manifesting in mid-adulthood, ChAc follows a progressive course, characterized by clinical features, such as chorea, orofacial dyskinesia, cognitive impairment, epilepsy, and acanthocytosis.

ChAc is one of the neuroacanthocytosis syndromes, characterized by neurological disorders and acanthocytosis. This syndrome includes McLeod's syndrome, pantothenate kinase-associated neurodegeneration, and Huntington's disease-like 2, each of which has distinct genetic causes. Among the distinctive

Correspondence: Ji-Ung Park

Department of Plastic and Reconstructive Surgery, Seoul Metropolitan Government Seoul National University Boramae Medical Center, Seoul National University College of Medicine, 20 Boramae-ro 5-gil, Dongjak-gu, Seoul 07061, Korea

E-mail: alfbskan@gmail.com

How to cite this article:

Han MW, Park JU. Treatment of a lip defect in a patient with chorea-acanthocytosis using a combination of surgical and adjuvant onabotulinumtoxinA therapy: a case report. Arch Craniofac Surg 2024;25(5):257-261. https://doi.org/10.7181/acfs.2024.00108

Received February 23, 2024 / Revised March 13, 2024 / Accepted August 17, 2024

symptoms of neurologic disorder, one notable feature is involuntary movement in the orofacial region. Orofacial features can manifest in various forms, including dysphagia, orofacial dyskinesia, dysarthria, involuntary tongue movement, and self-mutilation. Due to the clinical similarities between ChAc and other neuroacanthocytosis syndromes, diagnosis of ChAc should be confirmed by genetic testing to identify mutations of the *VP-S13A* gene [1,2].

However, as there is currently no curative or disease-modifying treatment available for ChAc, the management of this condition remains purely symptomatic. Various approaches have been reported for the management of orofacial dyskinesia, including the use of mechanical devices, tooth extraction, medication, and onabotulinumtoxinA (BTX-A) injections [3,4]. To the best of our knowledge, there have been no reported cases of surgical lip reconstruction followed by adjuvant therapy with BTX-A injections in patients with ChAc and lip defects.

In this study, our objective was to comprehensively investigate the orofacial features linked to the rare ChAc disease and offer a detailed account of effective treatment strategies for individuals with associated lip defects.

CASE REPORT

A 43-year-old woman diagnosed with ChAc was referred to our plastic surgery clinic due to a lip defect. The patient's parents were healthy and non-consanguineous; her older sister was diagnosed with ChAc, while her younger brother remained healthy. The main complaints related to lip deficiency were cosmetic and functional problems associated with spillage of liquid (Fig. 1A). Genetic testing confirmed the presence of a *VPS13A* gene mutation, and characteristic acanthocytosis was observed in a peripheral blood smear, leading to the diagnosis of ChAc. Orofacial dyskinesia was characterized by lip-pursing, pouting, tongue protrusion, and chewing-like motions that progressively worsened over time. With each involuntary movement during which the upper teeth bit into the lower lip, the lower lip wound showed no improvement, with an epithelialized wound resulting in a 5 × 5 mm lip defect.

The patient underwent surgery for reconstruction of the lip defect. Full-thickness wedge resection was performed, including scar tissue resection, followed by closure of the lower lip defect (Fig. 1B). To enhance postoperative preventive mea-

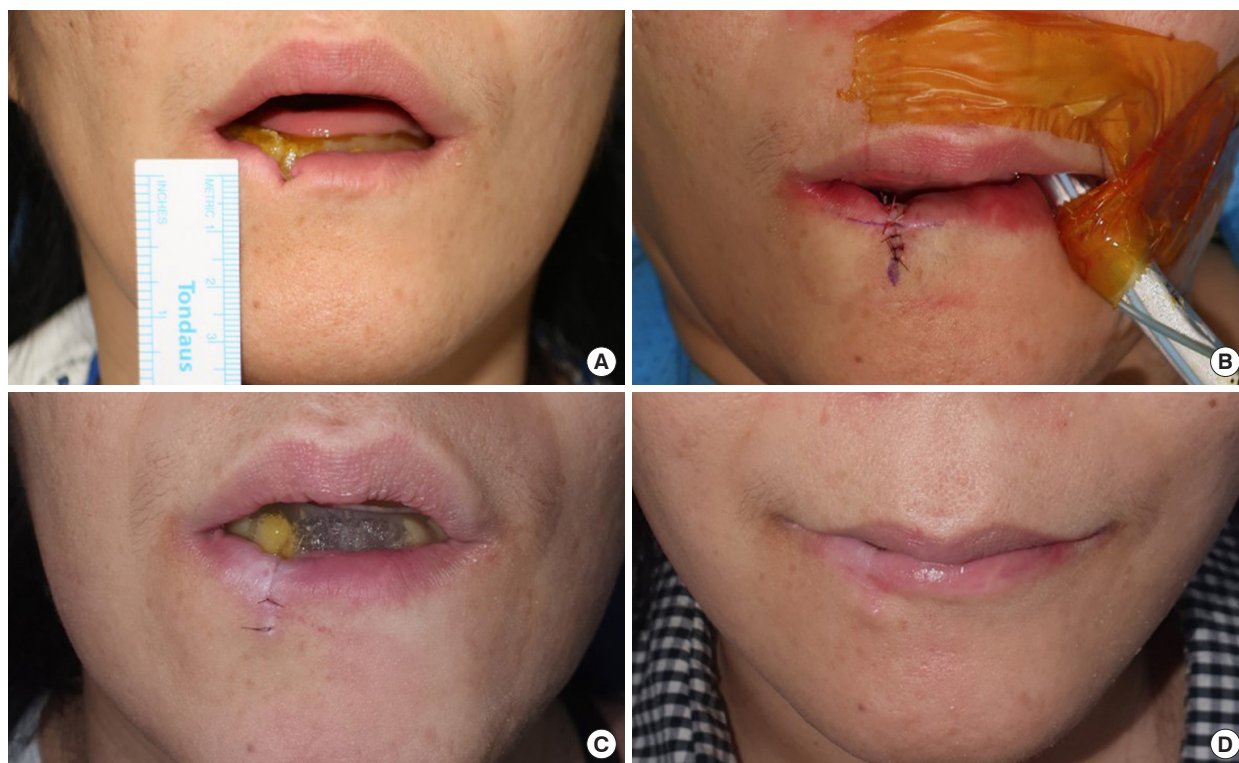


Fig. 1. A 43-year-old woman with a lower lip defect caused by orofacial dyskinesia, a characteristic feature of chorea-acanthocytosis. The changes in the appearance of the lower lip before and after surgery. (A) Preoperative photograph showing a lower lip defect approximately 5 × 5 mm in size. (B) The immediate postoperative photograph of the lower lip reconstructed using a wedge resection. (C) Five days after surgery, there is no wound dehiscence, and the surgical site appears slightly macerated. (D) Healed wound 1 month after surgery with improved appearance.

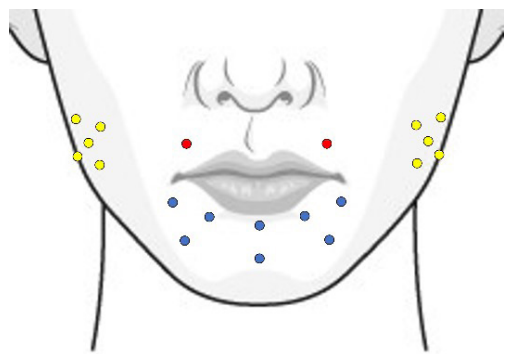


Fig. 2. OnabotulinumtoxinA injection sites. Six units at each of the five points of injection on the masseter muscle (yellow dots), four units at each of the two points on the superior orbicularis oris muscle (red dots), and four units at each of the eight points on the inferior orbicularis oris muscle (blue dots).

tures, a custom-made, thicker mouth guard was used. BTX-A was administered as adjuvant therapy to prevent lip wound recurrence post-surgery. BTX-A was reconstituted with 5 cc of 0.9% normal saline, resulting in a solution with a concentration of two units per 0.1 cc. A total of 100 units of BTX-A were injected as follows: five injection points with six units each in the masseter muscle, two injection points with four units each in the superior orbicularis oris muscle, and eight injection points with four units each in the inferior orbicularis oris muscle (Fig. 2).

The severity of orofacial dyskinesia was assessed using items 2 to 4 of the Abnormal Involuntary Movement Scale (AIMS), focusing on the lips, perioral area, jaw, and tongue. In addition, to measure subjective symptom changes, a questionnaire based on the Global Rating of Change Scale was administered. Follow-up evaluations were conducted at BTX-A pretreatment and 1, 2, and 4 weeks thereafter.

The results showed that the lip defect maintained its integrity without significant scar widening for up to 1 month postoperatively (Fig. 1C and D). In the objective assessment, a significant improvement in the involuntary movement of the perioral area and jaw was observed from the second week onward (Table 1). In the subjective symptom questionnaire, improvements in the intensity and frequency of involuntary movements, cosmetic concerns, and reduction of discomfort during meals were reported from the first week onward (Table 2). The patient did not experience any side effects, such as difficulty in swallowing, following the BTX-A injections. The symptoms improved by the fourth week of adjuvant treatment, and no additional injections were administered.

Table 1. Result of the Abnormal Involuntary Movement Scale scores following injection of botulinum toxin A

	Baseline	1 Week	2 Weeks	4 Weeks
Lips and perioral area	3	3	2	2
Jaw	3	3	1	1
Tongue	2	2	1	1
Mean	2.67	2.67	1.33	1.33

Table 2. Results of the Global Range Change Scale following onabotulinumtoxinA injection

	1 Week	2 Weeks	4 Weeks
Severity of involuntary movement	3	4	4
Frequency of involuntary movement	3	4	4
Social impact	2	3	3
Feeding	3	4	4

DISCUSSION

In this case report, we present the orofacial clinical features of a patient with ChAc, an exceedingly rare condition. We demonstrated that even in cases of lip defects with a high risk of recurrence due to orofacial dyskinesia, effective treatment without wound dehiscence can be achieved through surgical intervention and adjuvant BTX-A therapy. Objective assessments using AIMS before and after BTX-A injection, along with subjective questionnaires, showed improved orofacial dyskinesia. To the best of our knowledge, this is the first case report of surgical and adjuvant BTX-A treatment for lip lesions caused by involuntary movement in a patient with ChAc. This multidisciplinary approach is significant because it provides an effective treatment option for challenging cases.

Currently, treatment options for addressing involuntary movements in ChAc, include the use of medication, deep brain stimulation, and BTX-A injections [5,6]. When administering BTX-A, precision in targeting the muscles responsible for involuntary movements is crucial [1,7]. According to Urs et al. [1], a review of orofacial features in a total of 97 patients with ChAc reported the following percentages: dysphagia (62.7%), orofacial dyskinesia (51.4%), dysarthria (40.5%), involuntary tongue movement (27.7%), and tongue protrusion (13%) as prominent features, alongside minor features such as self-mutilation (5.9%) and bruxism (5%). Considering the diverse orofacial features, multiple facial muscles may be involved. Therefore, the orofacial features and specific discomfort experienced by patients should be accurately assessed before injection to establish an effective treatment plan.

In previous studies on the use of BTX-A injections for orofacial involuntary movements in ChAc, injections into the genio-

glossus muscle led to improvements in tongue protrusion and feeding dystonia in some cases [3]. Ortega et al. [4] administered 35 units of BTX-A into the inferior head of the lateral pterygoid muscles and 15 units into the masseter muscle in a ChAc patient with severe clenching, grinding, speech articulation, and oral ulcers due to oromandibular dystonia, resulting in an objective and subjective improvement in dystonia symptoms.

In this case, the lip defect was attributed to orofacial dyskinesia, specifically chewing-like motion and lip-smacking, wherein the upper teeth continually injured the lower lip. Therefore, injections were administered into the orbicularis oris and masseter muscles which are associated with lip-closing movements and chewing motion, respectively. Previous studies have guided the determination of BTX-A dosage and injection sites [8-10]. Studies on BTX-A injections for tardive dyskinesia have employed various approaches. One study administered 20 units at four sites: 1 cm lateral to the buccal commissure, the midpoint of the upper lip, and the mid-central area of the chin [8]. Another study targeted four sites in the orbicularis oris muscle (with two sites around the upper lip and two around the lower lip), injecting 10 units into each site. Considering that the lower orbicularis oris muscle exhibited a stronger muscle tone in the patient, more injections were administered in the lower orbicularis oris muscle while maintaining a total dosage of 40 units, consistent with findings in previous studies. Previous studies involving injections into the masseter muscle were primarily focused on patients with dystonia and typically utilized doses ranging from 10 to 50 units, with significant improvements usually observed with approximately 50 units [9]. As the patient predominantly displayed dyskinetic features with less spasticity than dystonia, a 30-unit injection was opted for in this case.

To evaluate the effectiveness of BTX-A in orofacial dyskinesia associated with ChAc patients, the approach of utilizing AIMS items of 2 to 4 was adopted, in line with previous studies [11,12]. One week after the BTX-A injection, the patients subjectively reported improvements in their symptoms. However, AIMS scores did not differ substantially. This discrepancy may be attributed to the limited sensitivity of the AIMS scale, which ranges from 0 (none) to 4 (severe) and may not adequately capture the extent of improvement. It is well documented that the maximum effect of BTX-A typically manifests within 2 to 4 weeks, which is consistent with our observations. In a scenario where BTX-A injections are considered for adjuvant purposes following lip or oral ulcer surgery, it is advisable to administer BTX-A injections approximately 1 to 2 weeks prior to surgery. This preoperative intervention can effectively mitigate the risk of wound dehiscence, which may decrease immediately after surgery.

In situations characterized by involuntary movements, particularly self-mutilation, leading to lip and oral ulceration, initial considerations may involve the use of a mouth guard. The patient in our case also used a mouth guard; however, it was not sufficiently thick to protect the wound after surgery. When considering lip surgery in patients with ChAc, ensuring an adequately thick mouth guard is crucial, highlighting the importance of a multimodal approach, including prosthetic and BTX-A injection therapy.

Potential side effects of BTX-A include temporary regional weakness, minor discomfort during chewing, asymmetric smiles, and lip numbness. In the present case, no side effects were observed; however, owing to the potential risk of dysphagia and aspiration, preemptive warnings about injection risks and close monitoring were advised.

In this case, surgical intervention and adjuvant BTX-A injections were effective in treating lip defects associated with orofacial dyskinesia in a patient with ChAc. In patients with ChAc, a multimodal approach is crucial during the perioperative period, emphasizing the need for precise identification of target muscles owing to the diverse nature of orofacial features.

NOTES

Conflict of interest

No potential conflict of interest relevant to this article was reported.

Funding

None.

Ethical approval

The study was approved by the Institutional Review Board of Seoul Metropolitan Government Seoul National University Boramae Medical Center (IRB No. 10-2023-51).

Patient consent

Written informed consent was obtained from the patient to use and publish her images.

ORCID

Man Wong Han <https://orcid.org/0009-0004-0934-048X>
Ji-Ung Park <https://orcid.org/0000-0002-6403-4918>

Author contributions

Conceptualization: Ji-Ung Park. Methodology: Man Wong Han. Writing - original draft: Man Wong Han. Writing - review & editing: Man Wong Han, Ji-Ung Park. Supervision: Ji-Ung Park.

REFERENCES

1. Urs AB, Augustine J, Khan AA. Chorea-acanthocytosis: a case report with review of oral manifestations. *Contemp Clin Dent* 2021;12:73-5.
2. Jung HH, Danek A, Walker RH. Neuroacanthocytosis syndromes. *Orphanet J Rare Dis* 2011;6:68.
3. McIntosh J. Multidisciplinary neurorehabilitation in chorea-acanthocytosis: a case study. In: Walker RH, Saiki S, Danek A, editors. *Neuroacanthocytosis syndromes II*. Springer-Verlag; 2008. p. 271-84.
4. Ortega MC, Skarmeta NP, Diaz YJ. Management of oromandibular dystonia on a chorea acanthocytosis: a brief review of the literature and a clinical case. *Cranio* 2016;34:332-7.
5. Kobal J, Dobson-Stone C, Danek A, Fidler V, Zvan B, Zaletel M. Chorea-acanthocytosis presenting as dystonia. *Acta Clin Croat* 2014;53:107-12.
6. Yoshida K. Botulinum toxin therapy for oromandibular dystonia and other movement disorders in the stomatognathic system. *Toxins (Basel)* 2022;14:282.
7. Moon B, Park KY, Mun HG, Kim YS, Kim YJ. The significance of split-face studies and electromyography in forehead rejuvenation. *Arch Craniofac Surg* 2023;24:218-22.
8. Rapaport A, Sadeh M, Stein D, Levine J, Sirota P, Mosheva T, et al. Botulinum toxin for the treatment of oro-facial-lingual-masticatory tardive dyskinesia. *Mov Disord* 2000;15:352-5.
9. Yoshida K. Therapeutic strategies for oromandibular dystonia. *Fortschr Neurol Psychiatr* 2021;89:562-72.
10. Choi JH, Choi SY, Hwang JH, Kim KS, Lee SY. Isolated unilateral temporalis muscle hypertrophy of unknown etiology: a case report and literature review. *Arch Craniofac Surg* 2023;24:278-83.
11. Slotema CW, van Harten PN, Bruggeman R, Hoek HW. Botulinum toxin in the treatment of orofacial tardive dyskinesia: a single blind study. *Prog Neuropsychopharmacol Biol Psychiatry* 2008;32:507-9.
12. Oh HY, Choi HJ, Nam DH, Kim JH, Lee YM. Botulinum toxin A treatment for cervical dystonia resulting in endoscopic thyroidectomy: a case report. *J Korean Soc Plast Reconstr Surg* 2011;38:207-11.